

Case report

Claude Bernard-Horner syndrome associated with colonic interposition grafting after esophagectomy

K.H. Katsanos, Sofia Markoula¹, D.K. Christodoulou, I. Sarmas¹, S. Konitsiotis¹, A. Kyritsis¹, E.V. Tsianos

SUMMARY

A 34 year-old male was admitted in our hospital because of double vision, ptosis of the eyelid, miosis and enophthalmos of the left eye together with impaired sweating of the upper body quarter for the last two weeks. Ten years ago the patient underwent total esophagectomy with colonic graft interposition because of esophageal rupture during large caliber bougienage for congenital esophageal stenosis. The endoscopy showed a large diverticulum below the upper esophageal sphincter and numerous ulcerations of the lower part of the colonic graft in the area of the former gastro-esophageal junction. The patient was diagnosed with post-ganglionic Claude Bernard-Horner syndrome due to stellate ganglion compression from the colonic diverticulum. The patient was discharged with recommendations for liquid diet and body positions that could facilitate left stellate ganglion decompression. In the case of persisting symptoms the patient was advised about the possibility of a new surgical intervention including diverticulectomy. To the best of our knowledge this is the first reported case of Claude Bernard-Horner syndrome as a long term complication of colonic graft diverticle after esophagectomy for congenital esophageal stenosis

Key words: Claude Bernard-Horner syndrome, colonic interposition, colon grafting, esophagectomy, neuro-ophthalmic complications, esophagus

INTRODUCTION

Claude Bernard-Horner syndrome [C. Bernard 1813-1887, J.F. Horner 1831-1886] is characterized by ptosis of the eyelid (paralysis of the smooth superior tarsal muscle), together with more or less marked miosis (paralysis of the dilator pupillae), with less impressive hyperemia of the conjunctiva (vasomotor paralysis), with enophthalmos (paralysis of the smooth orbital muscle or Muller muscle) and, often, with impaired sweating of the upper body quarter.

Claude Bernard-Horner syndrome can result from lesion of the central sympathetic homolateral pathways passing among the hypothalamus, the dorsolateral medulla oblongata and the lateral columns of the spinal cord or from lesions of the paravertebral sympathetic chain and its radicular afferents.

The common causes of the last are neoplastic (i.e thyroid carcinoma) or inflammatory involvement of the cervical lymphnodes or of the proximal part of the brachial plexus, surgical and other types of trauma to cervical structures such as jugular venous catheters, carotid artery dissection, syringomyelic or traumatic lesions of the first and second thoracic spinal segments and infarcts or other lesions of the lateral part of the medulla (Wallenberg syndrome). Congenital stenosis of the esophagus is an exceptional condition, for which three main types are described: a mucous diaphragm, to be compared with membranous atresia, fibrous stenosis and stenosis caused by bronchial heterotopy¹. The diagnosis is established in the newborn, and less frequently in children and adults, in cases of vomiting, regurgitation or dysphagia. It is based on esophago-gastro-duodenal follow through and fiberoendoscopy, which allows ruling out other causes of benign narrowing. Treatment resorts to endoscopic dilatations (bougienage) and to

Departments of Internal Medicine (Hepato-Gastroenterology Unit) and ¹Neurology, Medical School, University of Ioannina, Greece

Author for correspondence:

Dr Epameinondas V. Tsianos, Professor of Medicine, Department of Internal Medicine, University of Ioannina, Medical School, Leoforos Panepistimiou, 45 110 Ioannina, Tel:0030-26510-97501, Fax:0030-26510-97016, e-mail: etsianos@cc.uoi.gr

surgery with esophageal substitution, which remains the safest method.

CASE REPORT

A 34 year-old male was admitted to our hospital because of double vision, ptosis of the eyelid, miosis and enophthalmos of the left eye together with impaired sweating of the upper body quarter for the last two weeks (Figure 1a).

Ten years ago the patient underwent total esophagectomy with colonic graft interposition because of esophageal rupture during large caliber bougienage for congenital esophageal stenosis.

The patient fulfilled the criteria of Claude Bernard-Horner syndrome and underwent investigation with brain and neck computed tomography, which was negative. In addition, routine laboratory tests were within normal limits. As pre-ganglionic (stellate ganglion) or central nervous system damage was excluded, a post-ganglionic cause of the syndrome was speculated. Barium meal showed a slightly dilated spiral colonic graft with a left mediastinal position (Figure 1b) and neck computed tomography was suggestive of stellate ganglion compression from the colonic diverticulum (Figure 1c). Although the patient did not complain of dysphagia and long-term food impactions, an upper gastrointestinal endoscopy (using a paediatric type endoscope) was performed. The endoscopy showed a large diverticulum below the upper esophageal sphincter and numerous ulcerations of the lower part of the colonic graft in the area of the former gastro-esophageal junction. The colonic graft was spiral and slightly dilated with no evidence of stenosis or fistulae co-existence.

The patient was diagnosed with post-ganglionic Claude Bernard-Horner syndrome due to stellate ganglion compression from the colonic diverticulum. He was discharged with recommendations for soft food diet and body positions that could facilitate left stellate ganglion decompression. In case of persisting symptoms the patient was advised about the possibility of a new surgical intervention including diverticulectomy. Two years later, the patient remained in a stable condition and good nutritional status, and his ophthalmological complications were significantly improved.

DISCUSSION

Claude Bernard-Horner syndrome is a well-recognized but extremely rare complication of esophagecto-

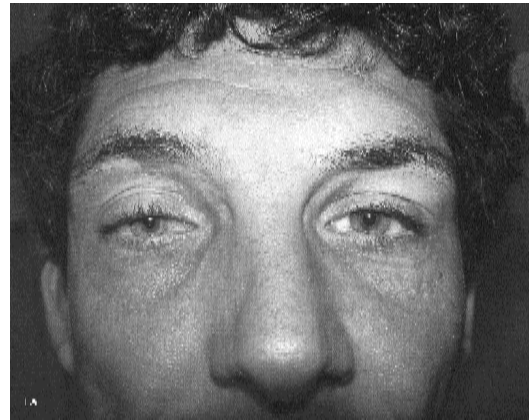

Figure 1a. Ptosis of the eyelid, miosis and enophthalmos of the left eye in a patient with Claude Bernard-Horner syndrome associated with colonic interposition grafting after esophagectomy

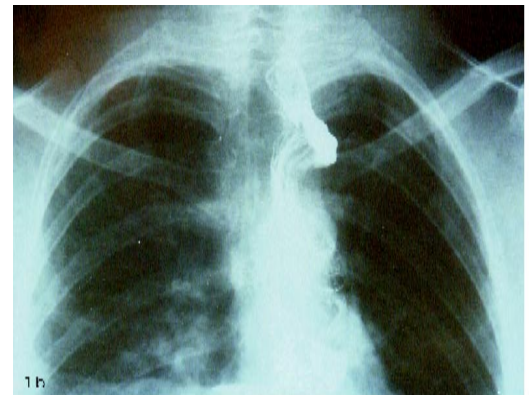


Figure 1b. Barium meal after esophagectomy for congenital esophageal stenosis showing the colonic graft with left mediastinal position.

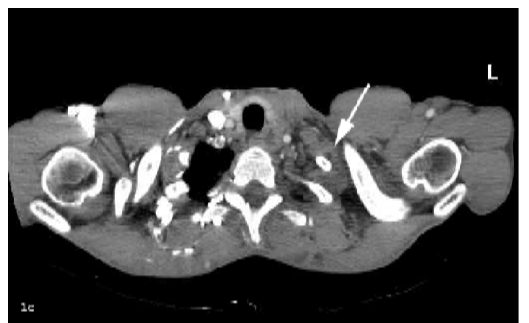


Figure 1c. Neck computed tomography showing stellate ganglion compression from the colonic diverticulum

my.¹ By contrast, colonic graft diverticula causing this syndrome as a long-term complication after esophagec-

tomy has not been previously described.

Differential diagnosis must be carefully done. With lesions on the stellate ganglia, Claude Bernard-Horner syndrome occurs in association with anhidrosis of the face. With paravertebral sympathetic chain lesions immediately caudal to the stellate ganglion, the result is isolated anhidrosis of the face without Claude Bernard-Horner syndrome, which was not the case reported here. Instillation of 1% of phenylephrine drops will cause dilatation of the miotic pupil when damage is post-ganglionic, as in this patient, but not in pre-ganglionic or central nervous system damage.

Congenital esophageal stenosis is the least common congenital tracheoesophageal anomaly. It is estimated to occur per 25,000 live births. The anomaly is thought to result from failure of normal embryonic separation of trachea and esophagus. Unlike atresia and tracheoesophageal fistulas, congenital stenosis often is not diagnosed until later in childhood and several cases have been reported in adults.² The question of whether "congenital" esophageal stenosis in adults really means "congenital" or just early onset of presently unknown causation has been recently posed.³ In addition, esophageal stenosis, mimicking that of congenital type, may result from tracheobronchial remnants remaining with the esophageal wall after repair soon after birth. In such instances, dysphagia that occurs later in life fails to respond to dilatation, but promptly improves after surgical resection of the stenotic segment. Unfortunately, the exact type of congenital stenosis could not be retrospectively identified in this patient.

With adequate insufflation during endoscopy the appearance of multiple rings with normal overlying mucosa can be seen in most cases of congenital esophageal stenosis. Segmental resection has been advocated for these patients; however properly performed bougienage has been reported to be safe in children and adults.³ However, repeated bougienage in this patient resulted in esophageal wall rupture and subsequent surgical intervention with colon grafting.

In general, the stomach remains the first choice for an esophageal substitute. During colon grafting the overall complication rate can be up to 60%, including anastomotic insufficiency, fistulae, graft necrosis, arterial hypoperfusion and peritonitis.⁴ Furthermore, secondary obstructive disorders of the esophageal substitute, including strictures^{5,6} and diverticles⁷⁻⁹ are generally surgically treated and this is what the patient was advised to do in case of persisting symptoms. Despite these limitations, colon interposition for esophageal replacement is required in some cases.

Some surgeons recommend the use of the colon graft especially in benign diseases of the esophagus since a better long-term function has been reported.¹⁰⁻¹²

Remarkably, in this patient there was evidence of colon graft ulcerations in the lower part of the colon graft. This mucosal damage is of exceptional interest in this kind of substitution surgery. In fact, thirty-six patients, subjected to colon interposition for benign esophageal disease or carcinoma of the esophagus or gastric cardia, were studied by endoscopy for signs of mucosal disease in the interposed colon. The alterations were unexpectedly few and mild considering the marked change in the location and function of the colonic segment.¹³

To the best of our knowledge this is the first reported case of Claude Bernard Horner syndrome as a long term complication of colonic graft diverticle after esophagectomy for congenital esophageal stenosis

REFERENCES

1. Vergos M, Chapuis O, Lhomme Desages B, Messina MH. Congenital stenosis of the esophagus. A rare diagnosis in children and adults. *J Chir (Paris)* 1992;129:16-19
2. Congenital esophageal stenosis. In: T. Yamada, Textbook of Gastroenterology Vol.II {2nd Ed}, J.B Lippincott Co(Editor), Philadelphia, PA, 1995 p.1163.
3. Langdon DE. 'Congenital' esophageal stenosis, corrugated ringed esophagus and eosinophilic esophagitis. *Am J Gastroenterol* 2000;95:2123-2124
4. Davis PA, Law S, Wong J. Colonic interposition after esophagectomy for cancer. *Arch Surg* 2003;138:303-308
5. Bender EM, Walbaum PR. Esophagogastrectomy for benign esophageal stricture. Fate of the esophagogastric anastomosis. *An Surg* 1987;205:385-388
6. Musher DR, Boyd A. Esophagocolonic stricture with proximal fistulae treated by balloon dilatation. *Am J Gastroenterol* 1988;83:445-447
7. Seidel K. On the ophthalmo-neurologic symptoms of esophagus diverticle. *Z Arztl Fortbild (Iena)* 1966;60:736-738
8. Furst H, Huttel TP, Lohe F, Schildberg FW. German experience with colon interposition grafting as an esophageal substitute. *Dis Esophagus* 2001;14:131-134
9. Huttel TP, Wichmann MW, Geiger TK, Schildberg FW, Furst H. Techniques and results of esophageal cancer in Germany. *Langenbeck's Arch Surg* 2002;387:125-129
10. De Meester SR. Colon interposition following esophagectomy. *Dis Esophagus* 2001;14:169-172
11. DeMeester TR, Johansson KE, Franze I, et al. Indications, surgical technique, and long-term functional results of colon interposition or bypass. *Ann Surg* 1988;208:460-474
12. Schultz-Coulon HJ. Jejunum interposition after cervical esophageal resection. *Dis Esophagus* 2001;14:13-16

13. Isolauri J, Helin H, Markkula H. Colon interposition for esophageal disease: histologic finding of colon mucosa

after a follow up of 5 months to 15 years. *Am J Gastroenterol* 1992;87:929