

Original article

# Through-the-Scope Mechanical Lithotripsy of Difficult Common Bile Duct Stones

P. Katsinelos<sup>1</sup>, I. Pilpilidis<sup>1</sup>, G. Paroutoglou<sup>1</sup>, S. Dimiropoulos<sup>1</sup>, P. Tsolkas<sup>1</sup>, E. Kamperis<sup>1</sup>, Daphni Katsiba<sup>2</sup>, Maria Kalomenopoulou<sup>2</sup>, Maria Arvaniti<sup>2</sup>, C. Kaitarzis<sup>2</sup>, A. Papagiannis<sup>1</sup>, G. Fotiadis<sup>1</sup>, I. Vasiliadis<sup>1</sup>

## SUMMARY

Over a 31 month period (October 1999 – April 2002), 342 patients were diagnosed at endoscopic retrograde cholangiography to have common bile duct stones. All patients underwent sphincterotomy and attempted extraction by Dormia basket or balloon catheter. This was successful in 305 patients (89.2%). The remaining 37 patients with difficult stones underwent through the scope mechanical lithotripsy. The mean stone size was 16.7 mm (range 1.1–2.2). Twenty-seven patients required one session of lithotripsy and eight patients two sessions. The stones were successfully crushed by the BML system and the ducts cleared in 35 patients (94.6%). In two patients, mechanical lithotripsy failed because the stones could not be engaged in the lithotripter basket. There were no serious procedure-related complications.

**Key-words:** Mechanical Lithotripsy, Difficult Common Bile Duct Stones

## INTRODUCTION

Endoscopic sphincterotomy and stone extraction have become the approach of choice, especially after cholecystectomy and in patients with high surgical risk. Several series have shown that 85-90% of common bile duct

stones can be effectively removed by endoscopic sphincterotomy combined with the Dormia basket or balloon catheter extraction<sup>1,2</sup>. The technical difficulty of stone extraction from the common bile duct increases with the size of the stones, or is difficult to remove en block through a relatively narrow distal bile duct, in patients with a small papillotomy, or in those who have undergone only balloon sphincteroplasty prior to stone extraction<sup>3,4</sup>.

Many techniques including chemical dissolution<sup>5</sup>, mechanical<sup>6</sup>, laser<sup>7</sup>, electrohydraulic<sup>8</sup>, and extracorporeal shock wave lithotripsy<sup>9</sup> have been used with success to overcome these problems.

We report our experience with a through the scope mechanical lithotripter (BML-3Q, BML-4Q) in the treatment of stones that were difficult for conventional endoscopic extraction with Dormia baskets or balloon catheters.

## PATIENTS AND METHODS

From October 1999 to April 2002, 342 patients with common bile duct (CBD) stones were referred for stone extraction to the Department of Endoscopy and Motility Unit at the Central Hospital. The majority of patients had been referred from other hospitals. In 37 patients (10.8%) difficulties were encountered using conventional extraction techniques, like Dormia basket and balloon catheter because of the large size of the stones, a comparatively narrow distal common bile duct, or inability to perform a generous sphincterotomy due to the small size of papilla of Vater. Maximal sphincterotomy length was influenced by the observed length of the intramural segment of CBD and size of papilla of Vater in each pa-

<sup>1</sup>Department of Endoscopy and Motility Unit, Central Hospital, Thessaloniki, Greece, <sup>2</sup>Department of Radiology, Central Hospital, Thessaloniki, Greece

Address for correspondence:

Panagiotis Katsinelos, 14 Marathonos str., P.O. 546 38, Thessaloniki, Greece

tient. Sphincterotomy size was confirmed by noting the diameter of a retrieval balloon which could be pulled through the sphincterotomy with minimal or moderate resistance. There were 14 men and 23 women with mean age of the gallbladder in situ.

In 21 patients (56.7%) pain in the right upper quadrant and jaundice had been the principal symptoms in diagnosing the stones, in 11 (29%) patients there had been initial signs of cholangitis and in 5 (14.3%) upper abdominal pain with increase of liver enzymes (Table 1).

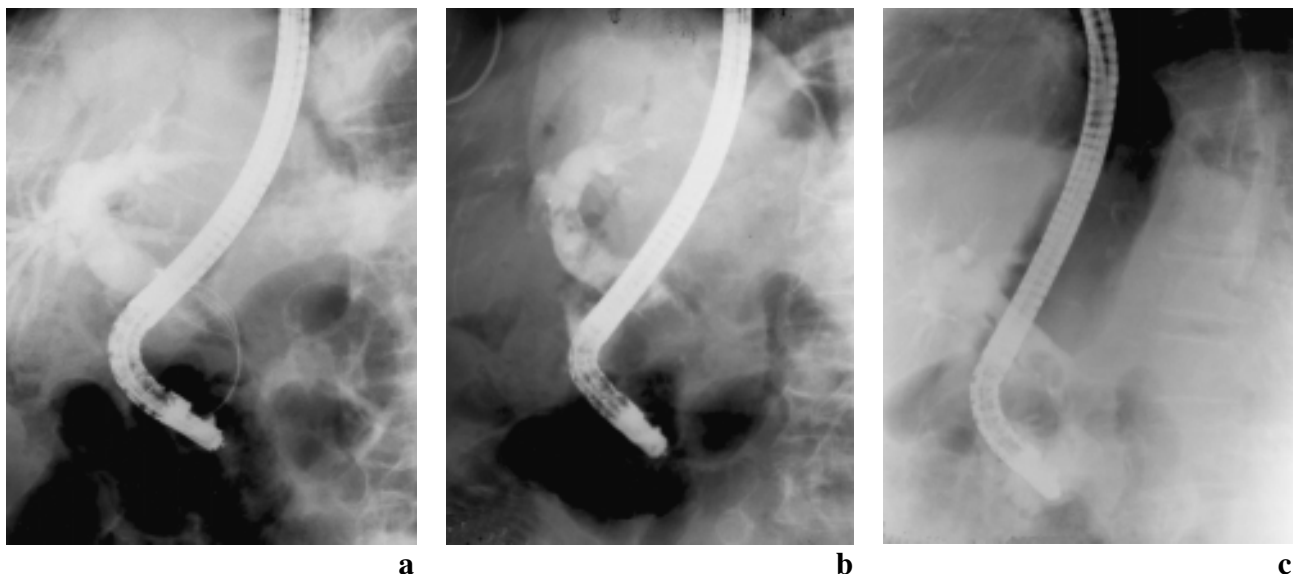
To determine the diameter and total number of stones suitable for mechanical lithotripsy, the maximum diameter of the stones was measured in the retrograde cholangiogram prior to the mechanical lithotripsy and compared with the diameter of the distal end of the endoscope. Four patients (10.9%) had gallbladder in situ and 33 patients (89.1%) previous cholecystectomy. The basket mechanical lithotriptor (Olympus BML-3Q or BML-4Q; Olympus Optical Company, Tokyo, Japan) applied through the scope in anticipation of lithotripsy (Figure 1) for large common duct stones or stones above a strictured/stenosed bile duct; and there was no need to remove the duodenoscope. There are basically two sizes: the BML-3Q has a larger basket and slightly thicker metal sheath, whereas the BML-4Q has a smaller basket and thinner sheath. The smaller system is more flexible and is useful for removal of intrahepatic stones. Initial cannulation of the common bile duct was carried out with the basket after an adequate sphincterotomy had

been performed. The metal sheath was retracted within the channel of the duodenoscope so that only the Teflon catheter and basket were used to cannulate the bile duct. Once the Teflon catheter with the closed basket had been inserted beyond the stone, the basket was opened and the Teflon catheter was pulled back, using the opened

**Table 1.** Characteristics of 37 patients with difficult common bile duct stones before treatment by endoscopic mechanical lithotripsy.

Sex		
Male	14.0	(37.8)
Female	23.0	(62.2)
Median (range) age (years)	74.8	(56–91)
Symptoms		
Upper abdominal pain and Jaundice	21.0	(56.7)
Cholangitis	11.0	(29)
Upper abdominal pain and elevated hepatic enzymes	5.0	(14.3)
Gallbladder in situ	4.0	(10.9%)
Periampullary diverticula	8.0	(21.6%)
No of stones		
Solitary	17.0	(45.9)
Two	10.0	(27)
Multiple	10.0	(27)
Mean (range) diameter of stones (mm)	16.7	(11–22)

Values in parentheses are percentages



**Figure 1.** (a) ERC showing multiple large stones in a dilated common bile duct. (b) A large common bile duct stone engaged in the lithotripsy basket. (c) Extraction of stone's fragments by a balloon catheter.

basket to engage the stone. Opening and closing of the basket, as well as tension on the wire were controlled by the gastrointestinal assistant.

Trapping of the stone may be difficult as the large stone may not leave sufficient space within the bile duct for basket manipulation. Shaking the basket often does not work. If necessary, the metal sheath was railroaded up the Teflon catheter to provide stiffness for manipulation of the basket. Gentle twisting of the scope transmitted a force to the basket to facilitate movement of the basket wires around the stone for stone engagement. It was helpful sometimes to advance the scope further into the second part of the duodenum to straighten the axis of the basket and the bile duct to facilitate stone engagement. Once the stone was properly trapped within the basket, the metal sheath was advanced up the level of the stone by adjusting the controls on the shaft of the lithotripsy basket.

Tension was then applied to the wires by turning the control knob to crush the stone. When lithotripsy was performed on a hard stone, the basket wires were often deformed after stone fragmentation. The basket was removed after lithotripsy, and the scope was opened to clean the wires as well as to reshape them to reform the basket before further stone engagement. Since the stone fragments may still be relatively large, repeated stone crushing using the same basket was necessary to facilitate stone extraction and duct clearance.

Written informed consent was obtained, and all patients received a single intravenous dose of piperacillin (2g) 1h before mechanical lithotripsy.

## RESULTS

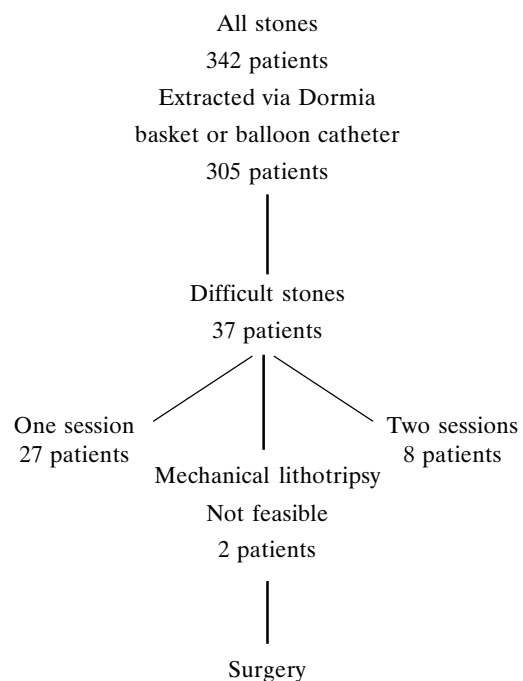
Standard endoscopic measures like Dormia baskets and balloon catheters failed to clear all stones in 10.8% of all patients who underwent endoscopic sphincterotomy for choledocholithiasis.

On retrograde cholangiography a solitary stone was present in 17 patients (45.9%), 10 patients (27%) had two stones and 10 patients (27%) had multiple stones. The mean stone size was 16.7mm; the largest stone had a diameter =15mm in 32.4 per cent of patients, 15–20mm in 48 percent, and 20–25mm in 19.6 per cent. All but one patient had radiolucent stones. One patient had stones with dense central calcification. Thirty-three patients had undergone cholecystectomy and four patients had gallbladder in situ with gallstones as assessed by ultrasonography of the gallbladder and ERCP.

In total, 43 mechanical lithotripsy sessions were carried out in 35 patients (mean 1.2 per cent, range 1–2). Complete clearance of the CBD was obtained in 35 patient (94 per cent) (Figure 2). Of these, 27 patients were cleared successfully during the initial attempt, whereas 8 patients required two treatments. These patients received a temporary biliary stent between first and second procedure.

In one patient, the CBD was completely filled with stones, preventing the opening of the basket and in a second patient the stone could not be captured because it was impacted at the bifurcation and 2.2 cm in diameter. No mechanical failures of the lithotriptor or basket wire breakages were encountered. Relevant complications occurred in four of the 37 patients (10.8%). One case of cholangitis and three cases of pancreatitis occurred as the only major complications after sphincterotomy and mechanical lithotripsy. All four patients could be treated conservatively with no consecutive symptoms and none died. No complications unique to the use of BML–3Q or BML–4Q lithotriptor occurred.

The median duration of follow-up (range) was 14.3 months (1–31). During this period five patients died of non-biliary causes and six other were lost to follow-up after mechanical lithotripsy.



**Figure 2.** Results of through the scope mechanical lithotripsy in 37 patients with difficult common bile duct stones.

## DISCUSSION

Since the introduction of endoscopic sphincterotomy, surgical exploration of the common bile duct has ceased to be the preferred treatment for stones in the common, bile duct<sup>1</sup>. Particularly in elderly or high risk patients, morbidity and mortality after cholecystectomy increase considerably if the common bile duct is explored at the same time, so endoscopic removal of stones from the bile duct is attempted as a primary procedure in these patients<sup>2</sup>.

After endoscopic papillotomy, common bile duct stones <1cm in size can easily be extracted using balloon catheters or Dormia baskets<sup>2</sup>. Larger stones must be fragmented before they can be removed. A number of techniques are available for breaking up such stones, such as intracorporeal electrohydraulic, extracorporeal shock wave, or laser induced lithotripsy<sup>7-9</sup>.

Since the description by Demling et al<sup>10</sup> in 1982, endoscopic mechanical lithotripsy has been accepted as the most reliable method of crushing difficult CBD stones, significantly improving the success rate of endoscopic extraction<sup>11-14</sup>.

Stone hardness does not seem to represent a limiting factor for mechanical lithotripsy, because large CBD stones are commonly of the brown variety<sup>15</sup>. They are often soft and muddy and can be broken with a lithotripsy basket. In the present study all grasped stones could also be fragment successfully. No cases were encountered in which the basket broke before the stone. The newer lithotripsy baskets Olympus BML-3Q or BML-4Q have an additional Teflon sheath over the basket<sup>16</sup>. The basket-Teflon sheath assembly is introduced into the common bile duct and the stone engaged before the strong spiral metal sheath is advanced over the sheath and basket. This design makes entry into the bile duct easier and may reduce some of the potential hazards such as bile duct perforation.

We have found through the scope mechanical lithotripsy to be very useful in dealing with difficult common bile duct stones. Before the use of the mechanical lithotripsy in our practice, the success rate for removal of common bile duct stones >1cm was only 89 percent. After the introduction of mechanical lithotripsy the CBD clearing increased to 94.6%. In eight patients with multiple stones, two sessions of mechanical lithotripsy and stone extraction were necessary. If lithotripsy fails, it is wiser for patients to be treated by biliary stenting before a second session of mechanical lithotripsy is attempted. In two patients the failure of this technique was the inability to

grasp the stones because the CBD was completely occupied by stones, preventing the progression or the complete unfolding of basket. Other technical problems, such as rupture of the basket or impaction of the lithotripter, may occasionally account for failure of mechanical lithotripsy.

However apart from stone size, no other factors, such as age, sex, clinical picture, paravaterian diverticula, or number of stones had any role in determining the outcome of mechanical lithotripsy. Mechanical lithotripsy through the scope is easy to use, safe and economical. It can be used immediately after identification of difficult CBD stones without the need to prepare sophisticated equipment.

Despite mechanical lithotripsy through the scope of difficult common bile duct stones, performed with success rate of 94.6%, the limited number of patients, in our study, requires further confirmation to define its significance in the treatment of difficult CBD stones.

In conclusion, we have found that use of a through the scope mechanical lithotripter with improved opening force, large-size basket, and increased crushing strength was successful in removing more than 94.6% of CBD stones refractory to conventional approaches. This improved clearance was not accompanied by an increase in morbidity or mortality. Therapeutic biliary endoscopists competent to use a therapeutic duodenoscope successfully use this lithotripter in a variety of hospital settings. When combined with other complementary procedures, it is possible that CBD could be successfully cleared in virtually all patients, without surgery.

## REFERENCES

1. Venu RP, Geenen JE. Overview of endoscopic sphincterotomy for common bile duct stones. *Gastrointest Endosc Clin North Am* 1991; 1:3-26.
2. Sherman S, Hawes RH, Lehman GA. Management of bile duct stones. *Semin Liver Dis* 1990; 10:205-221.
3. Sauerbruch T, Feussner H, Frimberger E. Treatment of common bile duct stones. A consensus report. *Hepatogastroenterology* 1994; 41:513-15.
4. Neoptolemos JP, Hofman AF, Mooss AR. Chemical treatment of stones in the biliary tree. *Br J Surg* 1986; 73:515-524.
5. Lee JG, Leung JW. Endoscopic management of common bile duct stones. *Gastrointest Endosc Clin N Am* 1996; 6:43-55.
6. Hintze RE, Adler A, Veltzke W. Outcome of mechanical lithotripsy of bile duct stones in an unselected series of 704 patients. *Hepatogastroenterology* 1996; 43:471-476.
7. Hochberger J, Banger J, May A, Mühlendorfer S, Maiss J,

- Hahn EG et al. Laser lithotripsy of difficult bile duct stones: results in 60 patients using a rhodamine 6G dye laser with optical stone tissue detection system. *Gut* 1998; 43:823–829.
8. Bruckner M, Grimm H, Soehendra N. Electrohydraulic lithotripsy of complicated choledocholithiasis. *Endoscopy* 1990; 22:234–235.
  9. Van der Hul R, Plaisier PW, Van Blankenstein M, Terpstra OT, Den Toom R, Bruining HA. Extracorporeal shock wave lithotripsy of common bile duct stones in patients with increased operative risk. *Eur J Surg* 1994; 160:31–35.
  10. Demling L, Seuberth K, Riemann JF. A mechanical lithotripter. *Endoscopy* 1982; 14:100–101.
  11. Schneider MU, Matek W, Bauer R, Domschke W. Mechanical lithotripsy of bile duct stones in 209 patients—effect of technical advances. *Endoscopy* 1988; 20:248–253.
  12. Siegel JH, Ben-Zvi JS, Pullano WE. Mechanical lithotripsy of common duct stones. *Gastrointest Endosc* 1990; 36:351–356.
  13. Chung SC, Leung JW, Leong HT, Li AK. Mechanical lithotripsy of large common bile duct stones using a basket. *Br J Surg* 1991; 78:1448–1450.
  14. Cipolletta L, Costomagna G, Bianco MA, Rotondano G, Piscopo R, Mutignan M, et al. Endoscopic mechanical lithotripsy of difficult common bile duct stones. *Br J Surg* 1997; 84:1407–1409.
  15. Katon RM. The giant common duct stones: still a hard nut to crack. *Gastrointest Endosc* 1988; 34:281–282.
  16. Leung JW, Neuhaus H, Chopita N. Mechanical lithotripsy in the common bile duct. *Endoscopy* 2001; 33:800–804.