

Chronic abdominal pain secondary to mesh erosion into cecum following incisional hernia repair: a case report and literature review

Divyangkumar Gandhi, Szember Marcin, Zhang Xin, Bale Asha, Dharmesh Kaswala, Brelvi Zamir

Gastroenterology Department, University of Medicine and Dentistry of New Jersey, Newark, NJ, USA

Abstract

Incisional hernias following abdominal operations are a common complication. Mesh is frequently employed to repair these hernias. Given the popularity of minimally invasive surgery utilizing polypropylene mesh for incisional hernia repair, related complications such as postoperative hematoma and seroma, foreign body reaction, organ injury, infection, mesh rejection, and fistula are being noted. Mesh migration is an infrequent occurrence, and is rarely reported in the literature. Those that are usually involve the urinary bladder. In particular, review of literature shows no reports of cases of mesh migration into the cecum several years after an open type incisional hernia repair. We present a case of delayed transmural mesh migration from the abdominal wall into the cecum presenting as chronic abdominal pain.

Keywords *Hernioplasty complication, mesh migration, cecum erosion, chronic abdominal pain*

Ann Gastroenterol 2011; 24 (4): 321-324

Introduction

Incisional hernia is the most common complication of abdominal surgery, with an incidence up to 10-15% and recurrence rates of 20-45% [1]. These hernias are often repaired with synthetic mesh to reinforce the repair or to reduce tension on weakened or missing abdominal wall fascia. This case presents one unusual complication of using mesh migration. In this case, the source of a patient's abdominal pain was found to be the erosion of the polypropylene mesh into the cecum.

Case report

The patient is a 56-year-old female with a past medical history of hypertension, morbid obesity, and uterine fibroids. She had a history of abdominal surgery with two cesarean sections, total abdominal hysterectomy, and bilateral salpingo-

oophorectomy. Five months after her last surgery in 1996, the patient was re-admitted with a large incisional hernia. She had open hernia repair with inlay polypropylene mesh under general anesthesia. Her post-operative course was uncomplicated. In general, polypropylene is cheap, available readily and is usually first choice for most hernias. It causes intense scarring, which is what is desired for repair of hernias.

Approximately 14 years (June 2010) after hernia repair, the patient presented to the Emergency Department complaining of intermittent abdominal pain rated 6/10 starting at right lower quadrant and migrating upwards and diffusely over the entire abdomen, associated with 2-3 episodes of nausea/week. She had felt this pain on and off for the past 2 years but came to the Emergency Department because she felt it was worsening. She denied any other complaints. She was passing gas and having bowel movements. All lab work was normal. Computed tomography (CT) scan of abdomen and pelvis was unremarkable. Physical exam showed moderate tenderness at right lower quadrant but was otherwise benign. Prior screening colonoscopy showed diverticulosis but was otherwise unremarkable. Repeat colonoscopy was performed on this admission which showed mesh in the cecum. In light of the patient's past history of incisional hernia repair with polypropylene mesh, this finding was consistent with partial migration of the previous surgical mesh into the cecum and mesh was intact. The mesh appeared to have eroded into the lumen, but there was no enterocutaneous fistula or any other enteric fistula. This would have been evident by clini-

Gastroenterology Department, University of Medicine and Dentistry of New Jersey, Newark, NJ, USA

Conflict of Interest: None

Correspondence to: Divyangkumar Gandhi,
80-15 41st Avenue, Apt # 428, New York City, NY 11373, USA,
e-mail: gandhidivyang@gmail.com

Received 18 July 2011; accepted 15 September 2011

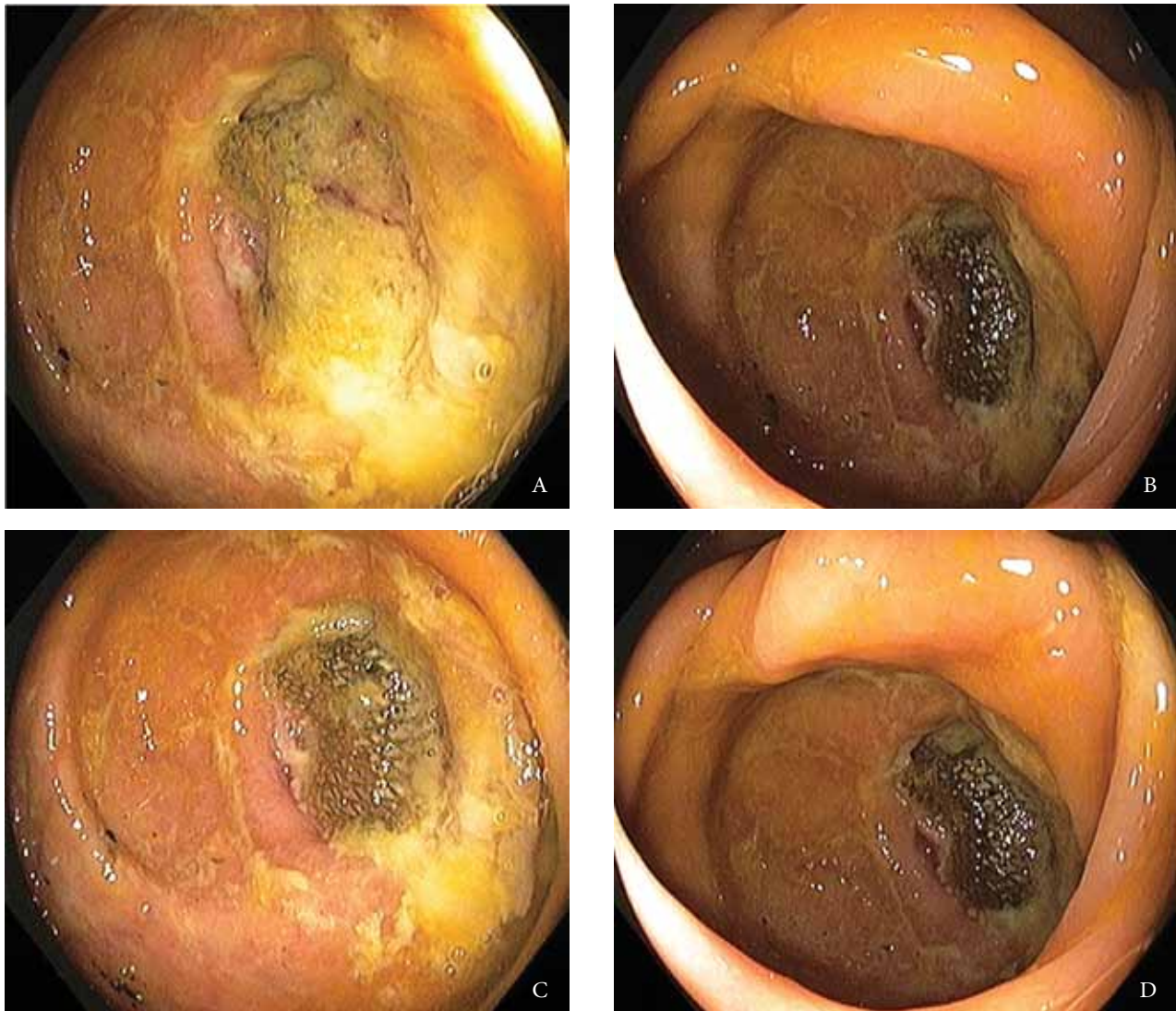


Figure 1 Endoscopic view of mesh-like material protruding through cecal wall (A-D)

cal exam and CT scan. The patient had no external leakage of stool or gas to suggest an enterocutaneous fistula, and she did not have peritoneal signs to suggest an enteric leak into the abdomen (Fig. 1).

Mesh migration often results in significant bleeding or a fistula and requires operation. However, based on the patient's minimal symptoms, morbid obesity, and probability of significant surgical morbidity (postoperative wound infection, recurrent hernia, fistula, etc.), we elected to observe. The patient was discharged with instructions to return in case of significant bleeding or increased, disabling pain. Surgery would be a better choice but the operation would be complicated; she was morbidly obese and had had multiple hernia repairs in the past. Her mesh migration was in the right lower quadrant, a difficult area to repair hernias because mesh fixation around the iliac bone is difficult. After initial presentation, she was advised to be followed

up as she was minimally symptomatic from it and had no bleeding. The operation would have involved removing the mesh, removing the cecum, re-anastomosing the bowel and then repairing the hernia with a biologic mesh, so that the mesh would not get infected. A two-stage operation might have to be done since bowel resection would have contaminated the field.

Discussion

The use of metallic mesh to reinforce the approximated tissues of a hernia repair or to actually replace the defect developed wide spread use by 1946. An increase in wound complications such as serum accumulations, wound infections, and persistent draining sinuses resulted from the use

of tantalum or stainless steel mesh. Consequently, the use of tantalum or stainless steel mesh, whole skin, and cutis were completely abandoned by 1970 [1].

Mesh repairs minimize the amount of tension that must be put on the abdominal wall in order to cover the hernia, and are generally considered preferable for incisional hernias. In a long-term retrospective study from Europe, the incidence of recurrence of incisional hernias after simple sutured repair was over 60%; the use of mesh decreased the recurrence rate to approximately 30%. Mesh repair is particularly important for incisional hernias with a diameter greater than 4 cm as the risk of recurrence is higher as the width increases. Complications related to the use of artificial materials in hernia repair include postoperative hematoma and seroma, foreign body reaction, organ injury, infection, mesh rejection, and fistula. Mesh migration following hernia repair is an uncommon complication. Erosion into a viscous can be associated with migration or can occur with the mesh in the intended position.

When erosion occurs, infection, abscess, fistula, or obstructions are the most common sequelae. Migration to a completely intraluminal position is exceedingly rare. Mesh migration occurs generally via two mechanisms. Primary mechanical migration occurs when an inadequately secured mesh traverses along adjoining paths of least resistance or when a relatively secure mesh is displaced by external forces [1]. Secondary migration, on the other hand, occurs through trans-anatomical planes and is the result of erosions triggered by foreign body reaction [2]. This mechanism has been supported by the presence of inflammatory granulation tissue at the site of migration [3]. The latter process is gradual and may take several years.

Mesh migration is rare and unpredictable. Clinical presentations are variable and related to the organ involved. Migration of knitted propylene mesh into the urinary bladder after laparoscopic left direct and indirect inguinal repair has been reported to cause hematuria [4] and recurrent urinary tract infections. One report noted mesh plug migration into the scrotum after laparoscopic hernia repair that presented as a tender scrotal mass [5]. In another report involving scrotal migration of mesh, strangulating bowel obstruction was the presenting feature after intraabdominal placement of a mesh plug during a trauma laparotomy [6]. Several reports of resultant enteric [7] and enterovesical fistulas [8] have been reported. Successful colonoscopic removal of a migrated mesh from the colon at the splenic flexure has also been reported. After a literature review discussing the significant complications that result from mesh migration, the authors hypothesized that the method of fixation, as well as type of mesh, may have contributed to this problem.

The method of fixation may affect migration rates by altering the tensile strength and degree of movement of the mesh. The nature of the biomaterial is also important, as it affects the extent and degree of interaction with the surrounding tissue. The size, shape, and positioning of the mesh may also be significant. Biologic agents are being used with increasing frequency in abdominal wall hernias, where they have been

shown to decrease foreign body reaction and potential infectious complications. One study [1] reported that 3% of patients with hernias repaired with a mesh plug suffer from morbidity due to migration of the plug. This is the first reported case of tension free open type placed mesh that migrated into the cecum. There are one to two case reports of mesh migration into small bowel, bladder, large bowel, cecum, but all after laparoscopic repair of an inguinal hernia [9,10]. This is the first case after an open repair of an incisional hernia.

Once there is erosion of the mesh into the bowel, the question is whether or not it should be repaired. Repair would entail laparotomy, bowel resection, mesh resection, and anastomosis. However, there is a high likelihood of hernia recurrence after mesh removal, and placement of a mesh at the time of surgery may result in a high probability of postoperative infection. One solution would be a staged operation, with mesh/bowel resection first followed by a subsequent surgery to place a new mesh. Another would be to use biologic mesh at the time of cecal resection, but biologic meshes are costly and are associated with problems such as stretching and may become infected themselves.

In conclusion, mesh migration, particularly erosion, is a rare complication of any incisional hernia repair, especially when polypropylene mesh is used for repair. There is no clear cause of this complication, but new methods of mesh fixation, as well as types of mesh, are being investigated. It should also be recognized that mesh complications, particularly erosion, tend to occur years later and should be considered in atypical patient presentations. Tissue placement between the mesh and bowel to prevent direct contact of the two may help avoid this complication.

Given the popularity of these surgical procedures, complications may be frequently encountered. Gastroenterologists should thus be aware of the potential complications and the appropriate management.

References

1. Kingsnorth A, LeBlanc K. Hernias: inguinal and incisional. *Lancet* 2003;**362**:1561-1571.
2. Agrawal A, Avill R. Mesh migration following repair of inguinal hernia: a case report and review of literature. *Hernia* 2006;**10**:79-82.
3. Celik A, Kutun S, Kockar C, Mengi N, Ulucanlar H, Cetin A. Colonoscopic removal of inguinal hernia mesh: report of a case and literature review. *J Laparoendosc Adv Surg Tech A* 2005;**15**:408-410.
4. Hume RH, Bour J. Mesh migration following laparoscopic inguinal hernia repair. *J Laparoendosc Surg* 1996;**6**:333-335.
5. Dieter RA Jr. Mesh plug migration into scrotum: a new complication of hernia repair. *Int Surg* 1999;**84**:57-59.
6. Nowak DD, Chin AC, Singer MA, Helton WS. Large scrotal hernia: a complicated case of mesh migration, ascites, and bowel strangulation. *Hernia* 2005;**9**:96-99.
7. Murphy JW, Misra DC, Silverglide B. Sigmoid colonic fistula secondary to Perfixplug, left inguinal hernia repair. *Hernia* 2006;**10**:436-438.

8. Gray MR, Curtis JM, Elkington JS. Colovesical fistula after laparoscopic inguinal hernia repair. *Br J Surg* 1994;**81**:1213-1214.
9. Goswami R, Babor M, Ojo A. Mesh erosion into caecum following laparoscopic repair of inguinal hernia (TAPP): a case report and literature review. *J Laparoendosc Adv Surg Tech A* 2007;**17**:669-672.
10. Daas A, Matthew B, Elijah D, Kulkarni P. An unexpected mass: mesh migration into the cecum following inguinal hernia repair. *Gastroenterol Hepatol* 2009;**5**:361-364.