

<i>Letter to the Editor</i>

Roth-net for successful removal of a large gallstone causing gastric outlet obstruction (Bouveret's Syndrome)

P. Katsinelos, G. Chatzimavroudis, K. Fasoulas, S. Terzoudis, G. Lazaraki, I. Pilpilidis

Dear Sir,

Acute pyloroduodenal obstruction, a condition usually referred to as Bouveret's syndrome, may occur when a large gallstone gains access to the duodenum via a cholecystoduodenal fistula and becomes impacted in the duodenal bulb.¹ We describe a very elderly patient with severe comorbid diseases who presented Bouveret's syndrome and the impacted gallstone was successfully removed by a Roth-net of large size. To the best of our knowledge, a similar case has not been reported.

A 87-year-old woman was admitted to the Department of Internal Medicine complaining of upper abdominal pain and recurrent episodes of vomiting associated with nausea during the last 16 hours. Past medical history revealed heart failure stage III, hypertension and cholelithiasis, diagnosed 10 years ago. Laboratory data showed hypokalemic hypochloremic alkalosis, obviously due to profuse vomiting, Hb 14.8gr/dl, Ht 44%, urea nitrogen 87mg/dl, SGOT 77IU/L, SGPT 92IU/L, and alkaline phosphatase 196IU/L. Clinical examination demonstrated a very elderly woman mildly dehydrated with mild tenderness in the epigastric area. She received crystalloids (0.9% NaCl) to treat alkalosis and an abdominal x-ray showed the presence of air in the biliary tract. The second day after admission, an upper endoscopy demonstrated a large black stone obstructing the pyloric orifice (Fig. 1). Because the space of duodenal bulb permitted the manipulation of the stone, we decided to use a Roth-net of large size (diameter 3cm) for capture and removal of the stone (Fig. 2). The pa-

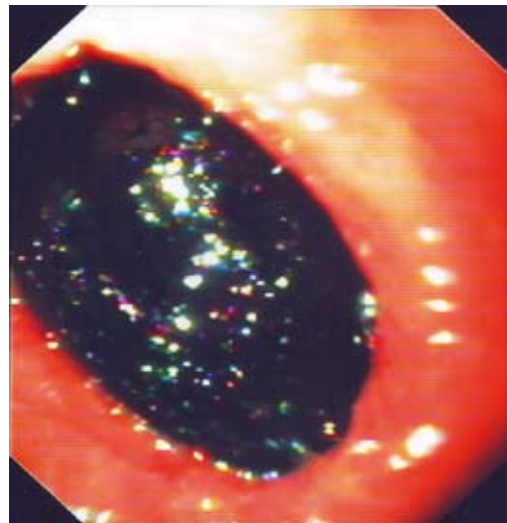


Figure 1. Endoscopic view of a black gallstone obstructing the pyloric orifice.

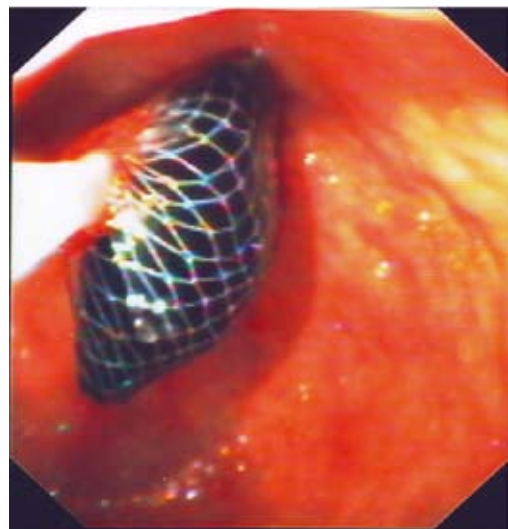


Figure 2. The gallstone was successfully retrieved by the Roth-net.

Department of Endoscopy and Motility Unit, G. Gennimatas General Hospital

Author for correspondence:

Panagiotis Katsinelos, Head, Department of Endoscopy and Motility Unit, G. Gennimatas General Hospital, Ethnikis Aminis 41, Thessaloniki, Greece, tel. 0030 2310 211221, fax: 0030 2310 210401, e-mail: gchatzimav@yahoo.gr

tient had an uneventful post-procedure course. The patient's general condition did not permit surgical intervention and she was discharged 5 days later.

To remove the obstructing calculus, endoscopic, laparoscopic and open surgical approaches have been attempted.²⁻⁴ Although the ideal treatment is to solve the obstruction by removing the gallstone, closing the fistula and preventing recurrence by cholecystectomy (which can be achieved by surgery), the therapeutic strategy should be chosen taking into consideration several aspects. Patient's age, comorbidities, the effect of obstruction on the general condition, the size of the gallstone and fistula and local inflammatory changes influence the decision on the patient's treatment.

We believe that endoscopic retrieval of an impacted gallstone in the duodenum, when clinically appropriate,

is suggested as a minimally invasive technique with negligible morbidity and mortality.

REFERENCES

1. Reisner RM, Cohen JR. Gallstone ileus: a review of 1001 reported cases. *Am Surg* 1994;60:441-446
2. Cappell MS, Davis M. Characterization of Bouveret's syndrome: a comprehensive review of 128 cases. *Am J Gastroenterol* 2006;101:2139-2146
3. Malvaux P, Degolla R, De Saint-Hubert M, Farchakh E, Hauters P. Laparoscopic treatment of a gastric outlet obstruction caused by a gallstone (Bouveret's syndrome). *Surg Endosc* 2002;16:1108-1109
4. Lowe AS, Stephenson S, Kay CL, May J. Duodenal obstruction by gallstones (Bouveret's syndrome: a review of the literature. *Endoscopy* 2005;37:82-87