

Case Report

Unique case of intestinal lymphangiectasia in an immunocompetent adult, caused by CMV and EBV co-infection

D. Kapetanios, H. Abuouda, F. Iordanidis, P. Katsinelos, G. Kitis

SUMMARY

Intestinal lymphangiectasia is a rare cause of protein losing enteropathy.¹ CMV infection is infrequently implicated in the pathogenesis of protein losing enteropathy and when this happens, the host is usually immunocompromised.²⁻⁶ We present a unique case of intestinal lymphangiectasia in an immunocompetent adult, caused by CMV and EBV co-infection.

Key words: Lymphangiectasia, protein losing enteropathy, CMV, EBV

CASE REPORT

A 36 year old male with acute diarrhoea (5-6 loose stools per day), fever (up to 38.5 °C), vomiting (1-2 times per day, after meals), abdominal pain, oedema ana sarca and weight loss (10 kg in 15 days) was admitted to our institution for further investigation. The clinical examination revealed mild ascites and left pleural effusion. The liver and spleen were not enlarged and there was no peripheral lymphadenopathy. Laboratory investigations showed leucocytosis (the WBC was 15500 K/uL [normal 4.9-10.8 K/uL] with 47% granulocytes and 45% lymphocytes), low total serum proteins 3.3g/dl (normal 6-8.4g/dl), low serum albumin 2.2g/dl (normal 3.5-5.1g/dl), AST 58IU/L (normal 10-40IU/L), ALT 39 IU/L (normal 10-40IU/L), γ GT 61IU/L (normal 20-75IU/L), alkaline phosphatase 55IU/L (normal 35-145IU/L), bilirubin 0.67mg/dl (normal 0.1-1.1mg/

dl), INR 1.3, blood urea 40mg/dl (normal 10-55mg/dl) and serum creatinine 1.27mg/dl (normal 0.9-1.7mg/dl). Tests for HIV, CMV and EBV infection were conducted because of fever and elevated aminotransferases and the results were: anti HIV-ve, IgM antiCMV+ve (1.166 IU/ml), IgG antiCMV+ve (59.5 IU/ml), IgM anti EBV+ve (>100 IU/ml), IgG anti EBV+ve (11.5 IU/ml). Computed tomography of the thorax and the abdomen showed mild ascites and pleural effusion, without lymphadenopathy. A cardiac ultrasound showed normal sized ventricles with 85% ejection fraction and a small quantity of pericardial fluid. Stool culture and examination for ova and parasites were normal. Esophago-gastro duodenoscopy, push enteroscopy and capsule endoscopy revealed oedema and diffuse white spots, which were compatible with lymphangiectasia of the duodenum and jejunum (Fig 1,2). Full colonoscopy including the terminal ileum was normal. Histological examination of jejunal biopsies confirmed the endoscopic findings (Fig 3a). No further tests for malabsorption were conducted. PCR examination of gastric biopsies was positive for EBV DNA (662 genoms/specimen) and CMV DNA (437 genoms/specimen) (Qiajen Artus). Jejunal biopsies were positive for EBV DNA (535 genoms/specimen). The immunophenotype of the lymphocytes showed increased CD8 cells with a ratio of CD4/CD8 0.4. Analytically, CD8 count was 2445 cells/uL (normal 250-1000), CD4 count was 1012 cells/uL (500-1500) and NK count was 207 cells/uL (80-350). These results suggest that the patient was not immunodeficient. The patient did not receive antiviral medication since his clinical condition improved gradually. Four months later IgM antiCMV was +ve (3.3 IU/ml), IgG antiCMV was +ve (364 IU/ml), IgM anti EBV was -ve and IgG anti EBV+ve (8.2 IU/ml). Nine months after the first presentation there was complete resolution of the histological changes (Fig 3b) but CD8 lymphocytosis persisted (1623 cells/uL) with the same CD4/CD8 ratio. The patient's

Gastroenterology Dept., "G. Papanikolaou" Hospital, Thessaloniki

Author for correspondence:

D. Kapetanios, "G. Papanikolaou" Hospital, Gastroenterology Dept., 57010 Thessaloniki, Greece, Tel: +30 2310 350102, Fax: +30 2310 359217, e-mail: dkapetan@otenet.gr

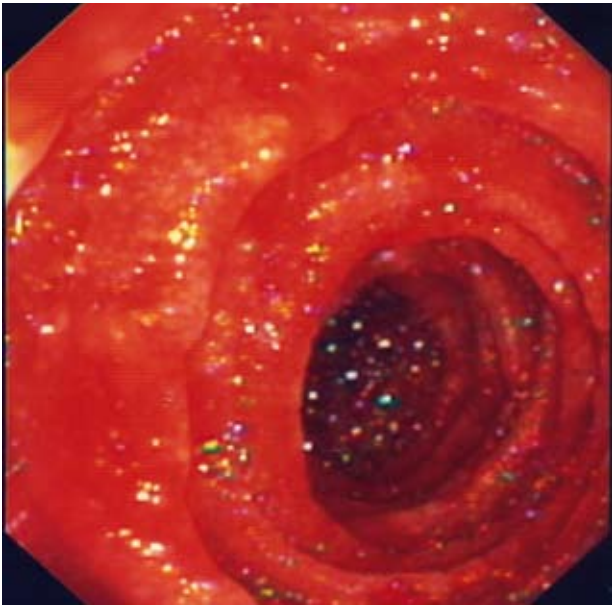


Figure 1. Mild oedema and white spots of the jejunum during push enteroscopy.

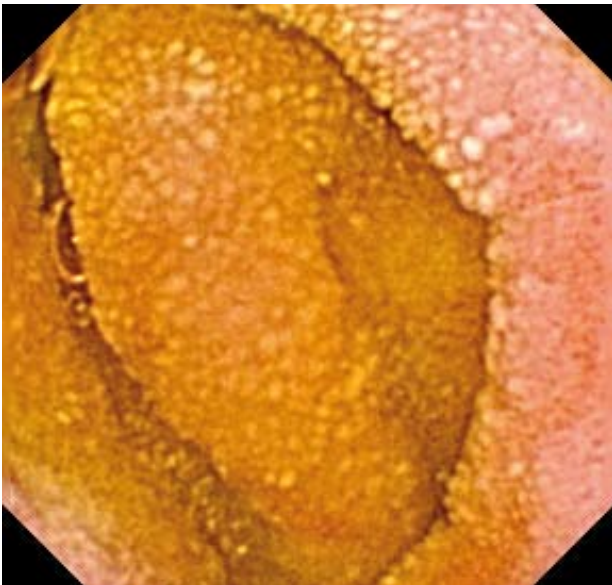


Figure 2. Lymphangiectatic lesions through the entire small intestine during capsule endoscopy.

clinical condition was excellent and all the biochemical results were normal. The IgM antiCMV was +ve (1.6 IU/ml), IgG antiCMV was +ve (1350 IU/ml), IgM anti EBV was -ve and IgG anti EBV +ve (9.4 IU/ml). Tissue PCR assays for the viruses were not repeated.

DISCUSSION

This is a case of enteric lymphangiectasia caused by

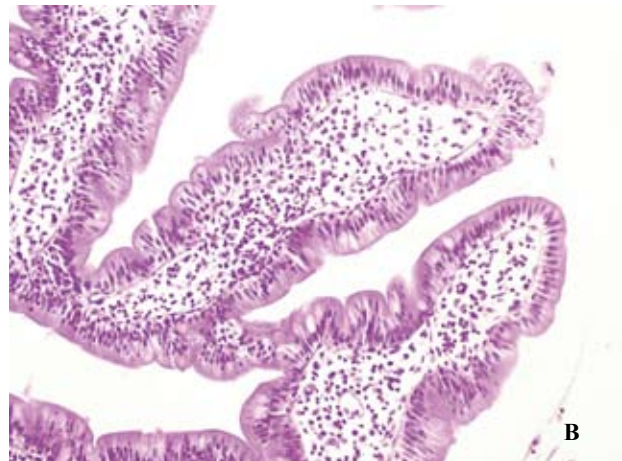
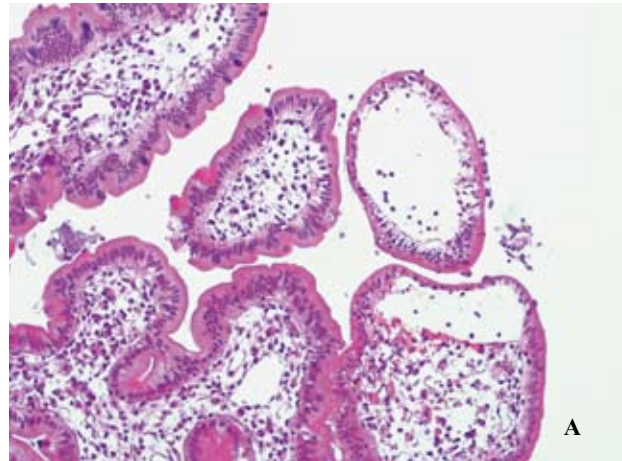


Figure 3. Large bulbous villi containing dilated lymphatic spaces a. at diagnosis and b. after 9 months.

viral infection in an immunocompetent adult. Acute CMV infection is a rare cause of protein losing enteropathy, presenting usually as Menetrier's disease in children. CMV infection may also affect immunocompromized adults, but there are scarce reports of CMV enteropathy in immunocompetent adults.²⁻⁶ This patient did not have endoscopic or histological findings of Menetrier's disease, but instead there was diffuse involvement of the small intestine, confirmed for the first time, to our knowledge, by capsule endoscopy and push enteroscopy. Typical inclusion bodies were not found in gastric biopsies, but CMV infection was diagnosed by positive IgM antibodies and detection of virus DNA in gastric specimens. The pathogenesis of lymphangiectasia in CMV infection has not been clarified. CMV can cause endothelial cell injury and attraction of leucocytes, leading to local inflammatory reaction.⁷ CMV can also activate Transforming Growth Factor β and increase collagen production.⁸ These changes may impair normal lymph flow and cause lymphangiectasia. It is noteworthy

that we also diagnosed acute EBV infection, which is not included in the known causes of protein losing enteropathy. Only one case is reported in the literature and this is in a child.⁹ We cannot speculate about the role of EBV co-infection, but it might have worsened the clinical features. Although CMV was not detected in the small intestine, we assume that this is a false negative result of the PCR assay, as CMV was detected in the gastric tissue. Ascites and pleural effusion was attributed to hypoalbuminemia.

Acute CMV enteropathy in children usually runs a self limited course, with good prognosis. However, the few case reports show that in adults the course is protracted, with slow recovery over months, but rarely has death been reported. Specialized antiviral therapy may shorten the disease duration. We did not treat our patient with antiviral drugs because his condition was already improved at diagnosis of CMV infection. However, complete recovery of the histological lesions was confirmed 9 months later.

This is, to our knowledge, the first case of CMV and EBV co-infection causing intestinal lymphangiectasia and protein losing enteropathy in an immunocompetent adult.

REFERENCES

- Peterson PB, Willard MD. Protein-losing enteropathies. *Vet Clin North Am Small Anim Pract* 2003; 33:1061-1082
- Bencharif L, Cathebras P, Bouchou K, et al. Exudative gastroenteropathy revealing primary CMV infection in an immunocompetent adult. *Rev Med Interne* 1998; 19:288-290
- Nakase H, Itani T, Mimura J, et al. Transient protein-losing enteropathy associated with cytomegalovirus infection in a noncompromised host: a case report. *Am J Gastroenterol* 1998; 93:1005-1006
- Setakhr V, Muller G, Hoang P, Lambert AS, Geubel A. Cytomegalovirus-associated protein losing gastropathy in an immunocompetent adult: a case report. *Acta Gastroenterol Belg* 2007; 70:296-299
- Suter WR, Neuweiler J, Borovicka J, et al. Cytomegalovirus-induced transient protein-losing hypertrophic gastropathy in an immunocompetent adult. *Digestion* 2000; 62:276-279
- Tajima T. An autopsy case of primary cytomegalic inclusion enteritis with remarkable hypoproteinemia. *Acta Pathol Jpn* 1974; 24:151-162
- Soderberg-Naucler C. Does cytomegalovirus play a causative role in the development of various inflammatory diseases and cancer? *J Intern Med* 2006; 259:219-246
- Tabata T, Kawakatsu H, Maidji E, et al. Induction of an Epithelial Integrin α v β 6 in Human Cytomegalovirus-Infected Endothelial Cells Leads to Activation of Transforming Growth Factor- β 1 and Increased Collagen Production. *Am J Pathol* 2008; 172:1127-1140
- Veres G, Bodanszky H, Dezsöfi A, et al. Transient protein-losing enteropathy associated with Epstein-Barr virus infection in an immunocompetent child: a case report. *Orv Hetil* 2004; 145:579-581