

# Endoscopic treatment modalities for the management of gastroparesis: a critical review

Dimitrios I. Ziogas<sup>a,b</sup>, Anastasios Manolakis<sup>b,c</sup>, Konstantinos Argyriou<sup>b,c</sup>, Ioannis S. Papanikolaou<sup>d</sup>, Elias Grivas<sup>e</sup>, Andreas Kapsoritakis<sup>b,c</sup>

Athens Naval Hospital, Athens, Greece; University of Thessaly, School of Medicine, Larisa, Greece; University Hospital of Larisa, Greece; Medical School, National and Kapodistrian University of Athens, Greece; Central Clinic of Athens, Athens, Greece

## Abstract

Gastroparesis, a chronic condition with complex etiopathogenesis, is associated with considerable symptom burden and significant morbidity. Dietary modifications and pharmacotherapy exhibit limited long-term efficacy, while surgical interventions are characterized by higher morbidity and variable efficacy. Endoscopic procedures, because of their less invasive nature, have been the focus of past and ongoing research. The majority of endoscopic treatment modalities target the pylorus: e.g., gastric peroral endoscopic pyloromyotomy, botulinum toxin injection, pyloric balloon dilatation, and transpyloric stent placement. Endoscopic feeding tube placement, endoscopic gastric electrical stimulation, and endoscopic ultrasound-guided gastroenterostomy have also been used to treat gastroparesis; however, these procedures are less well-studied. This critical review provides a detailed overview of the available endoscopic procedures for the management of gastroparesis, with emphasis on their pros and cons, quality of data and overall efficacy.

**Keywords** Gastroparesis, endoscopic treatment, G-POEM, Botox, stent

*Ann Gastroenterol* 2025; 38 (4): 353-363

<sup>a</sup>Department of Gastroenterology, Athens Naval Hospital, Athens, Greece (Dimitrios I. Ziogas); <sup>b</sup>University of Thessaly, School of Medicine, Larisa, Greece (Dimitrios I. Ziogas, Anastasios Manolakis, Konstantinos Argyriou, Andreas Kapsoritakis); <sup>c</sup>Department of Gastroenterology, University Hospital of Larisa, Greece (Anastasios Manolakis, Konstantinos Argyriou, Andreas Kapsoritakis); <sup>d</sup>Hepatogastroenterology Unit, Second Department of Internal Medicine-Propaedeutics, Medical School, National and Kapodistrian University of Athens, Greece (Ioannis S. Papanikolaou); <sup>e</sup>Department of Gastroenterology and Endoscopy Unit, Central Clinic of Athens, Athens, Greece (Elias Grivas)

Conflict of Interest: None

Correspondence to: Anastasios Manolakis, University of Thessaly School of Medicine, Viopolis 41500, Larisa, Greece; e-mail: amanwl@yahoo.com and manolakis@uth.gr

Received 6 May 2025; accepted 16 June 2025; published online 30 June 2025

DOI: <https://doi.org/10.20524/aog.2025.0982>

This is an open access journal, and articles are distributed under the terms of the Creative Commons Attribution-NonCommercial-ShareAlike 4.0 License, which allows others to remix, tweak, and build upon the work non-commercially, as long as appropriate credit is given and the new creations are licensed under the identical terms

## Introduction

Gastroparesis is a complex chronic disorder characterized by delayed gastric emptying in the absence of mechanical obstruction, presenting with symptoms such as nausea, vomiting, early satiety, postprandial fullness and epigastric pain [1]. Diabetes mellitus is the most commonly identified systemic condition associated with gastroparesis, while other causes include postsurgical complications, medications and neurologic disorders. In up to one third of cases, no clear etiology is identified, a condition referred to as idiopathic gastroparesis [1]. In terms of diagnosis, gastric-emptying (GE) scintigraphy remains the gold standard, with gastric retention rates of >60% at 2 and >10% at 4 h being considered diagnostic [1].

Managing patients with gastroparesis poses a significant challenge in everyday clinical practice. Dietary advice and pharmacologic therapy, particularly prokinetic drugs such as metoclopramide and domperidone, are first-line treatment modalities. In patients with refractory gastroparesis, surgical interventions such as pyloroplasty, pyloromyotomy, subtotal gastrectomy and gastric electrical stimulation (GES) implantation may be considered. These invasive procedures

are associated with considerable morbidity and exhibit variable efficacy across different patients [1]. Meanwhile, with the widespread use of gastrointestinal endoscopy, less invasive therapeutic modalities have emerged, such as endoscopic feeding tube placement, botulinum toxin injection, pyloric ring balloon dilatation, transpyloric stent placement and gastric peroral endoscopic pyloromyotomy (G-POEM) [1-3]. Most of these procedures target the pylorus, as pyloric dysfunction, particularly pylorospasm, has been identified as a key pathophysiological mechanism in a significant proportion of patients with gastroparesis.

The scope of the current review extends beyond a narrative overview of available methods, as it aims to provide a detailed assessment of each endoscopic procedure, while looking into its efficacy and safety profile across different patient subsets. Moreover, an analysis of each technique's pros and cons facilitates a clearer understanding of its role in patient management. Finally, a critical evaluation of study limitations and literature gaps is presented, along with procedure-related aspects requiring further investigation, with the aim of encouraging and guiding more focused future research.

## Materials and methods

### Literature search

A systematic search for original articles published through May 2025 was performed across PubMed, Embase, Scopus, and Google Scholar. The list of keywords that were used to identify relevant publications included: gastroparesis, endoscopy, therapy, dilatation, botulinum toxin, stent, gastric peroral endoscopic myotomy, endoscopic ultrasound, endoscopic gastrojejunostomy, endoscopic gastroenterostomy. Where applicable, keywords were combined in a literature search string: gastroparesis AND endoscopy OR endoscopic therapy OR dilatation OR botulinum toxin OR stent OR electrical stimulation OR gastric peroral myotomy OR endoscopic ultrasound OR gastroenterostomy.

The extensive literature search yielded 2534 articles. Articles in full paper format that were not written in English were excluded. Likewise, unrelated articles and narrative reviews were not included. Following the elimination process 200 articles remained for further assessment (Fig. 1).

### Parameters assessed

Based on the aforementioned search, 7 distinct endoscopic procedures used for the management of gastroparesis were identified. All relevant articles were examined with emphasis on diagnostic criteria, clinical success definitions and rates, procedural safety, including the rates and severity of adverse events, and patient and disease characteristics as predictors of treatment success and failure.

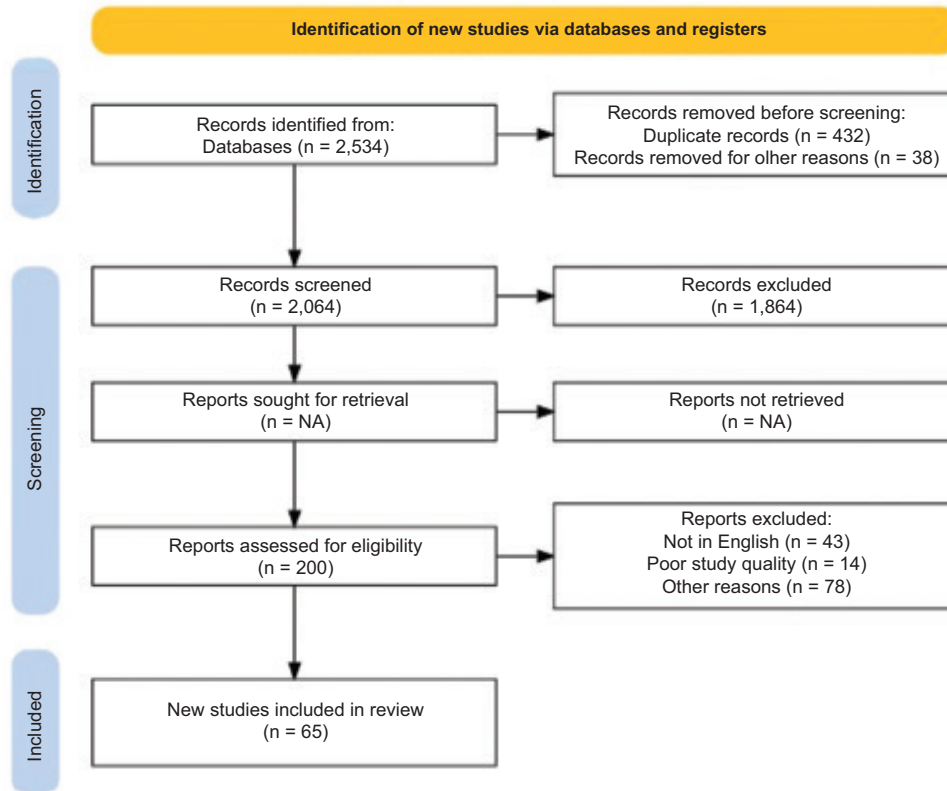
## G-POEM

Despite its relatively recent introduction, G-POEM has been extensively studied as an endoscopic treatment option for refractory gastroparesis. During an upper endoscopy, submucosal injection of a dye-containing solution is followed by a longitudinal or transverse mucosal incision, 3-5 cm proximal to the pyloric sphincter, usually along the greater curvature. The endoscope is then advanced into the submucosal space, and a tunnel extending to the pylorus is created. Myotomy is performed, and finally the mucosal incision is closed, either with endoscopic clips or suturing. When adequate expertise is available, G-POEM is consistently feasible, with most studies reporting a 100% technical success rate [2,3].

### Clinical efficacy

Khashab *et al* described the first case of G-POEM in a human patient in 2013, with a significant decrease in gastroparesis symptoms noticed during a follow-up period of 12 weeks [4]. The short-term clinical efficacy (3-6 months) of G-POEM in patients with gastroparesis ranges from 58-90% [5-7], while few recent meta-analyses have reported a pooled clinical success rate of 71-84% [8-10]. It is noteworthy that there was no standardized definition of clinical success among studies, with clinical success being expressed either as an improvement in the Gastroparesis Cardinal Symptom Index (GCSI) score, or as a subjective improvement in patients' symptoms. In cases where the GCSI score was applied, a decrease of at least 1 point in the average total GCSI score, with more than a 25% reduction in at least 2 subscales of cardinal symptoms, was the most frequent definition [11]. The major studies that assessed G-POEM outcomes beyond 12 months are summarized in Table 1. The clinical efficacy of G-POEM ranges from 33-94.3% at 1 year, from 50-89.9% at 2 years, and from 65.2-82.9% at 3 years, according to a recent systematic review [12-14]. In another recent meta-analysis, the pooled clinical success rate at 1 year was 72% ( $I^2=94.9\%$ ) and remained favorable at 2 and 3 years (71% and 58%, respectively) [15]. Three prospective studies, on the other hand, found lower 1-year clinical success rates, i.e., 33-56% [5,16,17]. Hernández Mondragón *et al* assessed the efficacy of G-POEM during a 4-year follow up in patients with refractory gastroparesis and found a remarkable clinical success rate of 77.5%, also accompanied by a significant decrease in hospitalizations (from 51.3% to 12.3%) [18]. Notably, the efficacy of G-POEM is evident for all the major symptoms of gastroparesis, as reflected by significant improvements in all GCSI subscales across studies [19,20]. A recent meta-analysis also demonstrated that G-POEM is equally effective across all major etiologies of the disease [21].

To our knowledge, there are 2 randomized trials evaluating the efficacy of G-POEM. Martinek *et al* reported the first randomized trial comparing G-POEM (n=21) with a sham procedure (n=19) for the treatment of refractory gastroparesis [22]. After 6 months, clinical success was significantly higher for patients in the G-POEM group



**Figure 1** Schematic representation of study selection process

compared to the sham group (71% vs. 22%). Moreover, crossover G-POEM was performed in 12 patients from the sham group, with clinical success observed in 9 (75%) after 6 months [22]. In the second randomized trial, Gonzalez *et al* found a higher, though not statistically significant, clinical efficacy of G-POEM compared to botulinum toxin injection at both 3 months and 1 year [23]. In terms of GE, recent meta-analyses have reported a 22-26% reduction in 4-h gastric retention rate following G-POEM, with significant heterogeneity across studies [10,24]. Another meta-analysis involving 8 studies reported an 84% rate for GE improvement (95% confidence interval [CI] 77-90%;  $I^2=0\%$ ;  $P=0.46$ ) and a 53% rate for GE normalization (95%CI 39-66%;  $I^2=46\%$ ;  $P=0.10$ ) [8].

#### **Endoscopic functional luminal imaging probe (EndoFLIP) as a tool for assessing pyloric dysfunction and G-POEM success**

EndoFLIP serves as a tool for estimating the distensibility of sphincters, as it measures pressure and cross-sectional area (CSA). Despite being introduced for the evaluation of the esophageal sphincter, various studies have described the utility of EndoFLIP for detecting pyloric dysfunction, which may help identify gastroparesis patients who could potentially benefit from pyloric interventions [25,26]. A few studies have also used EndoFLIP to evaluate the improvement in pyloric function following G-POEM. A retrospective study, conducted by Vousoughi *et al* [26], aimed to assess whether changes in

pyloric characteristics after G-POEM were correlated with clinical efficacy. According to the authors, G-POEM led to significant increases in both the CSA and distensibility index (DI), which were correlated with the clinical response of patients after 1 year. Moreover, post-procedural CSA was determined as the only significant predictor of clinical success (odds ratio [OR] 1.02, 95%CI 1.01-1.04;  $P=0.008$ ) [26]. Similarly, a prospective study reported a significant correlation between DI improvement, measured 3 months postoperatively, and clinical efficacy at 6 and 12 months ( $\chi^2=8.6$ ,  $P=0.003$  and  $\chi^2=3.5$ ,  $P=0.06$ , respectively) [16]. Regarding the predictive role of preoperative measurements, the data are more conflicting. Jacques *et al* [6], in their prospective study, reported that low pyloric distensibility before intervention, indicated by a DI of less than 9.2 mm<sup>2</sup>/mmHg, was predictive of clinical success after 3 months, with 100% specificity and 72.2% sensitivity ( $P=0.04$ ). In contrast, in the study by Vousoughi *et al* [26], patients with a clinical response 1 year after G-POEM had higher CSA and DI compared to non-responders.

#### **Other predictors of clinical success**

Setting aside pyloric function, additional factors that may influence G-POEM outcomes have been investigated. A few studies revealed an inverse relationship between gastroparesis duration and both the short- and long-term clinical efficacy of G-POEM based on GCSI score [11,18,20]. Ragi *et al* [20], in

**Table 1** Summary of studies assessing  $\geq 1$  year clinical efficacy of gastric peroral endoscopic pyloromyotomy (G-POEM)

Author [ref.] (year)	Study design	Number of patients	Gastroparesis etiology	Clinical success definition	Longest follow up	Clinical success rate (% of the available cohort)	Gastric emptying
Mekaroonkamol <i>et al</i> [12] (2019)	Single-center retrospective	30	Diabetic, idiopathic, post-surgical	A $\geq 1$ -point reduction in total GCSI score with $\geq 25\%$ decrease in at least 2 subscales	12 months	57% at 12 months	Improved in 78% Normalized in 48%
Vosoughi <i>et al</i> [25] (2020)	Multicenter retrospective	37	Diabetic, idiopathic, post-surgical	A $\geq 1$ -point reduction in total GCSI score with $\geq 25\%$ decrease in at least 2 subscales	12 months	70% at 12 months	Improved in 46% Normalized in 32%
Shen <i>et al</i> [14] (2020)	Single-center retrospective	23	Diabetic and other causes, idiopathic	A $\geq 1$ -point reduction in total GCSI score with $\geq 25\%$ decrease in at least 2 subscales	24 months	87% at 12 months 77% at 24 months	Improved in 80%
Conchillo <i>et al</i> [16] (2021)	Single-center prospective	24	Diabetic, idiopathic, post-surgical	At least a 1-point decrease in the mean overall GCSI score	12 months	33% at 12 months	NA
Abdelfatah <i>et al</i> [19] (2021)	Single-center retrospective	97	Diabetic, idiopathic, post-surgical	A $\geq 1$ -point reduction in total GCSI score with $\geq 25\%$ decrease in at least 2 subscales	36 months	69% at 12 months	Normalized in 63%
Ragi <i>et al</i> [21] (2021)	Multicenter retrospective	76	Diabetic, idiopathic, post-surgical	At least a 1-point decrease in the mean overall GCSI score	24 months	66% at 12 months 74% at 24 months	Significant reductions in 2 h and 4 h retention rate were noticed.
Tan <i>et al</i> [15] (2021)	Single-center retrospective	79	Post-surgical	A more than 25% decrease in at least 2 subscales of the GCSI scale	24 months	59% at 12 months 82% at 24 months	NA
Gregor <i>et al</i> [6] (2021)	Single-center prospective	52	Diabetic, idiopathic, post-surgical	A $\geq 1$ -point reduction in total GCSI score with $\geq 25\%$ decrease in at least 2 subscales	24 months	48% at 12 months	Gastric emptying improved compared to baseline
Vosoughi <i>et al</i> [17] (2022)	Multicenter prospective	75	Diabetic, idiopathic, post-surgical	A $\geq 1$ -point reduction in total GCSI score with $\geq 25\%$ decrease in at least 2 subscales	12 months	56% at 12 months	Evaluated in 53 patients Improved in 64% Normalized in 47%
Hernández Mondragón <i>et al</i> [18] (2022)	Single-center retrospective	374	Diabetic, idiopathic, post-surgical	A $\geq 1$ -point reduction in total GCSI score with $\geq 25\%$ decrease in at least 2 subscales	48 months	94.3% at 12 months 89.9% at 24 months 82.9% at 36 months 77.5% at 48 months	4 h retention rate improved from 44% (IQR 11-68) to 15.5% (IQR 0-36; P=0.021)
Labonde <i>et al</i> [20] (2022)	Retrospective (using prospectively collected data)	46	Diabetic, idiopathic, post-surgical and other causes.	A decrease of at least 1 point in the GCSI compared with the preprocedural GCSI score	36 months	69.5% at 12 months 69.5% at 24 months 65% at 36 months	NA

GCSI, gastroparesis cardinal symptom index; NA, not available; IQR interquartile range

their retrospective multicenter study, showed that patients with clinical failure at 24 months after G-POEM had a significantly longer disease duration compared to those who achieved a clinical response (92 months, interquartile range [IQR] 62-120 vs. 40 months, IQR 19-82;  $P=0.046$ , respectively). These findings were not replicated in a recent prospective study, as no significant correlation between symptom duration and response was recorded [19]. With regard to the etiology of gastroparesis, Hernández Mondragón *et al* [18] reported that, among 374 patients with refractory disease, the presence of diabetic gastroparesis increased the odds of long-term G-POEM success (OR 5.113, 95%CI 1.643-5.981;  $P=0.035$ ). Nevertheless, other studies observed no association between etiology and outcomes [9,19]. In a multicenter prospective study, overall baseline symptom severity was correlated with the clinical efficacy of G-POEM at 1 year (OR 3.23, 95%CI;  $P=0.04$ ) [17]. Various reports showed mixed results regarding the role of individual symptoms as predictors of clinical success. A higher GCSI satiety score was predictive of clinical success in 2 studies [19,20], while the presence of nausea or vomiting was related to clinical success in the study by Hernández Mondragón *et al* [18]. There is no agreement on whether severely impaired GE affects clinical outcomes after G-POEM [17,22]. Finally, G-POEM may have a particularly favorable effect in patients who previously responded to botulinum toxin injection. In a retrospective study of 119 patients who underwent both procedures, a prior response to toxin injection was predictive of clinical success after G-POEM (OR 2.3, 95%CI 1.2-4.6) [27]. Similar results were observed in 2 additional studies with smaller patient cohorts [5,28].

### Safety

Recent meta-analyses have reported an overall pooled adverse event rate related to G-POEM of 6-12% [8,29]. A multicenter retrospective study assessed the safety of G-POEM in 216 patients with refractory gastroparesis [30]. Overall, 31 adverse events were reported, most of which (73%) were classified as mild, and occurred within the first 48 h post-procedure (58%). Abdominal pain was the most frequent adverse event, affecting 15 patients; however, only 1 case was severe enough to require a laparotomy. Mucosotomy ( $n=5$ ) and capsuloperitoneum ( $n=4$ ) were the most common adverse events during the procedure, and were managed with endoscopic clip placement and needle decompression, respectively. Another multicenter study including 217 patients found a 0.4% rate of serious adverse effects [31]. Abdominal pain was present in 32 patients (14.7%), but required only analgesics in almost all cases. Four patients experienced bleeding within 24 h post-procedure, which resolved spontaneously without the need for endoscopic intervention. Additional studies found a rate between 3% and 7% for bleeding, managed either endoscopically or medically [20,32]. There have been concerns that G-POEM might lead to rapid gastric emptying and dumping syndrome, as observed with other pyloric interventions. Although data on this issue are limited, a recent meta-analysis reported that the

risk appears to be relatively low, with incidence rates ranging from 1.38-3.23% [33].

### Botulinum toxin injection

Botulinum toxin, produced by *Clostridium botulinum*, suppresses acetylcholine secretion at the neuromuscular junction, leading to transient paralysis. Botulinum toxin injection in the esophageal sphincter is used for the treatment of achalasia. This practice has been utilized for other functional disorders, including gastroparesis. It is hypothesized that the relaxation of the pyloric sphincter induced by toxin injection may improve GE and alleviate symptoms, particularly in cases where pyloric dysfunction is the primary underlying mechanism. To ensure this, botulinum toxin is injected intramuscularly into each of the 4 quadrants of the pyloric sphincter during an upper endoscopy. Many studies have assessed the efficacy of botulinum toxin in patients with gastroparesis of different etiologies, but they have yielded contradictory results. Small, open-label studies initially demonstrated significant improvements in both symptoms and GE [34-36]. Miller *et al* [36] reported on a prospective study of 10 patients with idiopathic gastroparesis who were treated with botulinum toxin (80-100 units). At 4 weeks post-procedure, improvement in symptoms and GE of solids was achieved in 90% and 70% of patients, respectively. However, after 6 months, a second injection was required in half of the patients because of symptom relapse. In order to confirm the results of the open-label studies, 2 randomized controlled studies were subsequently conducted. The first trial included 23 patients with predominantly idiopathic gastroparesis who underwent 2 upper endoscopies, separated by a 4-week interval, and received either 100 units of botulinum toxin or saline in a crossover strategy [37]. The authors reported no significant difference in symptom improvement between the 2 procedures, as both led to significant decreases in symptom severity, assessed by the GCSI score. Friedenber *et al* [38] conducted the second randomized trial, which included 32 patients who were randomized to receive either 200 units of botulinum toxin ( $n=16$ ) or saline ( $n=16$ ). In line with the findings of the previous study, significant reductions in symptom severity were documented in both groups, with no statistically significant difference between them (37.5% improvement with toxin vs. 56.3% with saline,  $P=0.29$ ). Notably, a significant effect on GE of solids was observed only in patients treated with toxin, although this effect was not significantly greater compared to the saline group ( $P=0.27$ ). In both studies, botulinum toxin injection demonstrated a safety profile equivalent to that of the placebo.

To overcome the limitations associated with small sample sizes, Coleski *et al* [39] conducted a large retrospective study of 179 patients to identify factors predictive of a clinical response after the procedure. Clinical success was significantly greater with a higher dose of toxin injection (200 units) compared to a lower dose (100 units), with an odds ratio of 2.79 (95%CI 1.20-6.51). This dose-dependent effect was more

evident for women, patients with idiopathic gastroparesis, and those under 50 years old. Approximately half of the patients in this cohort required repeated injections; however, improvement was sustained in most of them after the additional injection. Similarly, a recent prospective study found a favorable response to 200 units of botulinum toxin, with 16 of 25 patients (64%) experiencing symptomatic improvement at 1-month post-procedure [40]. Recently, endoscopic ultrasound (EUS)-guided botulinum toxin injection has garnered increasing attention for its potential to provide a more accurate delivery of the toxin into the *muscularis propria*. To our knowledge, only case reports exist on this subject, which have demonstrated clinical improvement in patients with diabetic gastroparesis [41,42]. Lastly, a recent study aimed to assess whether pyloric distensibility, as measured by endoFLIP, could predict the clinical response to toxin injection [43]. Among 35 patients, those with altered preprocedural pyloric distensibility (<10 mm<sup>2</sup>/mm Hg) exhibited superior improvement in symptoms, quality of life and GE at 3 months, compared to patients with normal distensibility values (>10 mm<sup>2</sup>/mm Hg).

### **Pyloric balloon dilatation**

Although less commonly used, pyloric balloon dilatation has been applied in clinical practice for gastroparesis. Two recent studies evaluated through-the-scope (TTS) balloon dilatation for the treatment of refractory gastroparesis. Jehangir *et al* [44] reported on a prospective study involving 13 patients with symptoms refractory to pyloromyotomy/pyloroplasty, who underwent TTS balloon dilatation of the pyloric sphincter up to 20 mm. Symptomatic improvement was found in 5 patients (38%) at 1 month. EndoFLIP measurements revealed significantly lower preprocedural pyloric distensibility in patients who responded to dilation compared to non-responders, with significant differences noted at 30 mL (4.7±0.8 vs. 13.2±2.9 mm<sup>2</sup>/mmHg, P=0.04), 40 mL (7.2±1.0 vs. 13.9±2.1 mm<sup>2</sup>/mmHg, P=0.02), and 50 mL (4.9±1.0 vs. 10.2±1.9 mm<sup>2</sup>/mmHg, P=0.04). No major adverse effects occurred. Moreover, in a retrospective study of 47 patients, TTS balloon dilation demonstrated a clinical success rate of 53% and 40% at 2 and 6 months, respectively, as characterized by a 1.0-point reduction in GCSI score [45]. This study also evaluated long-term efficacy, with a 32% clinical response after 2 years (median follow up: 27.0±10.4 months). Another retrospective study assessed the efficacy and safety of pyloric dilation with the esophageal FLIP (EsoFLIP), allowing for pyloric measurements during the dilation procedure [46]. Among 46 patients, the intervention was well-tolerated, with no severe adverse effects noticed except for epigastric pain post-procedure in 23 patients. Clinical success, defined as a >0.5-point decrease in GCSI score, was observed in 53% of patients after a mean follow-up period of 4 months. Additionally, significant improvements were achieved in both GE (from 211 to 179 min, P=0.001) and pyloric distensibility (from 9 to 13 mm<sup>2</sup>/mm Hg, P<0.001). Finally, in a small cohort of 10 patients, pyloric dilation with a 20 mm balloon improved

pyloric compliance, GE and quality of life after 10 days of follow up [47].

### **Transpyloric stent placement**

Transpyloric stent placement is another pylorus-targeted therapy; however, its efficacy in gastroparesis management has been investigated in only a handful of studies. A self-expandable metallic stent (SEMS) is advanced over a guidewire during upper endoscopy and deployed across the pylorus. The proximal flange of the stent is then usually anchored to the gastric wall, by either clips or endoscopic suturing, to reduce the risk of migration. Clarke *et al* [48] first reported the placement of SEMS in 3 patients with refractory gastroparesis, and showed improvement in both symptoms and GE. A retrospective study involving 30 patients with refractory gastroparesis found a 75% clinical response rate following SEMS placement, with the greatest improvement seen in symptoms of nausea and vomiting [49]. Notably, the authors also reported a high incidence of stent migration, occurring in 59% of patients, regardless of the anchorage method used. Another retrospective study aimed to identify whether lumen-apposing metal stent (LAMS) placement would reduce the risk of migration compared to SEMS. The broad flanges on both ends of the LAMS result in a better anchoring, thereby decreasing the risk of migration. In fact, LAMS placement demonstrated lower migration rates compared to SEMS (38% vs. 78%, P=0.07), while the clinical success rates were comparable between the 2 types of stent [50].

### **Endoscopic ultrasound-guided gastroenterostomy (EUS-GE)**

EUS-GE incorporates the fusion of the stomach and small intestine, most commonly the jejunum, using LAMS. To achieve this, an EUS-guided puncture of the targeted intestinal limb is first performed. This procedure is increasingly performed for the treatment of gastric outlet obstruction, and numerous studies have shown favorable outcomes in terms of both clinical efficacy and safety [51]. To our knowledge, only preliminary data exist regarding the role of EUS-GE in gastroparesis management. A retrospective study including 12 patients with gastroparesis refractory to G-POEM showed a clinical success rate of 75% at 6 months, with no reported adverse effects [52]. Another retrospective study reported that the clinical efficacy of EUS-GE, defined as a reduction in GCSI score of at least 50%, was 100% in a cohort of 7 patients with refractory gastroparesis. After 2.5 years of follow up, 5 of the 7 stents remained functional, whereas tissue ingrowth was evident in the remaining 2 [53].

### **Endoscopic feeding tube placement**

Endoscopically placed enteral tubes in the setting of refractory gastroparesis management involve endoscopic

venting gastrostomy and endoscopic jejunostomy. Percutaneous endoscopic gastrostomy (PEG) tube placement can decompress the stomach and relieve symptoms such as nausea and vomiting. To achieve this, a PEG tube is placed with the standard pull technique. A study by Kim *et al* [54] assessed the efficacy of PEG tube placement in 8 patients with refractory idiopathic gastroparesis and found a substantial and durable improvement in symptoms, with a median weight gain of 4.5 kg also observed across the group. In advanced cases where oral feeding is not feasible because of symptoms, or caloric intake is not optimal, post-pyloric nutrition with a jejunostomy is indicated [1]. Besides providing nutritional support, it also contributes to symptomatic relief by preventing the passage of food into the stomach. Temporary nasoduodenal or nasojejunal tube placement for 2-3 days often precedes jejunostomy to assess tolerance to enteral feeding. Either a PEG with a jejunal extension tube or a direct percutaneous endoscopic jejunostomy is then performed for long-term enteral nutrition. The former has the advantage of providing both gastric venting and nutritional support. On the other hand, this benefit may be counterbalanced by an increased risk of migration of the jejunal extension tube back to the stomach [55]. A recent meta-analysis demonstrated a higher tube malfunction rate for PEG with a jejunal tube compared to direct jejunostomy: 23.6% (95%CI 7.5-54.1%;  $P=90.8\%$ ) vs. 10.8% (95%CI 7.0-1.6%;  $P=7.8\%$ ), respectively [56]. However, there are no studies comparing the efficacy, patency and safety of these procedures specifically in patients with gastroparesis. A retrospective analysis revealed that PEG with jejunal tube extension exhibited a clinical efficacy of 37% in 19 patients with gastroparesis who had previously not responded to dietary advice, prokinetics and gastric rest [57]. Finally, direct percutaneous endoscopic jejunostomy placement appears to be associated with a lower incidence of adverse effects compared to surgical and radiologic placement methods [58].

## GES

GES, typically implanted surgically via laparoscopy or laparotomy, involves placing leads in the gastric *muscularis propria* and connecting them to a subcutaneous generator for electrical stimulation [59]. In various randomized studies, GES demonstrated a notable efficacy in improving symptoms [59]. An endoscopic approach using temporary electrodes has also been described to identify likely responders to permanent GES, thus helping to prevent unnecessary surgical procedures. The first report on this subject came from a retrospective study of 20 patients, in whom GES electrodes were placed either endoscopically (n=6) or via PEG (n=14) [60]. Overall symptom severity improved in 19 of the 20 patients, with no significant differences in improvement observed between the 2 groups. Abell *et al* [61] conducted a double-blind, placebo-controlled trial and reported a nonsignificant overall clinical effect with temporary GES in 58 patients with gastroparesis; nonetheless, improvement in vomiting and nausea symptoms was documented. A novel miniature, wireless, rechargeable

stimulator suitable for endoscopic placement has been introduced to overcome the issues associated with surgical GES placement while providing a durable effect; however, this method has only been evaluated in animal studies [62].

## Critical appraisal of evidence

There is a growing body of evidence regarding endoscopic procedures, mainly targeted at the pylorus, for the treatment of refractory gastroparesis. However, it is of paramount importance to recognize and consider the possible limitations inherent in the studies on this subject before drawing more definitive conclusions regarding the role of each procedure in patient management. First, as mentioned earlier, there is a variation in the definition of clinical success, which may lead to inconsistencies in the reported outcomes. Moreover, the majority of findings come from retrospective studies, which are susceptible to significant bias. Additionally, with the exception of G-POEM, there is currently a lack of data on the long-term efficacy of these procedures. Even for G-POEM, long-term efficacy has been evaluated primarily through retrospective studies; thus, the interpretation of the reported outcomes should be approached with caution. Notably, using the same definition, the 1-year clinical success rate of G-POEM ranges from 57-94% in retrospective studies and from 33-56% in prospective ones [5,16,17].

Regarding botulinum toxin injection, a point of debate in the existing literature is the dose required for a clinical effect, as it is unclear whether the response is dose-dependent [34,39]. As mentioned earlier, Coleski *et al* [39] reported a greater success rate with the injection of 200 units (76.7%) compared to 100 units (54.2%). In contrast, Bromer *et al* [34] failed to demonstrate any difference in clinical outcomes between 200 and 100 units. Studies evaluating pyloric balloon dilatation have used various techniques, including TTS balloon dilatation, pneumatic balloon dilatation, and more recently, dilatation with EsoFLIP. However, there are no comparative data to determine which of these techniques is most beneficial for gastroparesis patients.

Another source of heterogeneity arises from the different patient and disease characteristics among studies, which may affect procedure outcomes. Baseline pyloric dysfunction may be the most critical factor, as it could make certain patients more suitable candidates for pyloric interventions. In this regard, EndoFLIP could be a highly valuable tool, as it can assess pyloric function pre-procedurally, and it may also play a role post-procedurally by assessing changes in pyloric function and helping to estimate treatment outcomes. Nevertheless, some areas of uncertainty regarding its use and the interpretation of its measurements are yet to be clarified. Most reports indicate an inverse association between baseline pyloric compliance, DI, and the clinical efficacy of pyloric interventions; however, a definitive DI cutoff that reliably predicts favorable outcomes has not been established. Regarding postprocedural assessment, while improvements in both CSA and DI have been associated with symptom reduction after G-POEM, there is no agreement

in the current literature on which measurement carries the best predictive value.

### Clinical implications and future directions

The benefits and drawbacks of the available endoscopic interventions utilized for refractory gastroparesis are summarized in Table 2. G-POEM has received a lot of attention in recent years, as it appears to be effective in both alleviating symptoms and improving GE, while also demonstrating a favorable safety profile. This is reflected in current guidelines, which recommend G-POEM as a treatment modality for this condition [1,63]. That said, there still remains room to optimize the technical aspects of the procedure to further enhance its efficacy. Performing a single pyloromyotomy is the standard approach, although double pyloromyotomy in 2 distinct sites has also been described. In this context, a recent retrospective study comparing the short-term efficacy of double (n=35) vs. single (n=55) pyloromyotomy in 90 patients with refractory gastroparesis found significantly greater clinical success with double pyloromyotomy (86% vs. 67%,  $P=0.04$ ), while both methods demonstrated equivalent safety [64]. More data are needed to determine the role of double pyloromyotomy as a potential alternative to the standard technique. Based on case reports, redo pyloromyotomy, involving a new myotomy at a different site, can be considered a salvage option for patients

experiencing a relapse of symptoms following the initial procedure [65,66]. Moreover, it is vital to determine whether redo pyloromyotomy, other endoscopic interventions or surgery are the appropriate choice for patients who have not experienced clinical improvement following G-POEM, as data regarding the management of these patients are lacking. Currently, G-POEM is mainly performed in specialized centers by third-space endoscopy experts. The learning curve should be clearly defined, and a training curriculum should be established before this procedure can become widely adopted [67].

Despite the positive outcomes reported in open-label studies, the lack of significant clinical efficacy demonstrated in randomized trials led both American and European guidelines to recommend against the use of botulinum toxin for gastroparesis [1]. In most studies, the clinical effects last up to 6 months, so repeated injections are often necessary for patients to maintain symptom relief. This raises concerns about pyloric fibrosis and stenosis, as potential consequences of multiple injections [36]. Moreover, standardization of the toxin dose and technical aspects, such as the injection depth, should be further evaluated. At present, EUS-guided toxin injection has been documented solely in case reports. This technique may offer a more accurate delivery of the toxin into the *muscularis propria*, potentially leading to more effective and durable outcomes [42]. Given the short-term effect and the low adverse-events rate of pyloric balloon dilatation, this intervention could serve as a salvage method for prompt symptomatic improvement in hospitalized patients. It may also have a role in cases where

**Table 2** Advantages and disadvantages of endoscopic techniques for managing gastroparesis

Method	Advantages	Disadvantages
G-POEM	Only method with efficacy validated in a randomized trial Long-term efficacy compared to other pyloric interventions, safe	Still requires standardization Mainly performed in referral centers; more expertise required. Often requires hospitalization
Botulinum toxin injection	Minimally invasive, safe Simple procedure requiring less expertise compared to other endoscopic treatments Early patient discharge after the procedure	Short-term efficacy Multiple injections often needed for long-term effects, increasing the risk of pyloric fibrosis and stenosis Technical considerations, including toxin dose and delivery method, require standardization Not validated in randomized trials
Pyloric balloon dilation	Minimally invasive, safe Early patient discharge after the procedure Allows simultaneous measurement of pyloric characteristics to assess efficacy when using EsoFLIP	Short-term efficacy Lack of prospective or randomized data
Transpyloric stent placement	Minimally invasive Early patient discharge after the procedure	Short-term efficacy High migration rate, often requiring reintervention Lack of prospective or randomized data
EUS-GE	Increased patency and lower migration rates compared to transpyloric stent placement.	Only preliminary data available Technically challenging, not standardised Mainly performed in referral centers
Endoscopic gastric electrical stimulation	Less invasive than surgical placement, primarily used to assess responsiveness	Lack of human studies on the novel miniature wireless stimulator as a durable treatment option

G-POEM, gastric peroral endoscopic pyloromyotomy; EsoFLIP, esophageal FLIP. EUS-GE, endoscopic ultrasound-guided gastroenterostomy



**Table 3** Major studies assessing the predictive role of endoscopic functional luminal imaging probe (EndoFLIP) measurements in pyloric interventions

Author [ref.] (year)	Procedure	Study design	Number of patients	Assessment timing	EndoFLIP measurement	Findings
Jacques <i>et al</i> [7] (2019)	G-POEM	Single-center prospective	20	Pre/post (3 months)	DI (mm <sup>2</sup> /mmHg)	Pre-procedural DI <9.2 mm <sup>2</sup> /mmHg was correlated with clinical efficacy (100% specificity, 72.2% sensitivity, P=0.04)
Vosoughi <i>et al</i> [25] (2020)	G-POEM	Multicenter retrospective	37	Pre/post (immediately or 3 months)	CSA (mm <sup>2</sup> ) DI (mm <sup>2</sup> /mmHg)	Pre: DI at 40 mL and CSA at 50 mL were significantly higher in patients with symptom improvement after the procedure (P<0.05). Post: Increases in both the CSA and DI, were correlated with patients' clinical response after 1 year. CSA >154 mm <sup>2</sup> at 40 mL had an accuracy of 77%, sensitivity of 71%, and specificity of 91% for predicting 1-year clinical success.
Conchillo <i>et al</i> [16] (2021)	G-POEM	Single-center prospective	24	Post (3 months)	DI (mm <sup>2</sup> /mmHg)	DI improvement was significantly associated with clinical efficacy at 6 and 12 months ( $\chi^2=8.6$ , P=0.003 and $\chi^2=3.5$ , P=0.06, respectively)
Gregor <i>et al</i> [6] (2021)	G-POEM	Single-center prospective	52	Pre/post (3 months)	DI (mm <sup>2</sup> /mmHg)	No association found between DI and clinical success
Desprez <i>et al</i> [43] (2019)	Botulinum toxin injection	Multicenter prospective	35	Pre	DI (mm <sup>2</sup> /mmHg)	Decreased pre-procedural DI (<10mm <sup>2</sup> /mmHg) was predictive of symptomatic response 3 months after the procedure
Jehangir <i>et al</i> [44] (2021)	Pyloric balloon dilation	Single-center retrospective	13	Pre	DI (mm <sup>2</sup> /mmHg)	Patients with symptomatic improvement post-dilation had significantly lower baseline distensibility compared to non-responders
Murray <i>et al</i> [46] (2021)	Pyloric balloon dilation	Single-center retrospective	46	Post	DI (mm <sup>2</sup> /mmHg)	A significant decrease in GCSI of 0.9 points was observed for every 10 mm <sup>2</sup> /mm Hg increase in post-interventional DI (P=0.012)

EndoFLIP, endoscopic functional luminal imaging probe. G-POEM, gastric peroral endoscopic pyloromyotomy. DI, distensibility index. CSA, cross-sectional area; GCSI, gastroparesis cardinal symptom index

G-POEM has failed, as demonstrated in the study by Jehangir *et al* [44]. Long-term efficacy should be assessed to identify whether it could function as a long-lasting treatment.

Stent migration is a serious and common drawback of transpyloric stent placement, which, along with the lack of prospective data, makes current guidelines advocate against its use [63]. Methods for preventing this complication, such as the use of LAMS, are considered mandatory.

Finally, irrespective of the exact intervention, the correct identification of patients who may benefit the most from pylorus targeted therapy is essential for optimizing outcomes. EndoFLIP measurements may have a significant role in guiding treatment decisions. The results of studies on this aspect are summarized in Table 3. However, as previously noted, this method currently lacks standardization because there are insufficient data on specific pyloric parameters and their associated cutoff values with the highest predictive value. These aspects must be clarified in further studies to enable the widespread and reliable use of EndoFLIP.

EUS-GE represents a promising treatment for gastric outlet obstruction, and preliminary data suggest that this intervention may also be effective in patients with gastroparesis. However, it is important to note that the pathophysiology of symptoms

differs between these conditions, so more studies, especially prospective ones, are required to assess the performance of EUS-GE in gastroparesis. Currently, this procedure should be performed solely in an experimental setting for this indication.

## Concluding remarks

Despite recent advances in the understanding and treatment of gastroparesis, this disorder remains associated with considerable morbidity for patients. Moreover, it poses a significant problem for the healthcare system, given the frequent hospitalizations and the need for ongoing pharmacotherapy and prescription. Currently, numerous endoscopic procedures are available for patients who are unresponsive to pharmacological therapy, with G-POEM showing the most compelling data among them. However, heterogeneity in study characteristics, particularly in patient selection, has resulted in inconsistencies in reported outcomes and, along with the lack of randomized trials and the limited durability of some procedures (e.g., botulinum toxin injection, balloon dilatation), has hindered the widespread adoption of these techniques. Moreover, technical

aspects, such as the lack of standardization and the high level of expertise required specifically for G-POEM and EUS-GE, represent additional concerns that must be addressed to enable the broader implementation of these interventions. Future research should focus on better elucidating the underlying pathophysiological mechanisms responsible for gastroparesis, allowing the application of targeted therapies tailored to the specific mechanisms in each patient. Finally, further comparative studies are essential to provide a clearer understanding of the efficacy and outcomes of different endoscopic interventions.

## References

1. Camilleri M, Kuo B, Nguyen L, et al. ACG Clinical Guideline: Gastroparesis. *Am J Gastroenterol* 2022;**117**:1197-1220.
2. Soliman H, Gourcerol G. Targeting the pylorus in gastroparesis: from physiology to endoscopic pyloromyotomy. *Neurogastroenterol Motil* 2023;**35**:e14529.
3. Yan J, Tan Y, Zhou B, Zhang S, Wang X, Liu D. Gastric per-oral endoscopic myotomy (G-POEM) is a promising treatment for refractory gastroparesis: a systematic review and meta-analysis. *Rev Esp Enferm Dig* 2020;**112**:219-228.
4. Khashab MA, Stein E, Clarke JO, et al. Gastric peroral endoscopic myotomy for refractory gastroparesis: first human endoscopic pyloromyotomy (with video). *Gastrointest Endosc* 2013;**78**:764-768.
5. Gregor L, Wo J, DeWitt J, et al. Gastric peroral endoscopic myotomy for the treatment of refractory gastroparesis: a prospective single-center experience with mid-term follow-up (with video). *Gastrointest Endosc* 2021;**94**:35-44.
6. Jacques J, Pagnon L, Hure F, et al. Peroral endoscopic pyloromyotomy is efficacious and safe for refractory gastroparesis: prospective trial with assessment of pyloric function. *Endoscopy* 2019;**51**:40-49.
7. Khashab MA, Ngamruengphong S, Carr-Locke D, et al. Gastric per-oral endoscopic myotomy for refractory gastroparesis: results from the first multicenter study on endoscopic pyloromyotomy (with video). *Gastrointest Endosc* 2017;**85**:123-128.
8. Li P, Ma B, Gong S, Zhang X, Li W. Gastric per-oral endoscopic myotomy for refractory gastroparesis: a meta-analysis. *J Gastrointest Surg* 2021;**25**:1108-1116.
9. Mohan BP, Chandan S, Jha LK, et al. Clinical efficacy of gastric peroral endoscopic myotomy (G-POEM) in the treatment of refractory gastroparesis and predictors of outcomes: a systematic review and meta-analysis using surgical pyloroplasty as a comparator group. *Surg Endosc* 2020;**34**:3352-3367.
10. Uemura KL, Chaves D, Bernardo WM, Uemura RS, de Moura DTH, de Moura EGH. Peroral endoscopic pyloromyotomy for gastroparesis: a systematic review and meta-analysis. *Endosc Int Open* 2020;**8**:E911-E923.
11. Mekaroonkamol P, Dacha S, Wang L, et al. Gastric peroral endoscopic pyloromyotomy reduces symptoms, increases quality of life, and reduces health care use for patients with gastroparesis. *Clin Gastroenterol Hepatol* 2019;**17**:82-89.
12. Shen S, Luo H, Vachaparambil C, et al. Gastric peroral endoscopic pyloromyotomy versus gastric electrical stimulation in the treatment of refractory gastroparesis: a propensity score-matched analysis of long term outcomes. *Endoscopy* 2020;**52**:349-358.
13. Stojilkovic T, Staudinger K, Dennis J. A systematic review of the long-term clinical success of gastric peroral endoscopic myotomy for refractory gastroparesis. *Cureus* 2023;**15**:e39709.
14. Tan J, Shrestha SM, Wei M, et al. Feasibility, safety, and long-term efficacy of gastric peroral endoscopic myotomy (G-POEM) for postsurgical gastroparesis: a single-center and retrospective study of a prospective database. *Surg Endosc* 2021;**35**:3459-3470.
15. Mandarino FV, Barchi A, Salmeri N, et al. Long-term efficacy (at and beyond 1 year) of gastric peroral endoscopic myotomy for refractory gastroparesis: A systematic review and meta-analysis. *DEN Open* 2025;**5**:e70021.
16. Conchillo JM, Straathof JWA, Mujagic Z, et al. Gastric peroral endoscopic pyloromyotomy for decompensated gastroparesis: comprehensive motility analysis in relation to treatment outcomes. *Endosc Int Open* 2021;**9**:E137-E144.
17. Vosoughi K, Ichkhanian Y, Benias P, et al. Gastric per-oral endoscopic myotomy (G-POEM) for refractory gastroparesis: results from an international prospective trial. *Gut* 2022;**71**:25-33.
18. Hernández Mondragón OV, Contreras LFG, Velasco GB, Pineda OMS, Carrillo DMC, Perez EM. Gastric peroral endoscopic myotomy outcomes after 4 years of follow-up in a large cohort of patients with refractory gastroparesis (with video). *Gastrointest Endosc* 2022;**96**:487-499.
19. Labonde A, Lades G, Debourdeau A, et al. Gastric peroral endoscopic myotomy in refractory gastroparesis: long-term outcomes and predictive score to improve patient selection. *Gastrointest Endosc* 2022;**96**:500-508.
20. Ragi O, Jacques J, Branche J, et al. One-year results of gastric peroral endoscopic myotomy for refractory gastroparesis: a French multicenter study. *Endoscopy* 2021;**53**:480-490.
21. Malik S, Loganathan P, Khan K, Mohan BP, Adler DG. Efficacy and safety of gastric peroral endoscopic myotomy across different etiologies of gastroparesis: systematic review and meta-analysis. *Gastrointest Endosc* 2025;**101**:54-67.
22. Martinek J, Hustak R, Mares J, et al. Endoscopic pyloromyotomy for the treatment of severe and refractory gastroparesis: a pilot, randomised, sham-controlled trial. *Gut* 2022;**71**:2170-2178.
23. Gonzalez JM, Mion F, Pioche M, et al. Gastric peroral endoscopic myotomy versus botulinum toxin injection for the treatment of refractory gastroparesis: results of a double-blind randomized controlled study. *Endoscopy* 2024;**56**:345-352.
24. Aghaie Meybodi M, Qumseya BJ, Shakoor D, et al. Efficacy and feasibility of G-POEM in management of patients with refractory gastroparesis: a systematic review and meta-analysis. *Endosc Int Open* 2019;**7**:E322-E329.
25. Snape WJ, Lin MS, Agarwal N, Shaw RE. Evaluation of the pylorus with concurrent intraluminal pressure and EndoFLIP in patients with nausea and vomiting. *Neurogastroenterol Motil* 2016;**28**:758-764.
26. Vosoughi K, Ichkhanian Y, Jacques J, et al. Role of endoscopic functional luminal imaging probe in predicting the outcome of gastric peroral endoscopic pyloromyotomy (with video). *Gastrointest Endosc* 2020;**91**:1289-1299.
27. Wadhwa V, Gonzalez A, Azar F, et al. Response to botulinum toxin may predict response to peroral pyloromyotomy in patients with gastroparesis. *Endoscopy* 2023;**55**:508-514.
28. Monino L, Gonzalez JM, Barthet M, Vitton V. Role of pyloric botulinum injection and endoscopic functional luminal imaging probe in predicting the outcome of gastric peroral endoscopic pyloromyotomy: why not? *Gastrointest Endosc* 2020;**92**:798-799.
29. Spadaccini M, Maselli R, Chandrasekar VT, et al. Gastric peroral endoscopic pyloromyotomy for refractory gastroparesis: a systematic review of early outcomes with pooled analysis. *Gastrointest Endosc* 2020;**91**:746-752.
30. Ichkhanian Y, Vosoughi K, Aghaie Meybodi M, et al. Comprehensive analysis of adverse events associated with gastric peroral endoscopic myotomy: an international multicenter study. *Surg Endosc* 2021;**35**:1755-1764.
31. Baret F, Jacques J, Pioche M, et al. Evaluation of the safety profile of endoscopic pyloromyotomy by G-POEM: a French multicenter

- study. *Therap Adv Gastroenterol* 2022;**15**:17562848221122472.
32. Kahaleh M, Gonzalez JM, Xu MM, et al. Gastric peroral endoscopic myotomy for the treatment of refractory gastroparesis: a multicenter international experience. *Endoscopy* 2018;**50**:1053-1058.
  33. Shargo R, Poonen-Honig I, Thélin C, et al. Dumping syndrome and bile acid reflux following pyloroplasty and gastric peroral endoscopic myotomy (G-POEM) for refractory gastroparesis: a systematic review. *Cureus* 2025;**17**:e79056.
  34. Bromer MQ, Friedenberg F, Miller LS, Fisher RS, Swartz K, Parkman HP. Endoscopic pyloric injection of botulinum toxin A for the treatment of refractory gastroparesis. *Gastrointest Endosc* 2005;**61**:833-839.
  35. Ezzeddine D, Jit R, Katz N, Gopalswamy N, Bhutani MS. Pyloric injection of botulinum toxin for treatment of diabetic gastroparesis. *Gastrointest Endosc* 2002;**55**:920-923.
  36. Miller LS, Szych GA, Kantor SB, et al. Treatment of idiopathic gastroparesis with injection of botulinum toxin into the pyloric sphincter muscle. *Am J Gastroenterol* 2002;**97**:1653-1660.
  37. Arts J, Holvoet L, Caenepeel P, et al. Clinical trial: a randomized-controlled crossover study of intrapyloric injection of botulinum toxin in gastroparesis. *Aliment Pharmacol Ther* 2007;**26**:1251-1258.
  38. Friedenberg FK, Palit A, Parkman HP, Hanlon A, Nelson DB. Botulinum toxin A for the treatment of delayed gastric emptying. *Am J Gastroenterol* 2008;**103**:416-423.
  39. Coleski R, Anderson MA, Hasler WL. Factors associated with symptom response to pyloric injection of botulinum toxin in a large series of gastroparesis patients. *Dig Dis Sci* 2009;**54**:2634-2642.
  40. Reichenbach ZW, Stanek S, Patel S, et al. Botulinum toxin A improves symptoms of gastroparesis. *Dig Dis Sci* 2020;**65**:1396-1404.
  41. Guo H, Fang C, Huang Y, et al. Treatment of diabetic gastroparesis with botulinum toxin injection guided by endoscopic ultrasound in a patient with type 1 diabetes: the first report. *Acta Diabetol* 2017;**54**:509-511.
  42. Yin G, Tan W, Hu D. Endoscopic ultrasonography-guided intrapyloric injection of botulinum toxin to treat diabetic gastroparesis. *Dig Endosc* 2016;**28**:759.
  43. Desprez C, Melchior C, Wuestenberghs F, et al. Pyloric distensibility measurement predicts symptomatic response to intrapyloric botulinum toxin injection. *Gastrointest Endosc* 2019;**90**:754-760.
  44. Jehangir A, Malik Z, Petrov RV, Parkman HP. EndoFLIP and pyloric dilation for gastroparesis symptoms refractory to pyloromyotomy/pyloroplasty. *Dig Dis Sci* 2021;**66**:2682-2690.
  45. Soliman H, Oiknine E, Cohen-Sors B, et al. Efficacy and safety of endoscopic pyloric balloon dilation in patients with refractory gastroparesis. *Surg Endosc* 2022;**36**:8012-8020.
  46. Murray FR, Schindler V, Hente JM, et al. Pyloric dilation with the esophageal functional lumen imaging probe in gastroparesis improves gastric emptying, pyloric distensibility, and symptoms. *Gastrointest Endosc* 2021;**94**:486-494.
  47. Gourcerol G, Tissier F, Melchior C, et al. Impaired fasting pyloric compliance in gastroparesis and the therapeutic response to pyloric dilatation. *Aliment Pharmacol Ther* 2015;**41**:360-367.
  48. Clarke JO, Sharaiha RZ, Kord Valeshabad A, Lee LA, Kalloo AN, Khashab MA. Through-the-scope transpyloric stent placement improves symptoms and gastric emptying in patients with gastroparesis. *Endoscopy* 2013;**45** Suppl 2 UCTN: E189-E190.
  49. Khashab MA, Besharati S, Ngamruengphong S, et al. Refractory gastroparesis can be successfully managed with endoscopic transpyloric stent placement and fixation (with video). *Gastrointest Endosc* 2015;**82**:1106-1109.
  50. Dean G, Liu K, Brenner DM, Kahrilas PJ, Pandolfino JE, Aadam AA. Sa2015 Transpyloric stenting in refractory gastroparesis: lumen apposing metal stent is associated with decreased stent migration and is a predictor for clinical success of gastric per-oral endoscopic pyloromyotomy (GPOEM). *Gastrointest Endosc* 2020;**91**:AB243.
  51. Ziogas D, Vasilakis T, Kapizioni C, et al. Revealing insights: a comprehensive overview of gastric outlet obstruction management, with special emphasis on EUS-guided gastroenterostomy. *Med Sci (Basel)* 2024;**12**:9.
  52. Gonzalez JM, Gasmi M, Vitton V, Barthet M. Drain-assisted EUS-guided gastroenterostomy in the treatment of gastroparesis refractory to endoscopic pyloromyotomy by GPOEM: a novel promising therapeutic option. *Endoscopy* 2024;**56**(S 02):S80-S81.
  53. Heilmair M, Schulz D, Ulrich J, Wiefner JR, Abbassi R, Abdelhazef M. EUS-guided gastroenterostomy to treat refractory gastroparesis: preliminary results of the first German experience. *Endoscopy* 2024;**56**(S 02):S82.
  54. Kim CH, Nelson DK. Venting percutaneous gastrostomy in the treatment of refractory idiopathic gastroparesis. *Gastrointest Endosc* 1998;**47**:67-70.
  55. Limketkai BN, LeBrett W, Lin L, Shah ND. Nutritional approaches for gastroparesis. *Lancet Gastroenterol Hepatol* 2020;**5**:1017-1026.
  56. Deliwala SS, Chandan S, Kumar A, et al. Direct percutaneous endoscopic jejunostomy (DPEJ) and percutaneous endoscopic gastrostomy with jejunal extension (PEG-J) technical success and outcomes: systematic review and meta-analysis. *Endosc Int Open* 2022;**10**:E488-E520.
  57. Srijbos D, Keszthelyi D, Smeets FGM, et al. Therapeutic strategies in gastroparesis: Results of stepwise approach with diet and prokinetics, Gastric Rest, and PEG-J: a retrospective analysis. *Neurogastroenterol Motil* 2019;**31**:e13588.
  58. Ramai D, Heaton J, Fang J. Safety of percutaneous endoscopic jejunostomy placement compared with surgical and radiologic jejunostomy placement: a nationwide inpatient assessment. *J Clin Gastroenterol* 2024;**58**:902-911.
  59. Petrov RV, Bakhos CT, Abbas AE, Malik Z, Parkman HP. Endoscopic and surgical treatments for gastroparesis: what to do and whom to treat? *Gastroenterol Clin North Am* 2020;**49**:539-556.
  60. Ayinala S, Batista O, Goyal A, et al. Temporary gastric electrical stimulation with orally or PEG-placed electrodes in patients with drug refractory gastroparesis. *Gastrointest Endosc* 2005;**61**:455-461.
  61. Abell TL, Johnson WD, Kedar A, et al. A double-masked, randomized, placebo-controlled trial of temporary endoscopic mucosal gastric electrical stimulation for gastroparesis. *Gastrointest Endosc* 2011;**74**:496-503.
  62. Deb S, Tang SJ, Abell TL, et al. Development of innovative techniques for the endoscopic implantation and securing of a novel, wireless, miniature gastrostimulator (with videos). *Gastrointest Endosc* 2012;**76**:179-184.
  63. Weusten BLAM, Barret M, Bredenoord AJ, et al. Endoscopic management of gastrointestinal motility disorders - part 1: European Society of Gastrointestinal Endoscopy (ESGE) Guideline. *Endoscopy* 2020;**52**:498-515.
  64. Abdelfatah MM, Li B, Kapil N, et al. Short-term outcomes of double versus single pyloromyotomy at peroral endoscopic pyloromyotomy in the treatment of gastroparesis (with video). *Gastrointest Endosc* 2020;**92**:603-609.
  65. Dražilová D, Vacková Z, Husfak R, Buncová M, Martínek J. Successful repeated gastric peroral endoscopic myotomy (re-G-POEM) in the treatment of postsurgical gastroparesis. *Rozhl Chir* 2022;**101**:37-41.
  66. Monino L, Gonzalez JM, Barthet M, Vitton V. Redo gastric peroral endoscopic myotomy in case of recurrence of gastroparesis after the first GPOEM: It seemed to be a good option! *Gastrointest Endosc* 2020;**92**:975-976.
  67. Reja M, Mishra A, Tyberg A, et al. Gastric peroral endoscopic myotomy: a specific learning curve. *J Clin Gastroenterol* 2022;**56**:339-342.