

Use of nailfold capillaroscopy for the early diagnosis of systemic sclerosis in patients with primary biliary cholangitis

Daniele Crescenzi^{a*}, Daniele Balducci^{a*}, Marta Mazzetti^a, Denise Menghini^b, Chiara Gelardi^b, Veronica Pedini^b, Cristina Mezzanotte^b, Giuseppe Tarantino^a, Antonio Benedetti^a, Maria Giovanna Danieli^b, Marco Marzioni^a, Luca Maroni^a

Università Politecnica delle Marche, Ancona, Italy

Abstract

Background Primary biliary cholangitis (PBC) is a cholestatic autoimmune disease and is often associated with systemic sclerosis (SSc). The prevalence of SSc in PBC patients ranges from 1-22% and the diagnosis is often delayed. The aim of this study was to evaluate the role of nailfold capillaroscopy (NFC) for early SSc diagnosis in PBC patients.

Methods In this monocentric, cross-sectional study, NFC was performed in 56 PBC patients. Raynaud's phenomenon (RP) was assessed in each patient. Patients with major NFC abnormalities and those with a scleroderma pattern were screened for SSc-specific antibodies. The SSc diagnosis was established using the 2013 American College of Rheumatology and European League Against Rheumatism (ACR/AULAR) and Very Early Diagnosis Of Systemic Sclerosis (VEDOSS) criteria.

Results NFC abnormalities were found in 31 patients (55%): 11 (20%) presented minor abnormalities, 17 (30%) had major abnormalities and 3 (5%) presented a scleroderma pattern. RP was found in 12 patients. Two patients with a scleroderma pattern were newly diagnosed with SSc. All patients newly diagnosed with SSc presented RP. No patient without RP was diagnosed with SSc.

Conclusions Performing NFC in PBC patients can help anticipate the SSc diagnosis. RP should always be checked in PBC patients and should be an indication to perform NFC for early SSc diagnosis. A diagnostic algorithm is proposed.

Keywords Primary biliary cholangitis, systemic sclerosis, nailfold capillaroscopy

Ann Gastroenterol 2025; 38 (2): 187-194

^aDepartment of Gastroenterology and Hepatology, Università Politecnica delle Marche, Ancona, Italy (Daniele Crescenzi, Daniele Balducci, Marta Mazzetti, Giuseppe Tarantino, Antonio Benedetti, Marco Marzioni, Luca Maroni); ^bDepartment of Internal Medicine, Università Politecnica delle Marche, Ancona, Italy (Denise Menghini, Chiara Gelardi, Veronica Pedini, Cristina Mezzanotte, Maria Giovanna Danieli)

*These authors contributed equally to the manuscript

Conflict of Interest: None

Correspondence to: Luca Maroni, Department of Gastroenterology and Hepatology, Università Politecnica delle Marche, Nuovo Polo Didattico, III piano, Via Tronto 10, 60126 Ancona, Italy, e-mail: l.maroni@univpm.it

Received 9 September 2024; accepted 14 December 2024; published online 26 February 2025

DOI: <https://doi.org/10.20524/aog.2025.0949>

This is an open access journal, and articles are distributed under the terms of the Creative Commons Attribution-NonCommercial-ShareAlike 4.0 License, which allows others to remix, tweak, and build upon the work non-commercially, as long as appropriate credit is given and the new creations are licensed under the identical terms

Introduction

Primary biliary cholangitis (PBC) is a chronic autoimmune cholestatic liver disease characterized by the destruction of small and medium size bile ducts. Persistent cholestasis results in elevated alkaline phosphatase serum levels, while anti-mitochondrial antibodies (AMA) serve as a distinctive marker of disease. The clinical course is variable, with potential progression to cirrhosis and liver failure if the disease is not adequately managed [1].

Notably, a significant proportion of PBC patients (approximately 53%) also present with other autoimmune diseases [2]. Among these, systemic sclerosis (SSc) is frequently associated, with 1-22% of PBC patients receiving a concurrent SSc diagnosis, depending on the criteria used for the diagnosis [3]. However, the literature on this overlap syndrome is sparse, primarily consisting of case reports and limited case series.

SSc is characterized by sclerosis affecting the skin, mucosa and muscles, with variable involvement of internal organs, such as gastrointestinal tract, lungs, kidneys and heart. The

pathophysiological mechanisms of SSc are small-vessel vasculopathy, autoantibody production, fibroblast dysfunction and excessive extracellular matrix deposition [4]. Severe SSc with extensive organ involvement can preclude liver transplantation (LT) eligibility in PBC patients.

In clinical practice, symptoms and signs of SSc in PBC patients are often under-recognized or inadequately investigated, particularly by gastroenterologists, because of the predominance of subclinical forms. Moreover, rheumatologic manifestations may be confused with PBC's extra-hepatic symptoms, complicating the diagnosis. While some researchers have proposed screening algorithms for SSc in PBC patients, formal guidelines remain unestablished. Nailfold capillaroscopy (NFC) is pivotal for early SSc diagnosis, as well as for assessing disease activity and therapeutic response [5]. This observational cross-sectional study aimed to evaluate the effectiveness of systematic clinical assessments and NFC in the early diagnosis of SSc in PBC patients.

Patients and methods

Patients

This study involved 56 consecutive patients from our "Autoimmune Liver Diseases" outpatient clinic, recruited between December 2018 and March 2019. Informed consent was obtained from each participant. The study was conducted in accordance with the Declaration of Helsinki and was approved by the local ethics committee.

The inclusion criteria were: a diagnosis of PBC (with or without autoimmune hepatitis features), age over 18 years, and the ability to undergo baseline clinical and instrumental evaluation. The PBC diagnosis adhered to the criteria set by the European Association for the Study of the Liver (EASL) and the American Association for the Study of Liver Diseases (AASLD) [1]. Diagnosis was based on one of the following clinical scenarios: 1) persistent cholestasis and presence of AMA (titer >1:40) in a patient without systemic diseases; 2) persistent cholestasis and positivity to PBC-specific antinuclear antibodies by immunofluorescence (nuclear dots and perinuclear rim patterns), or immunoenzymatic test (sp100 and gp210), in a patient without AMA; and 3) evidence of non-suppurative obstructive cholangitis on histology [1].

Exclusion criteria comprised a prior SSc diagnosis, inability to provide informed consent, refusal of NFC, and incapacity to attend hospital assessments.

Study design

This was an observational cross-sectional study. Medical history investigation and physical examination were performed in all patients, with special attention to the evaluation of SSc-related signs and symptoms. All patients underwent complete NFC. Those showing major abnormalities or a scleroderma

pattern were advised to screen for autoantibodies within 2 months for data collection purposes.

Patients meeting the VEDOSS criteria (Very Early Diagnosis Of Systemic Sclerosis) [6] or 2013 ACR/EULAR criteria (American College of Rheumatology/European League Against Rheumatism) [7] were classified and diagnosed with SSc and referred to a rheumatology center.

This study was reported according to the STROBE (Strengthening the Reporting of Observational studies in Epidemiology) guideline.

Clinical evaluation

Medical history was obtained, and physical examination was performed in order to look for puffy fingers, pitting scars, digital ulcers, macroscopic telangiectasias, calcinosis, sclerodactyly, skin atrophy, microstomia, microcheilia, and signs of arthritis. The presence of Raynaud's phenomenon (RP) was assessed in each patient. RP was considered as a history of biphasic or triphasic color change (white, blue, red) of at least one finger of each hand, induced by cold exposure [8].

NFC

NFC was performed by skilled rheumatologists, according to a standard protocol. The examination was performed using a Wild Heerbrugg M5A stereomicroscope with a Volpi Intralux 6000 optical fiber light source. Prior to NFC, all patients waited for at least 15 min in a room at a temperature of about 20°C. A drop of cedar oil was applied to the nailfolds. All fingers, except for thumbs, were examined with the stereomicroscope.

During NFC, morphologic and functional parameters were also investigated in all patients. Morphologic parameters included skin transparency, visibility of the sub-papillary venous plexus, alignment, spatial distribution, density, length and diameter of capillaries. Blood flow, a functional parameter, was evaluated as continuous, granular or intermittent [9].

The NFC examination was performed in order to detect the following pathological features of the microcirculation: tortuosity, ectasia, microhemorrhages, microthrombi, neoangiogenesis, reduction in capillary density, avascular areas, and architecture disturbance of capillaries [9].

NFC findings were analyzed based on a qualitative system, to identify known pathological patterns. Based on the NFC findings, patients were classified into 4 categories: 1) patients with no NFC abnormalities; 2) patients with minor NFC abnormalities; 3) patients with major NFC abnormalities; and 4) patients with defined scleroderma pattern. These categories were defined according to an internal protocol, used in clinical practice, that was developed based on the current literature data. Minor NFC abnormalities included tortuous capillaries and apical ectasia in less than 6 fingers [9]. Major NFC abnormalities included tortuous capillaries and apical ectasia in more than 6 fingers [9].

Table 1 2013 ACR/EULAR criteria

Item	Sub-items	Weight/score
Skin thickening of the fingers of both hands extending proximal to the metacarpophalangeal joints (<i>sufficient criterion</i>)		9
Skin thickening of the fingers (higher score)	- Puffy fingers	2
	- Sclerodactyly of the fingers (distal to metacarpophalangeal joints but proximal to the proximal interphalangeal joints)	4
Fingertip lesions (higher score)	- Digital tip ulcers	2
	- Fingertip pitting scars	3
Teleangiectasia		2
Abnormal nailfold capillaries		2
Pulmonary arterial hypertension and/or interstitial lung disease (<i>maximum score is 2</i>)	- Pulmonary arterial hypertension	2
	- Interstitial lung disease	2
Raynaud's phenomenon		3
SSc-related autoantibodies (any of anti-centromere, anti-topoisomerase I [anti-Scl-70], anti-RNA polymerase III)		3

The total score is determined by summing the maximum weights/scores in each category. Patients with a total score ≥ 9 are classified as having definite scleroderma

Scleroderma pattern was defined by the variable presence of the following capillaroscopic features: tortuous capillaries and apical ectasia (of any entity), homogeneous ectasia, enlarged capillaries, mega capillaries, microhemorrhages, decrease in capillary density, avascular areas, neoangiogenesis. By combining these findings, the scleroderma pattern can be classified as early, active or late. These patterns are usually related with clinical features and prognosis [9].

Autoantibodies detection

Patients with NFC major abnormalities and those with scleroderma pattern were recommended to screen for SSc-related autoantibodies, including anti-centromere (ACA), anti-topoisomerase I (anti-Scl-70), antinuclear antibodies (ANA), and anti-extractable nuclear antigens (anti-ENA).

ACA and anti-Scl-70 are SSc-related antibodies included in the 2013 ACR/EULAR criteria [7] (see below). ANA are considered as "red flags" in the VEDOSS criteria [6] (see below).

Anti-ENA screening was performed to identify eventually coexisting connective tissue diseases. The anti-ENA screening panel included antibodies against the following antigens: DNA, RNP, Sm, SS-A/Ro, SS-B/La, Scl-70, CENP, Jo-1, histone, mitochondria. Tests were performed according to the manufacturer's instructions.

Classification and diagnostic criteria for SSc

The 2013 ACR/EULAR criteria [7] and VEDOSS criteria [6] were used for the classification and diagnosis of SSc. The 2013 ACR/EULAR criteria are a classification currently used in

clinical practice; the patients can be classified as having definite SSc. The VEDOSS criteria are diagnostic criteria used for the diagnosis of very early SSc.

According to the 2013 ACR/EULAR criteria, patients with a total score ≥ 9 are classified as having definite SSc (Table 1). The total score is calculated by summing the weighted values assigned to each of these features: skin thickening of the fingers, fingertip lesions, telangiectasia, abnormal nailfold capillaries at NFC, pulmonary involvement, Raynaud's phenomenon, SSc-related autoantibodies. Skin thickening of the fingers of both hands, extending proximal to the metacarpophalangeal joints, is a sufficient criterion to classify the patient as having definite SSc [7].

According to the VEDOSS criteria, Raynaud's phenomenon, puffy fingers and detection of ANA are considered as red flags. Coexistence of these clinical features must be considered suspicious for very early SSc. Diagnosis of very early SSc can be made in patients presenting a scleroderma pattern on NFC and/or SSc-related antibodies (ACA, anti-Scl-70, anti-RNA polymerase III) in addition to the abovementioned red flags [6].

Follow up

Follow-up clinical data were retrospectively retrieved from patients' clinical files where available.

Statistical analysis

Statistical analyses were performed using StataCorp. 2019 (*Stata Statistical Software: Release 16*. College Station, TX: StataCorp LLC). Continuous variables are expressed as means

with ranges, or medians with interquartile ranges. Categorical variables are expressed as numbers with percentages.

Results

Study population characteristics

During the study period 145 patients were screened for eligibility. Three were excluded because of a previous SSc diagnosis, 52 refused the NFC, and 34 refused to sign the informed consent. Finally, a total of 56 patients who met the inclusion criteria were analyzed (Fig. 1). Characteristics of the study population are summarized in Table 2: 48 (86%) were females and 8 were males, and the mean age was 62 years (range 37-84), with a median of 63 years. Mean time from diagnosis of PBC was 9 years (range 6 months to 50 years). Twelve patients had overlap of PBC with autoimmune hepatitis.

In terms of disease staging, 10 patients had hepatic cirrhosis due to PBC. Overall, 47 (84%) patients underwent liver stiffness measurement (FibroScan) and 21 (45%) had a liver stiffness value >9.6 KPa, suggestive of a high risk of liver decompensation, liver transplantation or death [10].

Regarding treatment, 53 (95%) patients were taking ursodeoxycholic acid (UDCA) and 6 (11%) were taking obeticholic acid (OCA). Of the UDCA-treated patients, 38 (72%) showed a complete biochemical response, while 3 (50%) of those on OCA normalized their liver tests. Response to therapy was defined according to EASL guidelines [1]. Concerning other medications, 9 (16%) patients were taking bezafibrate and 7 (12%) patients needed symptomatic therapy for pruritus. Three (5%) patients had

undergone liver transplantation. Laboratory findings are detailed in Table 2.

Raynaud's phenomenon was detected in 12 (21%) patients. None showed definite signs of SSc (skin sclerosis, pitting scars, digital ulcers, skin atrophy, microstomia, microcheilia), except for 1 patient who presented skin thickening of the fingers. Acrocyanosis was reported in 2 (4%) patients.

As outlined in Table 2, overall, auto-Ab screening revealed the following positivities: anti-ENA screening in 1 patient, anti-SSa/Ro in 4, anti-PML in 1 and anti-U1RNP in 1.

Regarding ANA, all patients were already tested at baseline of the hepatologic assessment and 27 (48%) were positive.

Results of NFC

As shown in Table 2, NFC abnormalities were found in 31 (55%) patients overall: 11 (20%) presented NFC minor abnormalities, 17 (30%) showed major abnormalities and 3 (5%) presented a scleroderma pattern (Fig. 2).

Based on the NFC results, 20 (36%) patients were referred to undergo SSc-related autoantibody screening. All the patients with NFC abnormalities were also advised to undergo follow-up capillaroscopy.

The mean age of patients with scleroderma pattern was 55 years; the mean ages of patients with negative NFC, minor abnormalities and major abnormalities were 62, 61.9 and 61.8 years, respectively.

All PBC patients with scleroderma pattern had associated autoimmune diseases among those defined by EASL guidelines (e.g., Hashimoto's thyroiditis, Sjögren disease or sicca complex, celiac disease, inflammatory bowel disease) [1]. These

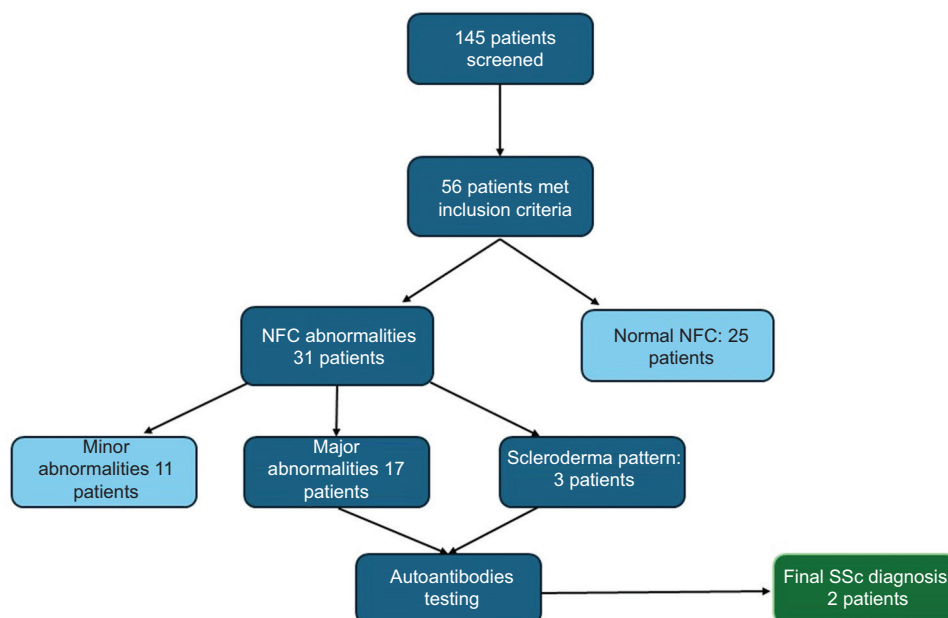


Figure 1 Flowchart showing patient screening and outcomes
NFC, nailfold capillaroscopy; SSc, systemic sclerosis

Table 2 Features of study population

Study population: clinical data	Total = 56
Female/male, n (%)	
Females	48 (85.7%)
Males	8 (14.3%)
Age (years), mean (range)	62 (37-84)
Time since diagnosis, mean (range), years	9 (0.5-50)
AIH/PBC, n (%)	12 (21.4%)
Cirrhosis, n (%)	10 (17.8%)
Liver stiffness value >9.6 KPa, n (%)	21 (45%)
Liver transplantation, n (%)	3 (5.3%)
Therapy with UDCA, n (%)	53 (95%)
Response to UDCA, n (%)	38 (72%)
Therapy with OCA, n (%)	6 (11%)
Response to OCA, n (%)	3 (50%)
Therapy with bezafibrate, n (%)	9 (16%)
Therapy for pruritus, n (%)	7 (12%)
Study population: laboratory data	
ALP (x u.n.l.)	1.08 (0.39-4.08)*
gGT (x u.n.l.)	2.13 (0.26-11.92)*
ALT (x u.n.l.)	0.85 (0.12-2.74)*
AST (x u.n.l.)	0.85 (0.27-2.45)*
Total bilirubin (mg/dL)	0.74 (0.20-2.11)*
Results of autoantibody detection	
Anti-ENA screening, n	1
Anti-SSA-Ro, n	4
Anti-PML, n	1
Anti-U1RNP, n	1
Results of nailfold capillaroscopy	
No abnormalities, n (%)	25 (45%)
Minor abnormalities, n (%)	11 (20%)
Major abnormalities, n (%)	17 (30%)
Scleroderma pattern, n (%)	3 (5%)

AIH/PBC, autoimmune hepatitis/primary biliary cholangitis; UDCA, ursodeoxycholic acid; OCA, obeticholic acid; *average value (range); ALP, alkaline phosphatase; gGT, gamma-glutamyl transferase; ALT, alanine aminotransferase; AST, aspartate aminotransferase; u.n.l., upper normal limit

diseases were reported in 48%, 45% and 47% of patients with negative NFC, minor abnormalities and major abnormalities, respectively.

ANA positivity was observed in all patients with scleroderma pattern, and in 40%, 55% and 47% of patients with negative NFC, minor abnormalities and major abnormalities, respectively.

No relevant differences were found in biochemistry laboratory values among the categories of patients mentioned above.

SSc diagnoses

Two patients (3.5%) met the criteria for SSc classification/diagnosis. One was diagnosed with very early SSc according

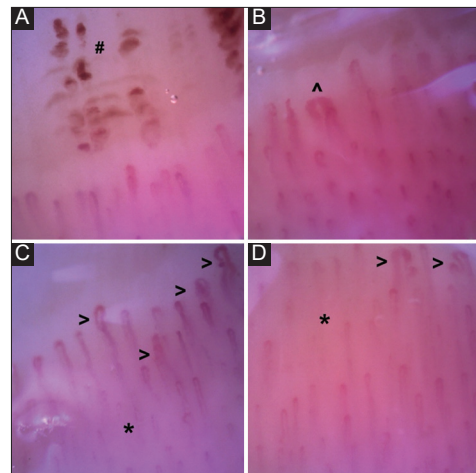


Figure 2 Scleroderma pattern: (A) microhemorrhages (#); (B) megacapillary (^); (C) and (D) capillary ectasia (>) and reduction in capillary density (*). The figure shows some of the typical capillaroscopic findings of scleroderma pattern: microhemorrhages, megacapillary, capillary ectasia and reduction in capillary density. This patient was diagnosed with an “early” scleroderma pattern. These pictures were taken using a digital video capillaroscope

to the VEDOSS criteria, presenting with RP, puffy fingers, ANA positivity and a scleroderma pattern in NFC. The second patient, exhibiting RP, sclerodactyly and a scleroderma pattern in NFC, was classified as having definite SSc according to the 2013 ACR/EULAR criteria.

Follow-up results

Follow-up capillaroscopy data were available at 12 months only for patients displaying capillaroscopic abnormalities (minor and major abnormalities, scleroderma pattern) at baseline (31 patients), without major changes from baseline. Two patients who met the criteria for SSc diagnosis received a confirmation of the diagnosis and were taken in charge by the rheumatology unit. No new diagnosis of SSc were made in all the cohort during a median clinical follow up of 36 months (33.75-36).

Discussion

Our study integrated clinical examination, medical history, NFC and SSc-related autoantibody assessment in PBC patients, leading to the identification of 2 new SSc diagnoses. Our analysis showed a substantial prevalence of NFC abnormalities in patients with PBC, with a subsequent diagnosis of SSc in 2 patients. Based on our results, we pointed out crucial elements for SSc screening in PBC patients, proposing a diagnostic algorithm.

SSc is classified into *diffuse cutaneous SSc* (dcSSc) and *limited cutaneous SSc* (lcSSc). The distinction is based on

skin sclerosis extension: the diffuse type is characterized by generalized skin sclerosis, the limited type is characterized by the sclerosis of the face and extremities of the limbs. Limited cutaneous SSc is the most common in PBC patients [11].

Pathophysiological features of SSc include small-vessel vasculopathy, autoantibody production and dysfunction of fibroblasts, leading to excessive extracellular matrix deposition. Clinical manifestations are heterogeneous; multiple organs and systems can be affected, including skin, gastrointestinal tract, lungs, kidneys and heart [7]. Systemic involvement often occurs early in the course of the disease and usually precedes symptom onset [6].

Multiorgan involvement of SSc may contraindicate LT in PBC patients with end-stage liver disease. All potential LT candidates should undergo a multidisciplinary evaluation before their inclusion on the transplant list. Cardiovascular, respiratory and renal function strongly impact the final decision about the reliability of LT [12]; therefore, patients with PBC and late-stage SSc could be excluded from the waiting list. Pulmonary arterial hypertension particularly increases the mortality after LT [12].

In PBC patients, SSc coexistence could alter the disease course, impacting transplant eligibility and prognosis. However, the literature on the influence of SSc on PBC prognosis is mixed, with some studies suggesting a better prognosis, while others report greater mortality due to SSc complications [13]. A higher incidence of a first episode of spontaneous bacterial peritonitis and septicemia was reported in patients with PBC and SSc, compared to PBC patients without SSc; an increased risk of infection due to immune abnormalities may explain this issue [13].

No disease-modifying drugs for SSc are currently available; however, early screening and organ-specific management appear to reduce disease progression and mortality. Proper investigation strategies should be adopted for the early identification of deterioration in pulmonary, gastrointestinal, renal and cardiac function. Current treatments include symptomatic therapies, immunosuppression, steroids and biological drugs. Targeted therapies are available for pulmonary arterial hypertension [14]. Patients may need hepatotoxic drugs to treat SSc complications (e.g., bosentan and methotrexate); thus, hepatic function should be carefully monitored.

Hudson *et al* studied 408 patients with SSc and pointed out that the mean time from the onset of RP to SSc diagnosis was 5 ± 6.3 years, while the time from non-Raynaud's symptoms to SSc diagnosis was 2.6 ± 4.5 years [15]. SSc is an uncommon disease for most physicians: diagnosis and treatment are often challenging, in particular for patients who are not sent to referral centers [14].

The prevalence of SSc in PBC patients is quite substantial [16]; thus, a special diagnostic algorithm should be planned and used by gastroenterologist whenever needed. Diagnosis of SSc should be made by investigating early SSc signs before the patient complains about advanced symptoms of the disease.

Rigamonti *et al* [13] proposed an algorithm for SSc screening and diagnosis in PBC patients, focusing on the

use of SSc-associated antibodies and NFC. However, official guidelines and indications for the diagnosis in PBC patients are lacking, and SSc identification is often delayed.

To our knowledge, this is the first study to investigate the prevalence of SSc in patients with PBC using 2013 ACR/EULAR and VEDOSS criteria to detect very early SSc, and the usefulness of NFC as a screening tool in this specific population.

RP was detected in 21.4% of our PBC patients; 12.5% of these were diagnosed with SSc. None of the patients without RP was diagnosed with SSc. This phenomenon is very common in patients with PBC, and it is a manifestation of SSc in a significant percentage of cases. SSc without RP is quite rare [17]. Based on this evidence, the indication to perform NFC can be properly given in all patients presenting RP at first evaluation and at any time during the clinical follow up.

Performing NFC at first is a useful approach, because it allows the patient to meet a rheumatologist who could properly evaluate all symptoms and signs. Moreover, SSc-related auto-antibody screening can be prescribed based on NFC results; thus, unnecessary extensive tests could be avoided.

Our study found NFC abnormalities in 55% of PBC patients, aligning with the literature on its prevalence in PBC populations and suggesting a role for endothelial dysfunction in PBC [18]. However, these findings must be interpreted cautiously, given the high prevalence of capillaroscopic abnormalities in healthy individuals. Hoerth *et al* [19] reported morphological changes in nailfold capillaries in 67% of healthy volunteers. Fahrig *et al* found morphological anomalies in 34% of the healthy population studied [20]. In another study, Fahrig *et al* reported capillary branching in 78% of the healthy subjects investigated, meandering in 94%, tortuous loops in 64%, hemorrhagic extravasation in 25% and apical dilatation in 19% [21]. Despite the similar prevalence of capillaroscopic abnormalities, the same findings should be considered carefully in people with PBC, given the high incidence of SSc in these patients. Proper follow up and further investigations, when needed, should be recommended when capillaroscopic abnormalities are found in patients diagnosed with PBC.

Our data did not reveal a specific capillaroscopic pattern for SSc in PBC patients. The high prevalence of capillaroscopic abnormalities in the healthy population makes it harder to find typical features in patients with PBC. At present, data on this issue are lacking; therefore, further studies involving a large number of patients are needed to better define the existence of a specific capillaroscopic pattern for PBC.

In our study, a scleroderma pattern on NFC was reported in 3 patients and was associated with SSc in 2 cases (66%). The third patient with scleroderma pattern did not fulfil the diagnostic criteria for SSc, and therefore a longitudinal observation was recommended. "Incomplete overlap" between PBC and SSc is also possible, and may represent an evolutive stage toward definite SSc [22].

Little is known about the clinical significance of isolated SSc features, such as capillaroscopic pathological patterns in

patients affected by PBC without SSc symptoms and signs. Both PBC and SSc are characterized by elevated levels of the profibrotic cytokines transforming growth factor- β and interleukin-6, resulting in dysregulation of inflammatory processes and fibrotic tissue deposition [11]. The vessel impairment may explain the presence of isolated SSc signs in patients with PBC [18].

In our study, all the patients with a scleroderma pattern on NFC shared common features: they were female, they had an associated autoimmune disease and they had a positive ANA test. All these aspects are strongly consistent with the autoimmune nature of PBC and SSc [2].

Adding the number of newly diagnosed patients to the number of those already diagnosed with SSc (excluded from the study), the SSc prevalence among PBC patients in our center is about 11.5%. This value is consistent with literature data (5-12%) [23]. Thanks to our study, the number of SSc diagnoses in our center increased by 40%.

Based on our findings, we propose a diagnostic algorithm for SSc in PBC patients as follows (Fig. 3). RP should always be checked at baseline assessment in the PBC patient. If present, the patient should undergo NFC; otherwise, the patient should be regularly checked over the years by the gastroenterologist for *ex novo* occurrence of RP. If a scleroderma pattern is detected on NFC, the patient should undergo screening for SSc-related autoantibodies (ACA, anti-Scl-70, ANA and anti-ENA). In patients without a scleroderma pattern, SSc-related antibody screening and/or capillaroscopic follow up, or no other intervention, should be scheduled, according to the entity of abnormalities found on NFC. Patients with scleroderma pattern and/or with SSc-related autoantibodies

should be assessed for fulfilment of the 2013 ACR-EULAR criteria [7] or VEDOSS criteria [6]. Patients diagnosed with SSc, according to these criteria, should be referred to a rheumatologist. The same diagnostic pathway should be clearly followed by patients with symptoms and signs of SSc at baseline assessment, even though they may have a later stage of the disease.

Several limitations of the present study must be acknowledged. First, as it was a cross-sectional study, patients were evaluated at a single point in time, without a specific follow up, except for capillaroscopy at 12 months from baseline. This design limits the ability to identify false negatives (patients who might develop SSc later) or observe disease progression. Without follow up, it is impossible to definitively assess whether patients classified as negative for SSc might develop the disease in the future; thus, the accuracy of the diagnostic algorithm could not be estimated. Second, 52 patients refused NFC, and 3 refused to sign informed consent, which could have introduced selection bias. The patients who agreed to participate may differ from those who declined in ways that are relevant to the study outcomes. Third, a larger sample would provide more robust conclusions.

In conclusion, NFC can help anticipate the SSc diagnosis in PBC patients, leading to the possibility of early treatment and prevention of major complications. Gastroenterologists should vigilantly monitor for clinical signs, particularly RP, and employ NFC as needed. Our proposed algorithm, focusing on early detection and appropriate follow up, could significantly impact patient outcomes by facilitating timely SSc diagnosis and management.

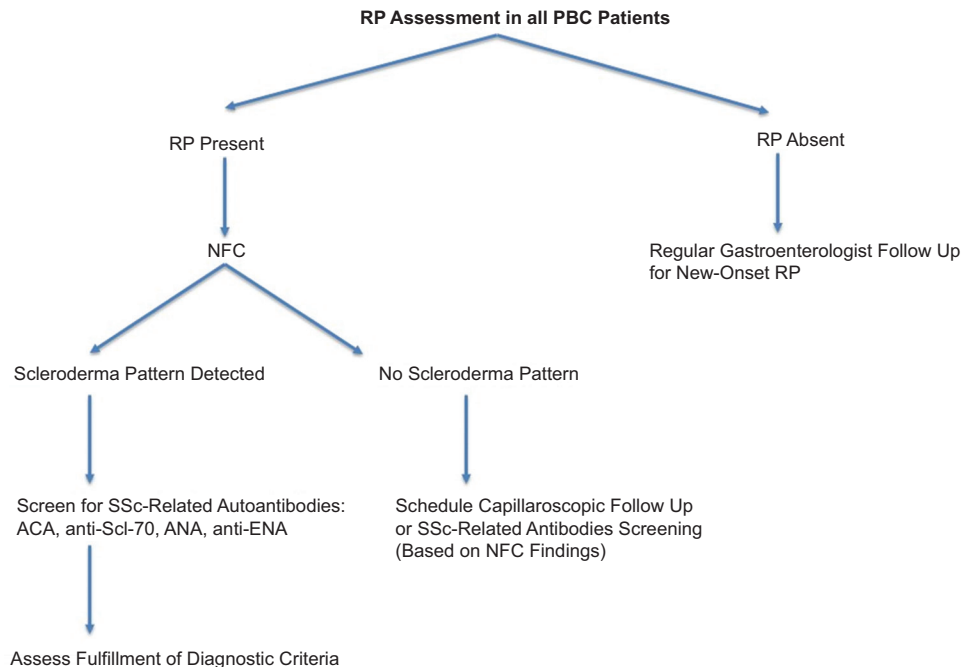


Figure 3 Diagnostic algorithm
 NFC, nailfold capillaroscopy; PBC, primary biliary cholangitis; RP, Raynaud’s phenomenon; SSc, systemic sclerosis; ACA, anti-centromere antibodies; anti-Scl-70, antitopoisomerase I; ANA, antinuclear antibodies; ENA, extractable nuclear antigens

Summary Box

What is already known:

- Primary biliary cholangitis (PBC) is an autoimmune liver disease, and about 1-22% of PBC patients may also develop systemic sclerosis (SSc), a progressive autoimmune condition
- SSc can be challenging to diagnose early, especially in patients with subclinical forms, leading to delays in treatment
- Nailfold capillaroscopy (NFC) is a noninvasive tool that is commonly used to detect microvascular abnormalities and diagnose SSc, but its specific role in PBC patients has been under-explored
- Raynaud's phenomenon (RP) is frequently associated with SSc and can be an early symptom, but its diagnostic significance in PBC patients requires further study

What the new findings are:

- The study suggests that using NFC in PBC patients, particularly those with RP, may help identify early signs of SSc, thus facilitating earlier diagnosis and management
- Two new cases of SSc were diagnosed using the proposed diagnostic algorithm based on NFC findings and the presence of RP
- NFC abnormalities, particularly the scleroderma pattern, were observed in 5% of PBC patients, reinforcing the potential of NFC as a screening tool for SSc in this population
- The study proposes a diagnostic algorithm for early detection of SSc in PBC patients, focusing on systematic use of NFC and antibody screening in the presence of RP and NFC abnormalities

References

- Hirschfield GM, Beuers U, Corpechot C, et al; European Association for the Study of the Liver. EASL Clinical Practice Guidelines: The diagnosis and management of patients with primary biliary cholangitis. *J Hepatol* 2017;**67**:145-172.
- Watt FE, James OF, Jones DE. Patterns of autoimmunity in primary biliary cirrhosis patients and their families: a population-based cohort study. *QJM* 2004;**97**:397-406.
- Zheng B, Vincent C, Fritsler MJ, Senécal JL, Koenig M, Joyal F. Prevalence of systemic sclerosis in primary biliary cholangitis using the new ACR/EULAR classification criteria. *J Rheumatol* 2017;**44**:33-39.
- Asano Y. The pathogenesis of systemic sclerosis: an understanding based on a common pathologic cascade across multiple organs and additional organ-specific pathologies. *J Clin Med* 2020;**9**:2687.
- Lambova SN, Müller-Ladner U. Nailfold capillaroscopy in systemic sclerosis – state of the art: the evolving knowledge about capillaroscopic abnormalities in systemic sclerosis. *J Scleroderma Relat Disord* 2019;**4**:200-211.
- Minier T, Guiducci S, Bellando-Randone S, et al; EUSTAR co-workers. Preliminary analysis of the very early diagnosis of systemic sclerosis (VEDOSS) EUSTAR multicentre study: evidence for puffy fingers as a pivotal sign for suspicion of systemic sclerosis. *Ann Rheum Dis* 2014;**73**:2087-2093.
- van den Hoogen F, Khanna D, Fransen J, et al. 2013 classification criteria for systemic sclerosis: an American College of Rheumatology/European League against Rheumatism collaborative initiative. *Arthritis Rheum* 2013;**65**:2737-2747.
- Wigley FM. Clinical practice. Raynaud's phenomenon. *N Engl J Med* 2002;**347**:1001-1008.
- Etehad Tavakol M, Fatemi A, Karbalaie A, Emrani Z, Erlandsson BE. Nailfold Capillaroscopy in Rheumatic Diseases: Which Parameters Should Be Evaluated? *Biomed Res Int* 2015;**2015**:974530.
- Corpechot C, Carrat F, Poujol-Robert A, et al. Noninvasive elastography-based assessment of liver fibrosis progression and prognosis in primary biliary cirrhosis. *Hepatology* 2012;**56**:198-208.
- Ohira H, Watanabe H. Pathophysiology and recent findings of primary biliary cirrhosis complicated by systemic sclerosis. *Hepatol Res* 2014;**44**:377-383.
- European Association for the Study of the Liver. EASL Clinical Practice Guidelines on liver transplantation. *J Hepatol* 2024;**81**:1040-1086.
- Rigamonti C, Bogdanos DP, Mytilinaiou MG, Smyk DS, Rigopoulou EI, Burroughs AK. Primary biliary cirrhosis associated with systemic sclerosis: Diagnostic and clinical challenges. *Int J Rheumatol* 2011;2011.
- Denton CP, Khanna D. Systemic sclerosis. *Lancet* 2017;**390**:1685-1699.
- Hudson M, Thombs B, Baron M; Canadian Scleroderma Research Group. Time to diagnosis in systemic sclerosis: is sex a factor?. *Arthritis Rheum*. 2009;**61**:274-278.
- Wang L, Zhang FC, Chen H, et al. Connective tissue diseases in primary biliary cirrhosis: a population-based cohort study. *World J Gastroenterol* 2013;**19**:5131-5137.
- Marasini B, Gagetta M, Rossi V, Ferrari P. Rheumatic disorders and primary biliary cirrhosis: an appraisal of 170 Italian patients. *Ann Rheum Dis* 2001;**60**:1046-1049.
- Marasini B, Pipia C, DeValle G, et al. Vascular impairment in patients with primary biliary cirrhosis. *Int J Microcirc Clin Exp* 1995;**15**:75-79.
- Hoerth C, Kundi M, Katzenschlager R, Hirschl M. Qualitative and quantitative assessment of nailfold capillaries by capillaroscopy in healthy volunteers. *Vasa* 2012;**41**:19-26.
- Andrade LE, Gabriel Júnior A, Assad RL, Ferrari AJ, Atra E. Panoramic nailfold capillaroscopy: a new reading method and normal range. *Semin Arthritis Rheum* 1990;**20**:21-31.
- Fahrig C, Heidrich H, Voigt B, Wnuk G. Capillary microscopy of the nailfold in healthy subjects. *Int J Microcirc Clin Exp* 1995;**15**:287-292.
- Tovoli F, Granito A, Giampaolo L, et al. Nailfold capillaroscopy in primary biliary cirrhosis: a useful tool for the early diagnosis of scleroderma. *J Gastrointest Liver Dis* 2014;**23**:39-43.
- Assassi S, Fritsler MJ, Arnett FC, et al. Primary biliary cirrhosis (PBC), PBC autoantibodies, and hepatic parameter abnormalities in a large population of systemic sclerosis patients. *J Rheumatol* 2009;**36**:2250-2256.