

Case Report

Synchronous occurrence of colorectal adenocarcinoma and colonic gastrointestinal stromal tumor (GIST). A case report

D. Dimitroulopoulos¹, Aik. Fotopoulou², D. Xinopoulos¹, N. Arnogiannaki³, D. Korkolis,⁴
K. Tsamakidis¹, D. Kypreos¹, S. Bassioukas¹, S. Patsavela¹, E. Paraskevas¹

SUMMARY

The synchronous occurrence of GIST and other primary gastrointestinal malignancies has been rarely reported. We report the case of an 84 year-old female who presented with a rectal blood loss. Total colonoscopy revealed a stenotic lesion at sigmoid colon covered by endoscopically healthy mucosa and also a massive polypoid cecal mass. The patient underwent left subtotal colectomy and ileorectal J-pouch anastomoses without diverting stoma. Histologically the sigmoid tumor met the GIST criteria and the cecal mass was a well differentiated adenocarcinoma. To our knowledge this synchronous occurrence is reported for first time in the literature.

Keywords: GIST; colon adenocarcinoma; synchronous; colon; imatinib

cases per million and an estimated 5-year survival rate of 45-65%, GIST's typically present in older individuals and are most common in the stomach (60%), followed by small intestine (15%), colon and rectum (5%), esophagus, mesentery and omentum^{5,6}.

The synchronous occurrence of GIST and other primary gastrointestinal malignancies has been rarely reported. In these cases stomach and small intestine were the most common locations for the GIST.⁷⁻¹¹

In the present case report we describe a 84 year-old woman with GIST of sigmoid colon and synchronous invasive adenocarcinoma at the ileocecal valve. To our knowledge, this synchronous occurrence has not been reported in the literature.

INTRODUCTION

Gastrointestinal stromal tumors (GIST's) have only recently become recognized as a distinct pathologic entity. The term was first used in 1983 by Mazur and Clark to encompass gastrointestinal and mesenteric non-epithelial neoplasms that lacked the immunohistochemical features of Schwann cells and did not have the ultrastructural characteristics of smooth muscle cells.¹ The vast majority of GIST's are positive for CD117 and vimentin in immunohistochemical staining.²⁻⁴

Their epidemiology still remain incompletely known. With an annual incidence ranging between 6.8 and 14.5

¹Gastroenterology Dept, "Agios Savvas" Cancer Hospital,
²Radiation-Oncology Dept, "Ygeia" Hospital, ³Pathology Dept,
"Agios Savvas" Cancer Hospital, ⁴1st Surgical Dept, "Agios Savvas" Cancer Hospital

Author for correspondence:

D.Dimitroulopoulos, 35 Parnassou str., 152 34 Halandri-Athens, Greece, Tel. 0030-210-6892460, E-mail: dimdim@otenet.gr

CASE REPORT

A 84 year-old Caucasian female, with a recently diagnosed GIST, located in the colon, was admitted to the Gastroenterology department of "Agios Savvas" Cancer Hospital, Athens, Greece, in February 2007. A lower gastrointestinal tract endoscopic examination, performed a month before due to rectal blood loss, was stopped in the sigmoid colon area because of a great stenosis. Tissue specimens obtained endoscopically from the stenosis were stained positive for CD117, CD34 and vimentin.

The patient's past medical history included hypertension, atrial fibrillation and Alzheimer disease. No history of malignancy was noted in her family history. Physical and rectal digital examination were undiagnostic.

Complete blood count, urine tests, standard biochemical studies and also serum levels of tumor markers including CEA, CA 19-9, AFP, CA125 and CA 15-3 were within normal ranges.

Chest X-ray and upper abdominal ultrasonography

were normal. Abdominal computed tomography showed wall thickening of ascending colon and cecum in a length of more than 7 cm.

Total colonoscopy revealed the already known stenosis at sigmoid colon, covered by endoscopically normal mucosa and also a massive polypoid mass (diameter almost 5cm) in ascending colon, close to the ileocecal valve.

Multiple biopsies were obtained with conventional biopsy forceps from the cecal lesion. Histology revealed mild/moderate dysplastic alterations from a mixed type (hyperplastic-adenomatous) colonic polyp.

The patient underwent left subtotal colectomy and ileorectal J-pouch anastomosis without diverting stoma 10 days after.

PATHOLOGY REPORT

Pathology department was examined three surgical specimens. The first one (total length 60 cm), consisted of a 7 cm length portion of small intestine adjoining by the ileocecal valve, the cecum and a portion of large intestine. Grossly, was observed a 5x5 cm cecal papillary mass close to the ileocecal valve with intracanalicular growth. Histology revealed a well differentiated adenocarcinoma limited to the muscularis propria, stage Dukes A and B1. None of the twelve examined lymph nodes presented metastatic invasion. The second (8 cm, large intestine) was without macroscopic alterations.

Gross examination of the third specimen revealed, 8 cm from the distal surgical margin, a 2,8x2,5x2 cm mass producing from the outer muscularis propria to the mucosa with a small ulceration and central cystic degeneration filled with blood. Histologically, the tumor demonstrated a mixed cell type appearance of a) epithelioid and b) uniform spindle cells (Fig. 1) which stained positive for CD 117 (KIT) (Fig. 2) and CD 34, slight positive for SMA and negative for vimentin, S-100 and desmin, with a mitotic activity <3 per 50 high power fields (HPF). None of the 12 lymph nodes recovered from the specimen showed evidence of metastatic disease. The final pathological diagnosis of this tumor was GIST of low grade malignancy with no metastatic involvement.

DISCUSSION

At present, GIST's may be defined as morphologically spindle cell, epithelioid, or occasionally pleomorphic, mesenchymal tumors, originated from interstitial cells of Cajal

or related stem cells, that usually express the KIT protein (-95%) and, that often harbour mutation of a gene that encodes for a type III receptor tyrosine kinase.¹²⁻¹⁴

Although they are the commonest gastrointestinal soft tissue tumors and can originate anywhere in the digestive tract, colon GIST's are relatively infrequent.^{8,15}

On the other hand, the synchronous occurrence of GIST's and other primary gastrointestinal malignancies has been rarely reported in the literature.^{7-11,16-22} The vast majority of these synchronous tumors are adenocarcinomas.⁹

To the best of our knowledge, the synchronous occurrence of two independent malignancies of colon, a GIST and an adenocarcinoma, has never been reported.

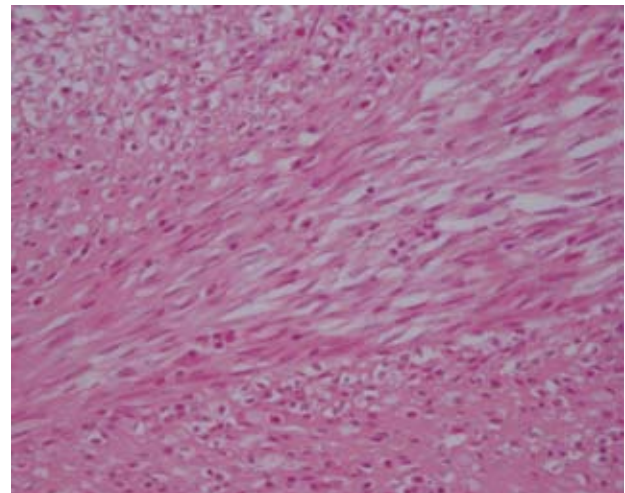


Figure 1. Spindle and epithelioid cells. H-E x 400.

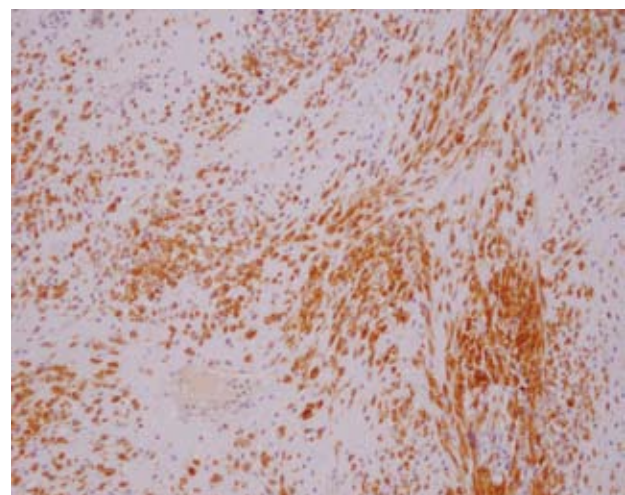


Figure 2. Spindle and epithelioid cells. CD117 positive x 100.

The most important manifestation of stromal tumors is their indolent, slow growing nature. They are generally found within the deeper stroma and the submucosa, and are often incidentally discovered during imaging studies. Symptomatic lesions have manifestation that depend on tumor size, location and growth pattern.²³⁻²⁵ Tumors less than 2 cm are generally asymptomatic while tumors with diameter more than 4 cm are associated with symptomatic disease.²⁶ Bleeding is the most common symptom at presentation and may take place either into abdominal cavity or into gastrointestinal tract lumen, as in the present case²⁷.

Localized GIST's risk assessment profile, according to the NIH consensus report of 2002, is based on the primary tumor diameter and the mitotic count. Thus, a mitotic index over 5 per 50 HPF or size more than 5 cm are considered as unfavorable prognostic factors.²⁸

Surgery is the standard of care for primary, localized, non-metastatic disease and provide 5-year survival rates ranging between 45% and 65%.^{4,29,30} Imatinib, a tyrosine kinase inhibitor, is widely used in the treatment of advanced and metastatic GIST's and has been recently employed in the neo adjuvant and adjuvant set-up with encouraging results. Another therapeutic agent, sunitinib, is approved for the treatment of imatinib-resistant tumors and a large spectrum of new small molecule inhibitors are in the pipeline eg. nilotinib, everolimus.³¹⁻³⁴

REFERENCES

- Mazur MT, Clark HB. Gastric stromal tumors: Reappraisal of histogenesis. *Am J Surg Pathol* 1983; 7: 507-519.
- Noguchi T, Sato T, Takeno S, et al. Biological analysis of gastrointestinal stromal tumors. *Oncol Rep* 2002; 9:1277-1282.
- Miettinen M, Sobin LH, Sarlomo-Rilcala M. Immunohistochemical spectrum of GIST's at different sites and their differential diagnosis with a reference to CD 117 (KIT). *Mod Pathol* 2000; 13:1134-1142.
- Blay JY, Bonvalot S, Casali P, et al. Consensus meeting for the management of gastrointestinal stromal tumors. Report of the GIST Consensus Conference of 20-21 March 2004, under the auspices of ESMO. *Ann Oncol* 2005; 16:566-578.
- Reddy P, Boci K, Charbonneau C. The epidemiologic, health-related quality of life, and economic burden of gastrointestinal stromal tumours. *J Clin Pharm Ther* 2007; 32:557-565.
- Judson I. Gastrointestinal stromal tumours (GIST): biology and treatment. *Ann Oncol* 2002; 13(Suppl 4): 287-289.
- Maiorana A, Fante R, Maria Cesinaro A, Adriana Fano R. Synchronous occurrence of epithelial and stromal tumors in the stomach: a report of 6 cases. *Arch Pathol Lab Med* 2000; 124:682-686.
- Urbanczyk K, Limon J, Korobowicz E, et al. Gastrointestinal stromal tumors. A multicenter experience. *Pol J Pathol* 2005; 56:51-61.
- Wronski M, Ziarkiewicz – Wroblewska B, Gornicka B, et al. Synchronous occurrence of gastrointestinal stromal tumors and other primary gastrointestinal neoplasms. *World J Gastroenterol* 2006; 12: 5360-5362.
- Lin Y-L, Tzeng J-E, Wei C-K, Lin C-W. Small gastrointestinal stromal tumor concomitant with early gastric cancer: A case report. *World J Gastroenterol* 2006; 12: 815-17.
- Melis M, Choi EA, Anders R, Christiansen P, Fichera A. Synchronous colorectal adenocarcinoma and gastrointestinal stromal tumor (GIST). *Int J Colorectal Dis* 2007;22:109-114.
- Kindblom LG, Remotti HE, Aldenborg F, Meis-Kindblom JM. Gastrointestinal pacemaker cell tumor (GIPACT): gastrointestinal stromal tumors show phenotypic characteristics of the interstitial cells of Cajal. *Am J Pathol* 1998; 152:1259-1269.
- Sarlomo-Rikala M, Kovatich AJ, Barusevicius A, Miettinen M. CD 117: a sensitive marker for gastrointestinal stromal tumors that is more specific than CD 34. *Mod Pathol* 1998; 11:728-734.
- Hirota S, Isozaki K, Moriyama Y, et al. Gain-of-function mutations of c-kit in human gastrointestinal stromal tumors. *Science* 1998;279: 577-580.
- Mucciarini C, Rossi G, Bertolini F, et al. Incidence and clinicopathologic features of gastrointestinal stromal tumors. A population-based study. *BMC Cancer* 2007; 7:230 [Epub ahead of print].
- Efstathios P, Athanasios P, Papaconstantinou I, et al. Coexistence of gastrointestinal stromal tumor (GIST) and colorectal adenocarcinoma: A case report. *World J Surg Oncol* 2007; 5:96-101.
- Kover E, Faluhelyi Z, Bogner B, Kalmar K, Horvath G, Tornoczky T. Dual tumours in the GI tract: synchronous and metachronous stromal (GIST) and epithelial/neuroendocrine neoplasms. *Magy Onkol* 2004; 48:315-321.
- Agaimy A, Wuensch PH. Gastrointestinal stromal tumours in patients with other-type cancer: a mere coincidence or an etiological association? A study of 97 GIST cases. *Z. Gastroenterol* 2005; 43:1025-1030.
- Kaffes A, Hughes L, Hollinshead J, Katelaris P. Synchronous primary adenocarcinoma, mucosa-associated lymphoid tissue lymphoma and a stromal tumor in a Helicobacter pylori-infected stomach. *J Gastroenterol Hepatol* 2002; 17:1033-1036.
- Usui M, Matsuda S, Suzuki H, Hirata K, Ogura Y, Shiraiishi T. Somatostatinoma of the papilla of Vater with multiple gastrointestinal stromal tumors in a patient with von Recklinghausen's disease. *J Gastroenterol* 2002; 37:947- 953.
- Liu SW, Chen GH, Hsieh PP. Collision tumor of the stomach: a case report of mixed gastrointestinal stromal tumor and adenocarcinoma. *J Clin Gastroenterol* 2002; 35:332-334.
- Huilgol RL, Young CJ, Solomon MJ. The gist of it: Case reports of a gastrointestinal stromal tumour and a leiomyoma of the anorectum. *ANZ J Surg* 2003;73:167-169.
- DeMatteo RP, Lewis JJ, Leung D, Mudan SS, Woodruff JM, Brennan MF. Two hundred gastrointestinal stromal tumors: recurrence patterns and prognostic factors for survival. *Ann Surg* 2000; 231:51-58.

24. Pithorecky I, Cheney RT, Kraybill WG, Gibbs JF. Gastrointestinal stromal tumors: current diagnosis, biologic behavior and management. *Ann Surg Oncol* 2000; 7: 705–712.
25. Miettinen M, Sarlomo-Rikala M, Lasota J. Gastrointestinal stromal tumors: recent advances in understanding of their biology. *Hum Pathol* 1999; 30:1213-1220.
26. Ludwig DJ, Traverso LW. Gut stromal tumors and their clinical behavior. *Am J Surg* 1997;173:390-394.
27. Miettinen M, Sobin LH, Lasota J. Gastrointestinal stromal tumors of the stomach: a clinicopathologic, immunohistochemical and molecular genetic study of 1765 cases with long-term follow-up. *Am J Surg Pathol* 2005; 29:52-68.
28. Fletcher CD, Berman JJ, Corless C, et al. Diagnosis of gastrointestinal stromal tumors: A consensus approach. *Hum Pathol* 2002; 33:459–465.
29. Gold JS, DeMatteo RP. Combined surgical and molecular therapy: the gastrointestinal stromal tumor model. *Ann Surg* 2006;244:176–184.
30. van der Zwan SM, DeMatteo RP. Gastrointestinal stromal tumor: 5 years later. *Cancer* 2005; 104:1781–1788.
31. Hornick JL, Fletcher CD. The role of KIT in the management of patients with gastrointestinal stromal tumors. *Hum Pathol* 2007; 38:679 –687.
32. Gupta P, Tewari M, Shukla HS. Gastrointestinal stromal tumor. *Surg Oncol* 2008 [Epub ahead of print].
33. Weisberg E, Wright RD, Jiang J, et al. Effects of PKC412, nilotinib, and imatinib against GIST-associated PDGFRA mutants with differential imatinib sensitivity. *Gastroenterology* 2006;131:1734–1742.
34. von Mehren M. Beyond imatinib: second generation c-KIT inhibitors for the management of gastrointestinal stromal tumors. *Clin Colorectal Cancer* 2006; 6 Suppl 1: S30 –S34.