

The perfect biliary plastic stent: the search goes on

Bianca Dinescu^a, Theodor Voiosu^{a,b}, Andreea Benguş^{a,b}, Radu Bogdan Mateescu^{a,b}, Mihail-Radu Voiosu^a, Andrei Voiosu^{a,b}

Carol Davila University of Medicine and Pharmacy; Colentina Clinical Hospital, Bucharest, Romania

Abstract

The introduction of biliary plastic stents has been a landmark achievement in the field of endoscopic retrograde cholangiopancreatography, ensuring minimally invasive and highly effective relief of the obstructed biliary system. Attempts to improve the patency and avoid complications after biliary plastic stenting have led to several innovations, but complications due to stent occlusion are still frequent. Because these complications are clinically relevant, and may guide stent choice and patient management, efforts have been made to elucidate the causes of and ways to prevent occlusion of indwelling stents. In this narrative review we focus on biliary plastic stents and discuss the mechanisms of stent occlusion, existing evidence on salient outcomes, as well as options to overcome existing limitations and prolong plastic stent patency.

Keywords Obstructive jaundice, endoscopic retrograde cholangiopancreatography, cholangitis, stent

Ann Gastroenterol 2023; 36 (5): 490-496

Introduction

Endoscopic stent therapy is a well-established therapeutic approach in patients with benign or malignant biliary obstructive disease. First described in the early 1980s [1], it is now routinely used in strictures caused by biliopancreatic malignancy, regional adenopathies, postoperative strictures or fistulas, chronic pancreatitis, and in some cases of complex choledocholithiasis. Because of its superior mortality and morbidity profile, there has been a definite shift from surgery towards endoscopic stent placement for most of these indications [1-4]. Expert opinion and guidelines highlight

the strengths of individual stent types, but the choice of stent hinges on many factors [2]. Despite its obvious benefits, stent placement does carry a risk of adverse events, and stent occlusion is a relevant common complication. The risk for occlusion increases with time and is associated with severe adverse events, such as cholangitis, which is a potentially life-threatening condition [5].

Because these complications are clinically relevant and may guide stent choice and patient management, efforts have been made to clarify the underlying pathological mechanisms and devise ways to prevent occlusion of indwelling stents. Most recommendations on stent follow up or exchange are based on older studies or expert opinion and no clearcut, evidence-based algorithm has been adopted. Recent guidelines mark a shift toward metal stenting of malignant strictures, but there is still a lack of definite consensus on the relative merits of plastic vs. metal stents in various other clinical settings. The approach to biliary stenting depends on several variables, including stricture etiology and extrahepatic vs. perihilar location of the stricture. Traditionally, benign biliary strictures have been managed with serial plastic stent placement [6], as this allows for a patient-tailored, temporary and progressive approach that ensures adequate dilatation of the stricture. For malignant biliary strictures, the choice between plastic and metal stenting is dependent on stricture characteristics and patient-related factors, including expected survival, physician choice, and stent availability. Despite definite advantages regarding diameter and patency, metal stenting makes reintervention more challenging and may interfere with subsequent surgical resection, particularly for perihilar strictures. On the other hand, plastic biliary stents are much more commonly used, are easy to insert and remove, can be used in temporary conditions,

^aCarol Davila University of Medicine and Pharmacy (Bianca Dinescu, Theodor Voiosu, Andreea Benguş, Radu Bogdan Mateescu, Mihail-Radu Voiosu, Andrei Voiosu); ^bColentina Clinical Hospital (Theodor Voiosu, Andreea Benguş, Radu Bogdan Mateescu, Andrei Voiosu), Bucharest, Romania

Conflict of Interest: None

Correspondence to: Bianca Alexandra Dinescu, MD, Department of Gastroenterology, Colentina Clinical Hospital, Stefan cel Mare, no. 19-21, Bucharest, 020125 Romania, email: dinescu.biancaalexandra@gmail.com

Received 8 October 2022; accepted 19 June 2023; published online 25 July 2023

DOI: <https://doi.org/10.20524/aog.2023.0826>

This is an open access journal, and articles are distributed under the terms of the Creative Commons Attribution-NonCommercial-ShareAlike 4.0 License, which allows others to remix, tweak, and build upon the work non-commercially, as long as appropriate credit is given and the new creations are licensed under the identical terms

and are financially less burdensome than self-expandable metal stents, but their main disadvantage is the rate of malfunction due to clogging. With the advent of interventional endoscopic ultrasound, both biliary plastic stents and new lumen-apposing metal stents have been used for a variety of indications, but these are not covered in the current discussion, which deals with their much more widespread use in the setting of endoscopic retrograde cholangiopancreatography (ERCP). In this narrative review, we focus on biliary plastic stents and discuss the mechanisms of biliary plastic stent occlusion, existing evidence on salient outcomes, and present tested or new techniques to overcome existing limitations and prolong stent patency.

Materials and methods

On March 20, 2022, we conducted a structured search of studies reporting on biliary plastic stent occlusion on PubMed (MEDLINE). We focused on studies reporting stent patency, stent-related complications and survival rate. Our review covers general aspects relating to the composition, diameter and design of plastic stents, characteristics of biofilm and biliary sludge formation, and novel approaches to improve stent patency.

The search terms included the following medical subject headings (MeSH) and text words: for ERCP: cholangiopancreatography endoscopic retrograde, cholangio*, ERCP; for stent: biliary endoprosthesis, bilioduodenal or biliary stent, bile duct endoprosthesis; and for occlusion: patency, blockage, clog*, cholangitis, occlusion.

The search string employed was the following: (((("cholangiopancreatography,endoscopicretrograde"[MeSH Terms]) OR "ERCP"[Title/Abstract] OR "cholangio*" [Title/Abstract] OR ("endoscopic retrograde cholangiography" [text word]))) AND ("Stents"[MeSH Terms] OR ("biliary endoprosthesis"[Title/Abstract] OR ("bilioduodenal"[All Fields] OR "biliary"[All Fields])) AND (stent"[All Fields] OR ("bile duct endoprosthesis"[Title/Abstract]))) AND ("occlusion"[Title/Abstract] OR "patency"[Title/Abstract] OR "blockage"[Title/Abstract] OR "clog*" [Title/Abstract] OR "cholangitis"[Title/Abstract]) NOT (("Case reports" [Publication Type] OR "Letter" [Publication type] OR "Comment" [Publication Type] OR "Letter" [Publication type] OR "Comment" [Publication type] OR letter* [ti] OR comment* [ti] OR (case report* [tiab] OR rat [tiab] OR rats [tiab] OR mouse [tiab] OR mice [tiab] OR animal* [tiab])))).

All manuscripts published from January 1980, with full text version available online via open access, were included in the screening process. Initial searching identified 1028 studies, of which 924 were excluded based on the title, repetition and/or abstract. Thus, 104 studies were fully assessed and a further 18 were excluded for the following reasons: non-English language studies, pediatric studies, case reports, letters to the editor. The algorithm of the literature search is presented in Fig. 1.

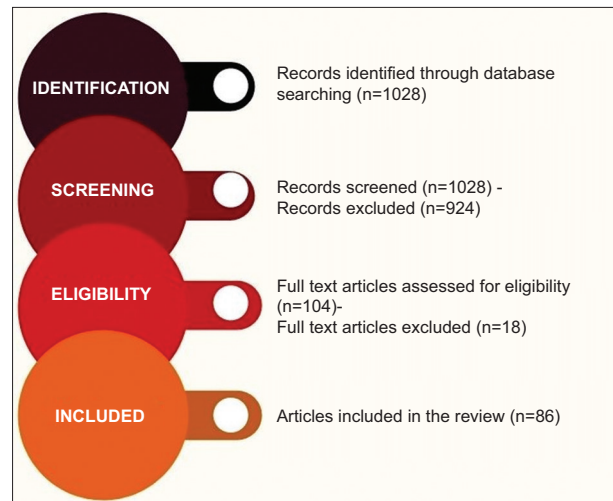


Figure 1 Literature search strategy and results

Plastic stents

Biliary plastic stents are composed of various materials: polyethylene (most common), polyurethane, polyethylene/polyurethane blend, Teflon, or soft polymer blend. Some stents are constructed by combining different layers: e.g., an inner layer of perfluoro, a middle layer of stainless steel and an outer layer of polyamide elastomer. The European Society of Gastrointestinal Endoscopy (ESGE) recommends against Teflon stents as they are not as soft as polyethylene stents [7].

The 2 main specifications that are essential for clinical use are: 1) *the stent diameter*, which ranges from 3-12 Fr (the French [Fr] is the unit of measurement of the external diameter of biliary stents and is equal to one third of a millimeter) with standard external diameters of 7.0, 8.5 and 11.5 Fr; and 2) its *length*, from 1-25 cm. Standard models range from 5-18 cm in length, while longer models are used in liver transplant patients. Stents also vary in shape, as they may be straight, angled or curved, plus the so-called "pigtail" stents, which are coiled at one or both ends (single or double pigtail). Plastic stents may also have side-holes, which are round and placed near the extremities for better drainage. Non-pigtail stents are also manufactured with a side hole and flanges arising from the proximal and distal ends in order to prevent migration while also providing drainage. The Tannenbaum (tree-type) design is provided with 4 flaps proximally and distally, but no side-holes. All plastic stents are radiopaque, and some of them have additional radiomarkers proximally and distally, to facilitate correct placement in the bile ducts [8]. Fig. 2 shows a representation of the most common types of biliary plastic stents.

Other applications of biliary plastic stents and alternatives to plastic stent placement

Plastic stent use has evolved beyond the initial indications, with various designs applied for pancreatic duct stenting,

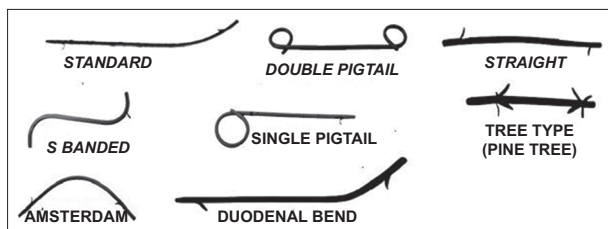


Figure 2 Diagram illustrating basic shapes of common biliary plastic stents in use

both in a prophylactic manner, to prevent post-ERCP pancreatitis [9], and as a therapeutic method for pancreatic duct strictures in chronic pancreatitis [10]. In addition, plastic stents can be used for endoscopic ultrasound-guided drainage of various fluid collections, mainly in cases of complicated acute pancreatitis [11], but also in temporary draining of the gallbladder as a bridge to surgery during acute cholecystitis.

Because of the intrinsic limitations of plastic stents, mainly related to long-term stent patency issues, metal stents have been proposed as an alternative to plastic stents, both in the setting of temporary stenting for benign conditions [12] and as definitive palliation of malignant obstruction [13]. The choice of a particular type of stent (plastic stent, tubular self-expanding metal stent or lumen-apposing metal stent) should be individualized in each case, according to clinical and technical factors, including operator preference and experience, and constitutes a discussion beyond the scope of this particular review.

Mechanisms of biliary stent occlusion

Plastic biliary stent dysfunction is generally due to stent occlusion or migration [14-16]. Other significant complications due to stent placement include cholecystitis, duodenal perforation, bleeding, pancreatitis and stent fracture [17-21].

There are very few studies in the literature about migration risk [22]. Migration is predominantly distal, and occurs in 5-10% of cases [23,24]. Emara *et al* reported that proximal and distal stent migration occurred at a rate of 8.4%, the independent predictors for stent migration being a wide sphincterotomy, a dilated biliary common duct and biliary balloon dilation. Furthermore, wide, straight stents inserted for more than 1 month were more prone to migration. Cholangitis and stent obstruction are the most commonly reported complications of migrated stents [25].

Stent occlusion is a much more frequent adverse event than migration, and several studies have proposed hypotheses about the mechanisms presumably involved. All plastic stents eventually clog up, which is why they are viewed as a temporary solution and require periodic exchange or follow up, except for terminally ill patients. The time to occlusion is dependent on many factors, including internal diameter, correct placement and underlying pathology, but it is generally measured in months. The identification of risk factors associated with early stent occlusion would help individualize stent exchange

intervals and prevent complications of stent occlusion that develop in at least one third of patients [26].

A common theory is that bacterial biofilm and biliary sludge produce a synergic effect when combined with dietary fibers [27-30]. Neither the gallbladder nor the bile duct wall has biofilm under regular, pre-sphincterotomy conditions, suggesting that opportunistic attachment of the microbes occurs later, with subsequent biofilm formation on the biliary stents [31]. The mechanism of biofilm formation is initiated by the process of "priming" of the stent surface with various proteins (fibronectin, vitronectin, laminin, fibrin, collagen) followed by microbial adherence and subsequent formation of an exopolysaccharide matrix to embed the microbial colonies and other particles that give rise to the final mature biofilm [32]. Biliary immunoglobulin-bacteria complexes promote the binding of the bacteria to the inner surface of the stents [33]. This process is very rapid, and Yu *et al* reported attachment of fibronectin to the inner surface of the stents within 24 h of exposure to bile [34].

Bacterial adherence is an important factor of the process. The Gram-negative *Escherichia coli* (*E. coli*), *Klebsiella* species and Gram-positive *Enterococcus* species are the most encountered aerobic bacteria, while *Clostridium* species predominate among anaerobic bacteria. The ratio between aerobic and anaerobic species varies in different studies, depending on the part of the stent analyzed and time expended from stent extraction to actual analysis [32,35]. Rerknimitr *et al* studied all biliary cultures collected during ERCP performed in patients with or without a biliary plastic stent *in situ*, focusing on the microbiology of bile and the antibiotic sensitivities of the organisms identified. *E. coli* and *Enterococcus* were the most common organisms found overall, while enterococci and polymicrobial infections were more common in patients with a biliary stent than in those without a stent [36].

Healthy individuals have sterile bile and pancreatic juice, thanks to the tonic action of the sphincter of Oddi, which prevents ascending development of microorganisms inside the ducts [37]. When a biliary stent is inserted across the sphincter of Oddi, this physical antimicrobial barrier is lost, and reflux of intestinal content promotes ascending microbial colonization [38]. Surface irregularities are thought to enhance bacterial adherence and biofilm formation, facilitating the accumulation of sludge [39]. Chemical analyses have shown that, in addition to the nonbacterial constituents, calcium palmitate and calcium bilirubinate crystals, as well as cholesterol crystals, are commonly present in biliary sludge [27,39,40].

How to improve stent patency?

Given the potential risk of stent obstruction and associated morbidity, most guidelines recommend that biliary stents be removed or changed every 3 months on a scheduled basis [2]. While the median patency of a 10-Fr plastic stent is 4-5 months, the occlusion risk increases rapidly after 3 months [41,42], while premature stent occlusion leads to complications (jaundice, cholangitis or sepsis) that may be life-

threatening [43]. Therefore, prevention of premature occlusion or long-term assurance of stent patency is highly desirable.

Diameter

It seems logical that stents with a larger diameter would have longer patency, because it takes longer for the inner cavity to fill with foreign substances [44]. This has led to the development of large-bore stents, but there is an intrinsic limit to the width of a stent because it has to be delivered through the channel of a duodenoscope [45]. In 1982, the first large-bore 10-Fr plastic stent was endoscopically placed [46]. Speer *et al* retrospectively reviewed the results of 8-Fr stents with pigtailed compared to 10-Fr straight stents in the palliation of biliary obstruction due to malignancy. The incidence of cholangitis following stent insertion was significantly lower with 10-Fr stents, and the time until stent blockage was significantly longer [44,46,47]. Kadakia *et al* compared 10-Fr stents and 11.5-Fr stents with regard to the success rate of stent insertion (85% vs. 79% for 11.5-Fr stents, $P=0.79$), clinical relief of jaundice (88% vs. 90% for 10-Fr stents, $P=0.79$), and the decline in total bilirubin (7.4 vs. 8.3 mg/100 mL, $P=0.67$). The complication rate was similar in both groups and the authors concluded that 10-Fr stents have similar efficacy and complication rates to 11.5-Fr stents in the management of biliary tract diseases [48].

Shape

Straight, angled or curved, with single or multiple flaps, with side holes proximally and distally—the effect on patency of plastic stent shape does not seem significant [45]. [29,45,56]. A randomized prospective trial involving 130 patients compared the Olympus Doublelayer stent (DLS; perfluoroalkoxy), which has no side holes, with a classic polyethylene stent with side holes. The results showed that the Doublelayer stent had a longer patency (114±15 days vs. 105±12 days, $P<0.05$) and a smaller risk of occlusion (144±11 days vs. 99±9 days, $P<0.05$) [49].

A small pilot study has reported the use of “wing stents” for the treatment of malignant biliary obstruction. The hypothesis was that, because of its lack of a lumen, it would not be susceptible to the usual clogging factors. In the short term, the stent appeared to be efficient, but whether such a stent will prove to be better than its conventional counterpart remains to be established via prospective comparative trials [50]. Further modifications, such as insertion of a larger circular lumen for bile flow into its architecture, or a combined use of conventional and wing stents in the same case, are also under consideration [51–53].

Stents with antireflux valves may also lead to longer patency. In a randomized trial performed by Dua *et al*, using a 10-Fr antireflux biliary plastic stent, average patency was 145 days for the antireflux stents and 101 days for the control group, with no statistically significant difference [54].

Material

It is unclear whether the choice of material significantly impacts patency rates [55]. Cheon *et al* performed a prospective, comparative randomized trial, comparing a new polyurethane stent made of a soft and pliable material (pellethane) with a standard 10-Fr polyethylene stent that showed a lower migration rate, but no difference in median stent patency was found between the 2 groups [56]. A 7-Fr double pigtail, dual tapered-tip polyethylene stent, with less memory at body temperature and a larger number of drainage holes, was used successfully in 2012 [57]. The addition of 2 visual and radiopaque markers identifies the pigtail locations via both video endoscopy and fluoroscopy. Each pigtail is 5 cm long and contains 17 drainage holes, compared to the 4–6 holes on conventional double pigtail stents. These innovations are intended to increase the ease and accuracy of placement, while allowing for better biliary and pancreatic drainage and stent durability [58], but further data will be required to gauge their efficacy.

Because bacterial adhesion to plastic stents is associated with surface hydrophobicity, studies have attempted to evaluate stents with hydrophilic coatings [59–61]. Silver coated stents, impregnation of biliary stents with antimicrobial agents, or new biomaterials have been explored, but no definitive recommendation can be made at this point [62,63].

Bioabsorbable stents have been studied for the treatment of benign and malignant biliary strictures. The use of polylactic acid as a potential bioabsorbable material was first described in 1966 [64]; Kukarni *et al* decided to use polylactic acid implants on porcine models, with good results, the implants being biodegradable and safe [64]. Meng *et al* showed that helical poly-L-lactide stents, evaluated *in vivo* and *in vitro*, had good biocompatibility and a self-clearing effect that cleared the attached sludge away, while also maintaining the self-expanding property [65]. Another feasibility study was performed in a porcine model, using a self-expanding 10 mm/50 mm stent composed of polylactide filaments loaded with barium for radio-opacity. Stent function and biotolerance were assessed by cholangiography, serum bilirubin and necropsy for histopathology performed in pairs at 2, 4, 6, and 12 months. The patency was confirmed in 7 of 8 pigs at 2 months, 6 of 6 at 4 months and 4 of 4 at 6 months. No bile duct integration or proliferative changes were seen at the level of the stent [66]. Haber *et al* demonstrated safe deployment of a 10 mm/74 mm bioabsorbable poly-L-lactide stent in 48 of 50 patients with malignant biliary obstruction [67].

Recently, Yamamoto *et al* placed biodegradable 6 mm/15 mm poly-L-lactide Y stents with a platinum marker in the bile ducts of 12 dogs. Cholangiography and laparotomy were performed at 1, 3, 6, and 9 months, and revealed that the stents were patent at all time points. Moderate fragmentation was seen in all stents removed at 9 months [68].

Bioabsorbable stents may offer advantages for the treatment of benign and malignant biliary strictures, including large stent diameter, low biofilm accumulation and proliferative changes, elimination of the need for stent removal and imaging artifacts, and prospects for drug impregnation.

Other methods

Innovations in materials or construction, effective though they may be, do not change the underlying issue of a foreign body (i.e., the plastic stent) being deployed and disrupting the sphincter of Oddi. A logical option to prevent bacterial colonization and stent dysfunction might seem to be the use of prophylactic antibiotic treatment. *In vitro* and *in vivo* studies have reported that ciprofloxacin has good tissue penetration and achieves a high concentration in the bile, thus reducing bacterial adhesions [69]. Despite the benefits demonstrated *in vitro*, clinical trials have failed to show significant improvement of stent patency, whereas quality of life was negatively influenced by antibiotic use [70-72]. Ampicillin-sulbactam, ursodeoxycholic acid with cyclical antibiotics or plus norfloxacin have also been unsuccessfully tested in this setting [73-76]. Furthermore, a Cochrane review reported no significant effect of antibiotic therapy on stent patency or mortality rate [76].

Another way to reduce bacterial migration and deposition of organic material might be to place the stent above an intact sphincter of Oddi, instead of across the sphincter or after sphincterotomy. A prospective randomized trial compared these 2 options, but found that stents placed above an intact sphincter for palliation of malignant obstructive jaundice had a higher migration rate, rather than improved patency [77].

Shockwave application to clean the occluded biliary endoprostheses was attempted in an *in vitro* study of 35 plastic biliary stents retrieved from 24 patients. Shockwave pulses were administered every 10 mm along the prosthesis, stored in a liquid-filled latex balloon. Shockwave application showed only a limited cleaning effect in clogged plastic biliary endoprostheses and to date has not been further developed as a suitable alternative to regular stent replacement [78].

Unfortunately, all these different methods of increasing stent patency have not led to remarkable improvements in biliary plastic stenting, and for malignant indications self-expanding metal stents continue to provide obvious benefits regarding patency [79]. New materials that are significantly more effective in preventing biofilm formation, and that translate into relevant clinical results, larger diameter channel duodenoscopes, self-expandable plastic stents or bioabsorbable plastic stents with larger diameter, are potential game changers for patency, but there is an intrinsic limit to what can be achieved by technologies designed with the express purpose of “temporary” stenting.

Concluding remarks

The introduction of biliary plastic stents has been a landmark achievement in the field of ERCP, ensuring minimally invasive and highly effective treatment for biliary obstruction of various causes. Attempts to improve the patency and avoid complications after biliary plastic stenting have led to several innovations, but complications due to stent occlusion are still frequent. Endoscopists should be aware of the existing stent

specifications and their estimated life cycles in order to choose optimal solutions for their patients. Further study of the causes of stent occlusion, and how to avoid premature clogging and delayed adverse events, is necessary to improve patient care.

References

1. Soehendra N, Reynders-Frederix V. Palliative bile duct drainage - a new endoscopic method of introducing a transpapillary drain. *Endoscopy* 1980;**12**:8-11.
2. Dumonceau JM, Tringali A, Blero D, et al; European Society of Gastrointestinal Endoscopy. Biliary stenting: indications, choice of stents and results: European Society of Gastrointestinal Endoscopy (ESGE) clinical guideline. *Endoscopy* 2012;**44**:277-298.
3. Davids PH, Tanka AK, Rauws EA, et al. Benign biliary strictures. Surgery or endoscopy? *Ann Surg* 1993;**217**:237-243.
4. Smith AC, Dowsett JF, Russell RC, Hatfield AR, Cotton PB. Randomised trial of endoscopic stenting versus surgical bypass in malignant low bileduct obstruction. *Lancet* 1994;**344**:1655-1660.
5. Lawrence C, Romagnuolo J, Payne KM, Hawes RH, Cotton PB. Low symptomatic premature stent occlusion of multiple plastic stents for benign biliary strictures: comparing standard and prolonged stent change intervals. *Gastrointest Endosc* 2010;**72**:558-563.
6. Draganov P, Hoffman B, Marsh W, Cotton P, Cunningham J. Long-term outcome in patients with benign biliary strictures treated endoscopically with multiple stents. *Gastrointest Endosc* 2002;**55**:680-686.
7. Moy BT, Birk JW. An update to hepatobiliary stents. *J Clin Transl Hepatol* 2015;**3**:67-77.
8. ASGE Technology Assessment Committee, Pfau PR, Pleskow DK, Banerjee S, et al. Pancreatic and biliary stents. *Gastrointest Endosc* 2013;**77**:319-327.
9. Mazaki T, Masuda H, Takayama T. Prophylactic pancreatic stent placement and post-ERCP pancreatitis: a systematic review and meta-analysis. *Endoscopy* 2010;**42**:842-853.
10. Costamagna G, Bulajic M, Tringali A, et al. Multiple stenting of refractory pancreatic duct strictures in severe chronic pancreatitis: long-term results. *Endoscopy* 2006;**38**:254-259.
11. Tyberg A, Karia K, Gabr M, et al. Management of pancreatic fluid collections: A comprehensive review of the literature. *World J Gastroenterol* 2016;**22**:2256-2270.
12. Ramchandani M, Lakhtakia S, Costamagna G, et al. Fully covered self-expanding metal stent vs multiple plastic stents to treat benign biliary strictures secondary to chronic pancreatitis: a multicenter randomized trial. *Gastroenterology* 2021;**161**:185-195.
13. Almadi MA, Barkun A, Martel M. Plastic vs. self-expandable metal stents for palliation in malignant biliary obstruction: a series of meta-analyses. *Am J Gastroenterol* 2017;**112**:260-273.
14. Blake AM, Monga N, Dunn EM. Biliary stent causing colovaginal fistula: case report. *JSLs* 2004;**8**:73-75.
15. Lenzo NP, Garas G. Biliary stent migration with colonic diverticular perforation. *Gastrointest Endosc* 1998;**47**:543-544.
16. Wurbs D. The development of biliary drainage and stenting. *Endoscopy* 1998;**30**:A202-A206.
17. Lee MJ, Mueller PR, Saini S, Morrison MC, Brink JA, Hahn PF. Occlusion of biliary endoprostheses: presentation and management. *Radiology* 1990;**176**:531-534.
18. Lowe GM, Bernfield JB, Smith CS, Matalon TA. Gastric pneumatosis: sign of biliary stent-related perforation. *Radiology* 1990;**174**:1037-1038.
19. Mueller PR, Ferrucci JT Jr, Teplick SK, et al. Biliary stent endoprosthesis: analysis of complications in 113 patients. *Radiology*

- 1985;156:637-639.
20. Lahoti S, Catalano MF, Geenen JE, Schmalz MJ. Endoscopic retrieval of proximally migrated biliary and pancreatic stents: experience of a large referral center. *Gastrointest Endosc* 1998;47:486-491.
 21. Baty V, Denis B, Bigard MA, Gaucher P. Sigmoid diverticular perforation relating to the migration of a polyethylene endoprosthesis. *Endoscopy* 1996;28:781.
 22. Johanson JF, Schmalz MJ, Geenen JE. Incidence and risk factors for biliary and pancreatic stent migration. *Gastrointest Endosc* 1992;38:341-346.
 23. Bagul A, Pollard C, Dennison AR. A review of problems following insertion of biliary stents illustrated by an unusual complication. *Ann R Coll Surg Engl* 2010;92:W27-W31.
 24. Arhan M, Odemiş B, Parlak E, Ertuğrul I, Başar O. Migration of biliary plastic stents: experience of a tertiary center. *Surg Endosc* 2009;23:769-775.
 25. Emara MH, Ahmed MH, Mohammed AS, Radwan MI, Mahros AM. Biliary stent migration: why, how, and what? *Eur J Gastroenterol Hepatol* 2021;33:967-973.
 26. Donelli G, Guaglianone E, Di Rosa R, Fiocca F, Basoli A. Plastic biliary stent occlusion: factors involved and possible preventive approaches. *Clin Med Res* 2007;5:53-60.
 27. Rajjman I. Biliary and pancreatic stents. *Gastrointest Endosc Clin N Am* 2003;13:561-592, vii-viii.
 28. Libby ED, Leung JW. Prevention of biliary stent clogging: a clinical review. *Am J Gastroenterol* 1996;91:1301-1308.
 29. van Berkel AM, van Marle J, Groen AK, Bruno MJ. Mechanisms of biliary stent clogging: confocal laser scanning and scanning electron microscopy. *Endoscopy* 2005;37:729-734.
 30. Leung JW, Liu YL, Desta T, Libby E, Inciardi JF, Lam K. Is there a synergistic effect between mixed bacterial infection in biofilm formation on biliary stents? *Gastrointest Endosc* 1998;48:250-257.
 31. Swidinski A, Schlien P, Pernthaler A, et al. Bacterial biofilm within diseased pancreatic and biliary tracts. *Gut* 2005;54:388-395.
 32. Vaishnavi C, Samanta J, Kochhar R. Characterization of biofilms in biliary stents and potential factors involved in occlusion. *World J Gastroenterol* 2018;24:112-123.
 33. Chan FK, Suen M, Li JY, Sung JJ. Bile immunoglobulins and blockage of biliary endoprosthesis: an immunohistochemical study. *Biomed Pharmacother* 1998;52:403-407.
 34. Yu JL, Andersson R, Ljungh A. Protein adsorption and bacterial adhesion to biliary stent materials. *J Surg Res* 1996;62:69-73.
 35. Dowidar N, Kolmos HJ, Lyon H, Matzen P. Clogging of biliary endoprostheses. A morphologic and bacteriologic study. *Scand J Gastroenterol* 1991;26:1137-1144.
 36. Rerknimitr R, Fogel EL, Kalayci C, Esber E, Lehman GA, Sherman S. Microbiology of bile in patients with cholangitis or cholestasis with and without plastic biliary endoprosthesis. *Gastrointest Endosc* 2002;56:885-889.
 37. Sung JY, Leung JW, Shaffer EA, Lam K, Olson ME, Costerton JW. Ascending infection of the biliary tract after surgical sphincterotomy and biliary stenting. *J Gastroenterol Hepatol* 1992;7:240-245.
 38. An YH, Friedman RJ. Concise review of mechanisms of bacterial adhesion to biomaterial surfaces. *J Biomed Mater Res* 1998;43:338-348.
 39. Speer AG, Cotton PB, Rode J, et al. Biliary stent blockage with bacterial biofilm. A light and electron microscopy study. *Ann Intern Med* 1988;108:546-553.
 40. van Berkel AM, van Marle J, Groen AK, Bruno MJ. Mechanisms of biliary stent clogging: confocal laser scanning and scanning electron microscopy. *Endoscopy* 2005;37:729-734.
 41. Schmassmann A, von Gunten E, Knuchel J, Scheurer U, Fehr HF, Halter F. Wallstents versus plastic stents in malignant biliary obstruction: effects of stent patency of the first and second stent on patient compliance and survival. *Am J Gastroenterol* 1996;91:654-659.
 42. Shepherd HA, Royle G, Ross AP, Diba A, Arthur M, Colin-Jones D. Endoscopic biliary endoprosthesis in the palliation of malignant obstruction of the distal common bile duct: a randomized trial. *Br J Surg* 1988;75:1166-1168.
 43. Motte S, Deviere J, Dumonceau JM, Serruys E, Thys JP, Cremer M. Risk factors for septicemia following endoscopic biliary stenting. *Gastroenterology* 1991;101:1374-1381.
 44. Speer AG, Cotton PB, MacRae KD. Endoscopic management of malignant biliary obstruction: stents of 10 French gauge are preferable to stents of 8 French gauge. *Gastrointest Endosc* 1988;34:412-417.
 45. Terruzzi V, Comin U, De Grazia F, et al. Prospective randomized trial comparing Tannenbaum Teflon and standard polyethylene stents in distal malignant biliary stenosis. *Gastrointest Endosc* 2000;51:23-27.
 46. Huibregtse K, Tytgat GN. Palliative treatment of obstructive jaundice by transpapillary introduction of large bore bile duct endoprosthesis. *Gut* 1982;23:371-375.
 47. Laurence BH, Cotton PB. Decompression of malignant biliary obstruction by duodenoscopic intubation of bile duct. *Br Med J* 1980;280:522-523.
 48. Kadakia SC, Starnes E. Comparison of 10 French gauge stent with 11.5 French gauge stent in patients with biliary tract diseases. *Gastrointest Endosc* 1992;38:454-459.
 49. Tringali A, Mutignani M, Perri V, et al. A prospective, randomized multicenter trial comparing DoubleLayer and polyethylene stents for malignant distal common bile duct strictures. *Endoscopy* 2003;35:992-997.
 50. Raju GS, Sud R, Elfert AA, Enaba M, Kalloo A, Pasricha PJ. Biliary drainage by using stents without a central lumen: a pilot study. *Gastrointest Endosc* 2006;63:317-320.
 51. Khashab MA, Hutfless S, Kim K, et al. A comparative evaluation of early stent occlusion among biliary conventional versus wing stents. *Dig Dis Sci* 2012;57:1708-1716.
 52. Schmidt A, Riecken B, Rische S, et al. Wing-shaped plastic stents vs. self-expandable metal stents for palliative drainage of malignant distal biliary obstruction: a randomized multicenter study. *Endoscopy* 2015;47:430-436.
 53. Ayres L, Cheriyan D, Scott R, et al. A randomized trial comparing winged versus conventional plastic stents for malignant bile duct strictures. *Endosc Int Open* 2017;5:E635-E641.
 54. Dua KS, Reddy ND, Rao VG, Banerjee R, Medda B, Lang I. Impact of reducing duodenobiliary reflux on biliary stent patency: an *in vitro* evaluation and a prospective randomized clinical trial that used a biliary stent with an antireflux valve. *Gastrointest Endosc* 2007;65:819-828.
 55. Moss AC, Morris E, Leyden J, MacMathuna P. Do the benefits of metal stents justify the costs? A systematic review and meta-analysis of trials comparing endoscopic stents for malignant biliary obstruction. *Eur J Gastroenterol Hepatol* 2007;19:1119-1124.
 56. Cheon YK, Oh HC, Cho YD, Lee TY, Shim CS. New 10F soft and pliable polyurethane stents decrease the migration rate compared with conventional 10F polyethylene stents in hilar biliary obstruction: results of a pilot study. *Gastrointest Endosc* 2012;75:790-797.
 57. Hair CD, Sejjal DV. Future developments in biliary stenting. *Clin Exp Gastroenterol* 2013;6:91-99.
 58. Sung JY, Shaffer EA, Lam K, Rususka I, Costerton JW. Hydrophobic bile salt inhibits bacterial adhesion on biliary stent material. *Dig Dis Sci* 1994;39:999-1006.
 59. Sung JY, Shaffer EA, Lam K, Rususka I, Costerton JW. Hydrophobic bile salt inhibits bacterial adhesion on biliary stent material. *Dig Dis Sci* 1994;39:999-1006.

60. John SF, Hillier VF, Handley PS, Derrick MR. Adhesion of staphylococci to polyurethane and hydrogel-coated polyurethane catheters assayed by an improved radiolabelling technique. *J Med Microbiol* 1995;**43**:133-140.
61. McAllister EW, Carey LC, Brady PG, Heller R, Kovacs SG. The role of polymeric surface smoothness of biliary stents in bacterial adherence, biofilm deposition, and stent occlusion. *Gastrointest Endosc* 1993;**39**:422-425.
62. Leung JW, Lau GT, Sung JJ, Costerton JW. Decreased bacterial adherence to silver-coated stent material: an *in vitro* study. *Gastrointest Endosc* 1992;**38**:338-340.
63. Rees EN, Tebbs SE, Elliott TS. Role of antimicrobial-impregnated polymer and Teflon in the prevention of biliary stent blockage. *J Hosp Infect* 1998;**39**:323-329.
64. Kulkarni RK, Pani KC, Neuman C, Leonard F. Polylactic acid for surgical implants. *Arch Surg* 1966;**93**:839-843.
65. Meng B, Wang J, Zhu N, Meng QY, Cui FZ, Xu YX. Study of biodegradable and self-expandable PLLA helical biliary stent *in vivo* and *in vitro*. *J Mater Sci Mater Med* 2006;**17**:611-617.
66. Ginsberg G, Cope C, Shah J, et al. *In vivo* evaluation of a new bioabsorbable self-expanding biliary stent. *Gastrointest Endosc* 2003;**58**:777-784.
67. Hair CD, Sejpal DV. Future developments in biliary stenting. *Clin Exp Gastroenterol* 2013;**6**:91-99.
68. Yamamoto K, Yoshioka T, Furuichi K, et al. Experimental study of poly-L-lactic acid biodegradable stents in normal canine bile ducts. *Cardiovasc Intervent Radiol* 2011;**34**:601-608.
69. Leung JW, Liu YL, Desta TD, Libby ED, Inciardi JF, Lam K. *In vitro* evaluation of antibiotic prophylaxis in the prevention of biliary stent blockage. *Gastrointest Endosc* 2000;**51**:296-303.
70. Leung JW, Libby ED, Morck DW, et al. Is prophylactic ciprofloxacin effective in delaying biliary stent blockage? *Gastrointest Endosc* 2000;**52**:175-182.
71. Luman W, Ghosh S, Palmer KR. A combination of ciprofloxacin and Rowachol does not prevent biliary stent occlusion. *Gastrointest Endosc* 1999;**49**:316-321.
72. Chan G, Barkun J, Barkun AN, et al. The role of ciprofloxacin in prolonging polyethylene biliary stent patency: a multicenter, double-blinded effectiveness study. *J Gastrointest Surg* 2005;**9**:481-488.
73. Tsang TK, Pollack J, Chodash HB. Inhibition of biliary endoprostheses occlusion by ampicillin-sulbactam in an *in vitro* model. *J Lab Clin Med* 1997;**130**:643-648.
74. Ghosh S, Palmer KR. Prevention of biliary stent occlusion using cyclical antibiotics and ursodeoxycholic acid. *Gut* 1994;**35**:1757-1759.
75. Barrioz T, Ingrand P, Besson I, de Ledinghen V, Silvain C, Beauchant M. Randomised trial of prevention of biliary stent occlusion by ursodeoxycholic acid plus norfloxacin. *Lancet* 1994;**344**:581-582.
76. Galandi D, Schwarzer G, Bassler D, Allgaier HP. Ursodeoxycholic acid and/or antibiotics for prevention of biliary stent occlusion. *Cochrane Database Syst Rev* 2002;**2002**:CD003043.
77. Pedersen FM, Lassen AT, Schaffalitzky de Muckadell OB. Randomized trial of stent placed above and across the sphincter of Oddi in malignant bile duct obstruction. *Gastrointest Endosc* 1998;**48**:574-579.
78. Farnbacher MJ, Kraupa W, Schneider HT. Cleaning of occluded biliary endoprostheses: is shockwave application an alternative to regular stent exchange? *J Med Eng Technol* 2013;**37**:10-16.
79. Carr-Locke DL, Ball TJ, Connors PJ, et al. Multicenter, randomized trial of Wallstent biliary endoprosthesis versus plastic stents. *Gastrointest Endosc* 1993;**39**:A310.