

Case report

Three cases of esophageal perforation treated successfully with plastic stents and clips

D. Kapetanios, G. Kokozidis, T. Maris, A. Ilias, A. Augerinos, K. Vasiliou, F. Samantara, O. Christophoulou, I. Avramidis, G. Kitis

SUMMARY

Esophageal perforation is a clinical condition that in the past was usually managed with surgical intervention. The application of clips and self-expanding removable plastic stents facilitated conservative treatment of esophageal perforation. Here we present 3 cases with esophageal perforation treated with self-expanding plastic stents or clips.

Key words: Esophageal perforation, stents, clips

INTRODUCTION

Esophageal perforation, spontaneous or iatrogenic, is considered a difficultly managed clinical state. Surgical and conservative approaches are both characterized by considerable morbidity and mortality. The application of self-expanding covered metallic stents offer an alternative treatment in patients of high risk for surgery. The major disadvantage of metallic stents is that they are removed with difficulty and often result in complications. Plastic self-expanding silicon covered stents and clips placement is a more acceptable approach, due to lower complication rates.

CASE REPORT

The first patient was a 64 year old man, who presented with fever, right thoracic pain and right pleural effusion. WBC was 16100/ μ l (neutrophils 82%), Hb 15,9g/

Gastroenterology Department, George Papanikolaou Hospital, Thessaloniki, Greece

Author for correspondence:

D. Kapetanios, George Papanikolaou Hospital, Thessaloniki, Tel.: +2313 307 006, e-mail: dkapetan@otenet.gr

dl, PLT 173000/ μ l, serum glucose 127mg/dl, serum amylase 39IU/L and LDH 249IU/L. Pleural fluid glucose was 13mg/dl, LDH 19640IU/L and amylase 793IU/L. These results led to the suspicion of spontaneous esophageal rupture and therefore esophagoscopy was performed, which revealed an esophageal tear of 4mm length and indeterminate depth, 36cm from the teeth (fig 1). Gastroesophageal junction was at 43cm from the teeth.

Forty eight hours after the assumed time of perforation we placed a 12 cm long Polyflex stent (Microvasive Endoscopy, Boston Scientific corp, Boston, Mass). The pleural effusion was drained and antibiotics were administered. Feeding started after 5 days and two weeks later the patient was discharged. The stent was removed with rat tooth forceps, without complications, after 3 months. No granulation tissue was observed at the upper or lower end of the stent. After stent removal, a diverticulum was observed at the site of the tear (fig 2).

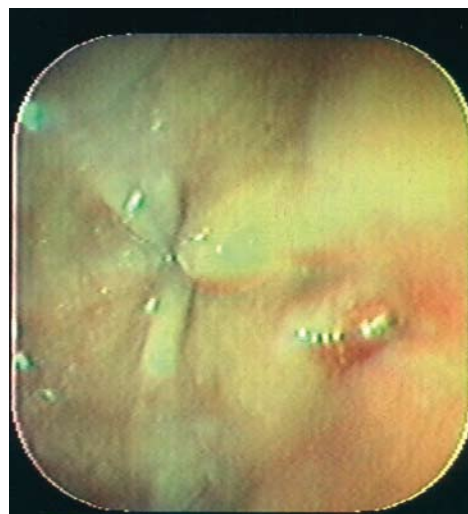

Figure 1.

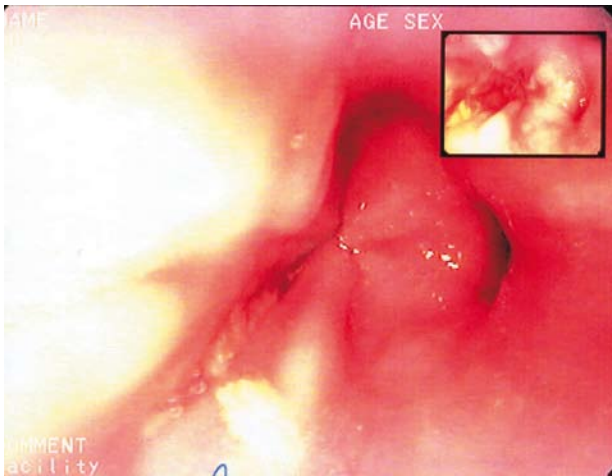


Figure 2.

The second patient was a 60-year-old male who was admitted with esophageal perforation caused during an attempt to remove a food bolus, in another hospital. During esophagoscopy, the bolus was removed with a Roth net (US Endoscopy, Ohio). After reinsertion of the instrument, a 4cm esophageal perforation was recognized at the lower part of the oesophagus, covering 50% of the esophageal circumference (fig 3). The perforation was treated with placement of a 9cm long Polyflex stent 48 hours after its creation (fig 4). Pleural effusion was drained, feeding started after 7 days and the patient was discharged 3 weeks later in very good condition. A second look esophagoscopy was not performed because the patient migrated.

The third patient was a 28-year-old female who was also admitted to our hospital with iatrogenic esophageal

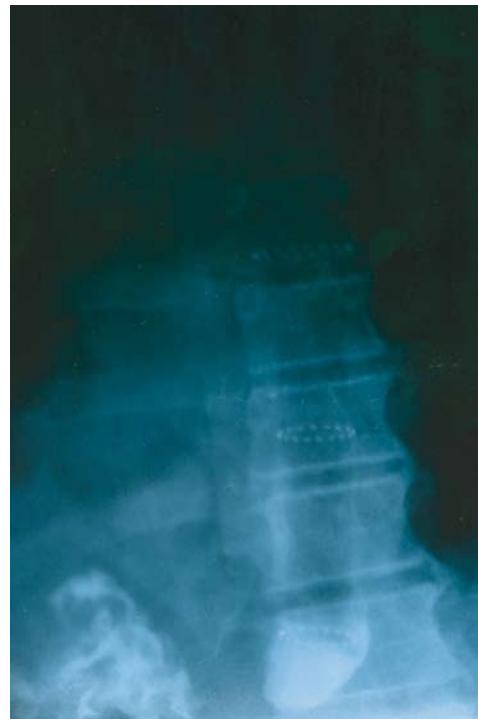

Figure 4.

perforation after foreign body removal. During esophagoscopy, a 10mm perforation 35cm from the teeth was diagnosed (fig 5). Sealing of the perforation was successful after placement of 5 Resolution clips (Microvasive Endoscopy, Boston Scientific corp, Boston, Mass). Pleural effusion was drained, feeding started after 4 days and the patient was discharged two weeks later. Barium swallow was used to access closure of the leakage, as in the pre-

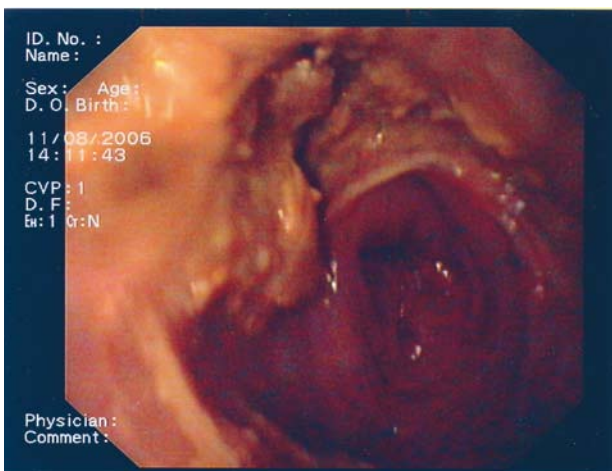


Figure 3.

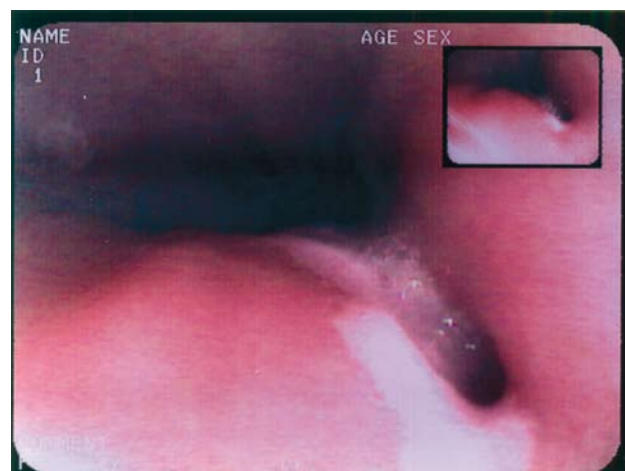


Figure 5.

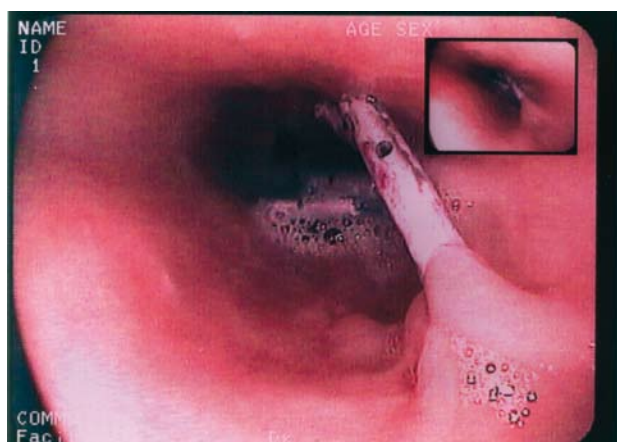

Figure 6.

vious cases. After one month, a second esophagoscopy showed that 4 of the 5 clips were still in place (fig 6), the patient being in perfect condition.

DISCUSSION

Esophageal perforation is a clinical situation with high morbidity and mortality either treated surgically or conservatively, especially when diagnosis and treatment is delayed. Endoscopic esophageal stent placement was introduced for the treatment of patients with malignant stenoses or fistulas. As the survival probability of these patients is low, the stents were left in place until their death. The self-expanding stents were originally metallic, covered, with uncovered parts in both ends, to ensure that the stent does not migrate. These uncovered parts cause inflammatory granulation tissue growth and the stent is embedded in the esophageal mucosa. In this situation, stent removal is very difficult and can cause complications such as haemorrhage or perforation. Therefore endoscopists were reluctant to place metallic stents in benign conditions. Plastic self-expandable stents were applied later, with the advantage of being completely covered with silicon, avoiding thus excess tissue growth. Additionally, their diameter shortens when they are stretched, so they can be easily removed.¹

On the other hand, clips can be easily placed in order to seal small defects in the esophageal wall. In a recent report, 17 cases of esophageal rupture treated successfully with clips have been found in the literature.²

Schubert et al recommend that a dehiscence less than 30% of the circumference could be treated with fibrin glue or clips.³ We decided to place a Polyflex stent in the first patient, although the leak was small, because the diagnosis was delayed due to late admission to the hospital and thus, this procedure was considered to be safer.

We did not proceed to endoscopic cleansing of the fistula and mediastinum, as Schubert et al did. Immediate drainage and stent or clip placement was adequate for all our patients and this is a sufficient procedure, as Siersema commented.¹ The cause of the esophageal rupture in this patient was not identified, so it was considered spontaneous. Successful treatment of spontaneous esophageal rupture with the Polyflex stent has been rarely reported.⁴

The second patient had a large dehiscence, 4cm long, covering 50% of the esophageal circumference, impacted food bolus and the stent was placed 48 hours after the rupture. Despite these unfavourable characteristics, treatment was successful.

Clips were placed in the third patient 60 hours after the perforation, but drainage and treatment with antibiotics were immediately employed. The outcome was also successful despite the delayed endoscopic treatment.

In conclusion, our results support the primary role of the endoscopic procedures in the treatment of esophageal perforation. Morbidity and mortality are decreased and patients avoid surgery.

REFERENCES

1. Siersema P. Treatment of esophageal perforations and anastomotic leaks: the endoscopist is stepping into the arena. *Gastrointest Endosc* 2005; 7:897-900.
2. Qadeer MA, Dumot JA, Vargo JJ, Lopez AR, Rice TW. Endoscopic clips for closing esophageal perforations: case report and pooled analysis. *Gastrointest Endosc* 2007; 66:605-611.
3. Schubert D, Scheidbach H, Kuhn R, Wex C, Weiss G, Eder F, et al. Endoscopic treatment of thoracic esophageal anastomotic leaks by using silicone-covered, self-expanding polyester stents. *Gastrointest Endosc* 2005; 61:891-896.
4. Gelbmann CM, Ratiu NL, Rath HC, Rogler G, Lock G, Scholmerich J et al. Use of self expandable plastic stents for the treatment of esophageal perforations and symptomatic anastomotic leaks. *Endoscopy* 2004; 36:695-699.