

# Pancreatic endometriosis: a systematic review

Ioannis D. Gkegkes<sup>a,b</sup>, Alexandros Fotiou<sup>c</sup>, Vasileios K. Mavroeidis<sup>d</sup>, Ioannis N. Gerogiannis<sup>e</sup>, Christos Iavazzo<sup>f</sup>

Royal Devon and Exeter NHS Foundation Trust, Exeter, UK; Athens Colorectal Laboratory, Greece; Metaxa Cancer Hospital, Piraeus, Greece; The Royal Marsden NHS Foundation Trust, London, UK; Kingston Hospital NHS Foundation Trust, Kingston, Greater London, UK

## Abstract

**Background** Extrapelvic manifestations of endometriosis can be identified in nearly every part of the female body, and the true prevalence of extrapelvic locations is unknown. Pancreatic endometriosis may manifest in several ways, ranging from emergency presentations to asymptomatic cysts.

**Method** A systematic PubMed and Scopus search was conducted.

**Results** Eighteen patients from 17 case reports were included. The patients' mean age was 39.3 (range: 21-72) years. An emergency presentation was noted in 8 of the 18 (44.4%) patients. Menstrual irregularity was present in 3 (16.7%) patients, while in 3 (16.7%) cases there was simultaneous presence of endometriosis elsewhere. The most frequent symptoms at presentation of pancreatic endometrial cysts were epigastric pain, acute left upper quadrant pain, back pain, nausea/vomiting/diarrhea, which occurred in 12 (66.7%), 11 (61.1%), 4 (22.2%), and 6 (33.3%) patients, respectively. Only one case presented as an asymptomatic pancreatic cyst. The maximum diameter of the endometrial cysts ranged from 1-16 cm. In the majority of cases, surgical treatment was offered (16/18, 88.9%). Recurrence of pancreatic endometrial cyst occurred in one case only, following needle aspiration of the endometrial cyst. No fatality was reported.

**Conclusions** Review of the available published literature suggests that pancreatic endometriosis is a rare condition that should be included in the differential diagnosis of pancreatic masses. Further clinical and experimental studies are necessary to investigate the pathogenesis of extrapelvic and pancreatic endometriosis.

**Keywords** Pancreas, endometriosis, endometrial cyst, abdominal mass, pancreatic endometriosis

*Ann Gastroenterol 2023; 36 (1): 61-67*

<sup>a</sup>Department of Colorectal Surgery, Royal Devon and Exeter NHS Foundation Trust, Exeter, UK (Ioannis D. Gkegkes); <sup>b</sup>Athens Colorectal Laboratory, Athens, Greece (Ioannis D. Gkegkes); <sup>c</sup>Gynaecological Oncology Department, Metaxa Cancer Hospital, Piraeus, Greece (Alexandros Fotiou, Christos Iavazzo); <sup>d</sup>Department of Academic Surgery, The Royal Marsden NHS Foundation Trust, London, UK (Vasileios K. Mavroeidis); <sup>e</sup>Department of General and Emergency Surgery, Kingston Hospital NHS Foundation Trust, Kingston, Greater London, UK (Ioannis N. Gerogiannis)

Conflict of Interest: None

Correspondence to: Ioannis D. Gkegkes, MD, PhD, 17C James House, Residential Village, EX2 5DS, Bovemoors Lane, Exeter, UK, e-mail: ioannisgkegkes@gmail.com

Received 12 June 2022; accepted 7 July 2022; published online 15 November 2022

DOI: <https://doi.org/10.20524/aog.2023.0760>

This is an open access journal, and articles are distributed under the terms of the Creative Commons Attribution-NonCommercial-ShareAlike 4.0 License, which allows others to remix, tweak, and build upon the work non-commercially, as long as appropriate credit is given and the new creations are licensed under the identical terms

## Introduction

Cystic lesions of the pancreas often pose difficulties in both their diagnosis and management. Pancreatic cystic formations can be mainly classified into 4 categories: 1) congenital cysts; 2) primary cystic neoplasms; 3) acquired cysts, including cysts of infective origin and post-inflammatory cysts (e.g., pseudocyst); and 4) pancreatic cysts, which originate from extra-pancreatic cystic disorders [1,2]. Endometrial cysts of the pancreas are included in the latter category.

Endometriosis is a benign condition, which occurs when endometrial cells are present outside the uterus. It occurs in up to 10% of women of reproductive age, while one quarter of affected patients are symptomatic [3]. Extragenital manifestations of endometriosis may affect up to 40% of cases with pelvic endometriosis, with intestinal and urinary tract locations being the most frequent. In addition, extragenital endometrial cysts have been described in a great variety of organs, such as liver, brain and lungs, but only a small number of cases with pancreatic involvement have been

described [4,5]. In this study, we aimed to present the available evidence concerning pancreatic endometriosis, by performing a systematic review of the literature.

**Materials and methods**

A systematic, electronic search was performed in PubMed and Scopus. All databases were accessed until June 12, 2022. The literature search was performed in accordance with the Preferred Reporting Items for Systematic Reviews and Meta-Analyses (PRISMA) guidelines [6]. The search strategy for both databases included the combination of the key words: (pancreas OR pancreatic) AND (endometriosis OR endometrioma OR endometrioid cyst). The references of relevant articles were also searched for additional studies.

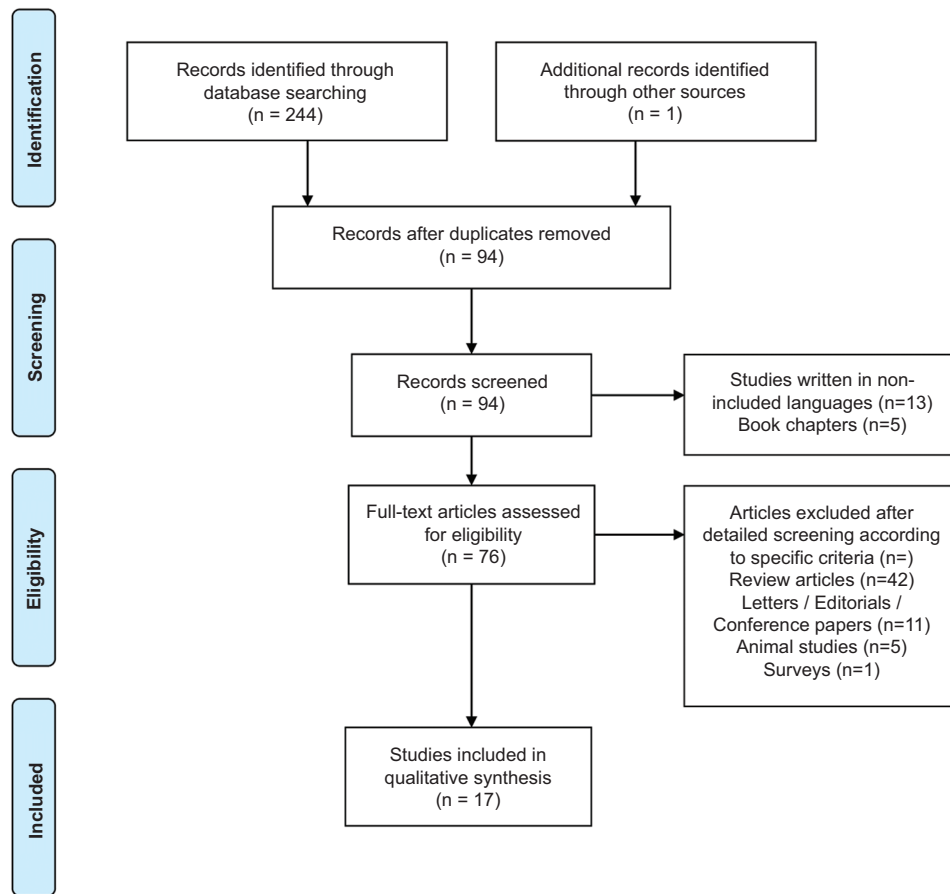
Studies reporting data on pancreatic endometriosis were included in this review. Specifically, data extracted from each of the included studies included the demographic characteristics (age) of the included patients, the clinical setting of the symptom onset, patients’ menstrual history, the clinical manifestation of pancreatic endometriosis, preoperative evaluation/imaging required, the anatomic location of endometrial cysts in the pancreas, the type of treatment selected (surgical or not), the

type of operation performed and the postoperative outcomes. Abstracts in scientific conferences, conference papers, editorials and animal studies were excluded. Studies published in languages other than English, Dutch, German, Italian or Greek were also excluded from this review. Duplicates between the included databases were removed. The database search was independently performed by IDG and AF. JBI’s critical appraisal tools assisted in assessing the trustworthiness, relevance and results of published papers. The extracted data (findings of individual studies) were combined and evaluated to present a critical interpretive synthesis.

**Results**

The search in PubMed and in Scopus retrieved 187 and 57 articles, respectively, from which 17 studies were identified as eligible for inclusion in our review. One additional study was identified through a manual search of references. The search and selection process is graphically represented in Fig. 1 (flow diagram).

The available data from case reports referring to patients with pancreatic endometriosis are summarized in Table 1; data for 18 patients from 17 case reports are



**Figure 1** Flow diagram showing the detailed process of selection of articles for inclusion in the review

**Table 1** Main characteristics and outcomes of the patients with pancreatic endometriosis

Demographics	n/N (%)
No. of patients included	18
Age in years, mean (range)	39.3 (21-72)
Clinical setting of the symptom onset	
Emergency setting	8/18 (44.4)
Menstrual history	
Irregular menstruation	3/18 (16.7)
Simultaneous presence of endometriosis elsewhere	3/18 (16.7)
Clinical manifestation of pancreatic endometriosis	
Symptom duration before the diagnosis, median (range)	13 months (2-84 days)
Epigastralgia	12/18 (66.7)
Acute LUQ pain	11/18 (61.1)
Back pain	4/18 (22.2)
Nausea/vomiting/diarrhea	6/18 (33.3)
Asymptomatic	1/18 (5.6)
Preoperative evaluation /imaging	
CT scan	15/18 (83.3)
MRI scan	6/18 (33.3)
U/S	5/18 (27.8)
EUS	3/18 (16.7)
Angiography / CT angiography	2/18 (11.1)
MRCP	2/18 (11.1)
ERCP	2/18 (11.1)
Elevated serum amylase (>110 U/L)	6/18 (33.3)
Normal tumor markers	18/18 (100)
Length of endometrial cysts (in cm), range	1-16
Anatomic location of endometrial cysts in pancreas	
Body	6/18 (33.3)
Tail	9/18 (50)
Body and tail	2/18 (11.1)
Head	1/18 (5.6)
Treatment options	
No surgical treatment (drainage, etc.)	2/18 (11.1)
Surgical treatment	16/18 (88.9)
Type of operation	
Distal pancreatectomy	2/18 (11.1)
Distal pancreatectomy / splenectomy	12/18 (66.7)*
Laparoscopic surgical exploration/left oophorectomy	1/18 (5.6)
Robotic pancreas-sparing cyst resection/cystogastrostomy	1/18 (5.6)
Postoperative outcomes	
Post-op complications	2/18 (11.1) <sup>†</sup>
Recurrence	1/18 (5.6) <sup>†</sup>
Follow up (in months), median (range)	12 (6-60)
Death	0/18

<sup>†</sup>In 3 cases, additionally performed procedures included cholecystectomy, left nephrectomy and subtotal distal gastrectomy, respectively

\*Asymptomatic small cystic lesion in the tail of the pancreas, for which conservative management was advised. In the second patient, a postoperative abscess was formed at the surgical site of the initial operation

<sup>†</sup>Recurrence after needle drainage of endometrial cyst

N, number; LUQ, left upper quadrant; CT, computed tomography; MRI, magnetic resonance imaging; U/S, ultrasound; EUS, endoscopic ultrasound; MRCP, magnetic resonance cholangiopancreatography; ERCP, endoscopic retrograde cholangiopancreatography

presented [2,7-22]. The patients' mean age was 39.3 (range: 21-72) years. An emergency presentation was noted in 8 of the 18 (44.4%) patients. Menstrual irregularity was present in 3 (16.7%) patients, while in 3 (16.7%) there was simultaneous presence of endometriosis elsewhere. The median duration

of symptoms before the diagnosis was 13 months (range: 2-84 days). The most frequent symptoms at presentation of pancreatic endometrial cysts were epigastric pain, acute left upper quadrant pain, back pain, nausea/vomiting/diarrhea, which occurred in 12 (66.7%), 11 (61.1%), 4 (22.2%) and

6 (33.3%) patients, respectively. Only one case presented as an asymptomatic pancreatic cyst (1/18, 5.6%). Computed tomography (CT) was commonly used for preoperative evaluation (15/18, 83.3%). Magnetic resonance imaging (MRI), ultrasound, endoscopic ultrasound, angiography/CT angiography, magnetic resonance cholangiopancreatography and endoscopic retrograde cholangiopancreatography were used in 6 (33.3%), 5 (27.8%), 3 (16.7%), 2 (11.1%), 2 (11.1%), and 2 cases (11.1%), respectively. At the time of symptom presentation, elevated serum amylase (>110 U/L) was present in 6 of the 18 (33.3%) patients, while all tumor markers were normal in all patients. The maximum diameter of the endometrial cysts ranged from 1-16 cm. The most common anatomic location was the tail of the pancreas (9/18, 50%), while location in the pancreatic body, the body and tail, or the head was noted in 6 (33.3%), 2 (11.1%), and 1 (5.6%) patient, respectively. In the majority of cases, surgical treatment was undertaken (16/18, 88.9%). With regard to the type of surgical treatment, distal pancreatectomy, distal pancreatectomy with splenectomy, laparoscopic surgical exploration combined with left oophorectomy and robotic pancreas-sparing cyst resection combined with cystogastrostomy, were performed in 2 (11.1%), 12 (66.7%), 1 (5.6%), and 1 (5.6%) patient, respectively. None of the included patients was on preoperative hormonal treatment, while postoperative hormonal therapy was administered in only 1 patient [22]. Recurrence of pancreatic endometrial cyst occurred in one case, following needle aspiration. The median follow-up period of the studied patients was 12 (range: 6-60) months. No fatality was reported.

## Discussion

Extrapelvic manifestations of endometriosis can be identified in nearly every organ of the female body, with the true prevalence of extrapelvic endometriosis being unknown [23]. As shown in this review, pancreatic endometriosis may manifest in several ways, ranging from emergency presentation to asymptomatic cyst identification.

Explanations of the spread of endometrial tissue to distant sites are based on the pathogenesis of endometriosis and include various theories, such as retrograde menstruation, metaplasia of celomic epithelium, maturation of undifferentiated cells, migration of embryologic Mullerian duct cells, or lymphatic and hematogenous dissemination of endometrial cells. The dominant theory of retrograde menstruation and migration of endometrial cells through patent fallopian tubes into the peritoneal cavity cannot explain the presence of endometriosis in distant sites, such as the lungs, the liver parenchyma or the central nervous system. For such sites, the theory of lymphatic or hematogenous dissemination has gained acceptance, with several publications supporting this route of endometrial cell spread [24].

A review of the available literature demonstrates that in almost half of the reported cases the symptom onset occurred as an emergency (8/18, 44.4%). Menstrual irregularity (3/18, 16.7%) and a history of endometriosis (3/18, 16.7%) were

not common. Patients' medical history revealed a previous diagnosis of pelvic endometriosis in only 3 of 18 (16.7%), while previous gynecological surgery (cesarean section, adnexectomy, cystectomy, myomectomy) was reported in 5 of them. Such operations may lead to spread of endometrial cells with resultant implants into the peritoneal cavity. Symptoms were commonly related to the upper abdomen. The anatomic location of the pancreas and the acute presentation of symptoms dictate the use of CT scan as the first-line imaging technique. Biochemistry may be of assistance in the differential diagnosis. Elevated serum amylase was not always present (6/18, 33.3%) while all tumor markers so far have tested normal. In the majority of the patients surveyed, surgical treatment was performed (16/18, 88.9%), mainly owing to the difficulty of otherwise establishing a definite diagnosis. Furthermore, a single case of recurrence of pancreatic endometrial cyst was related to previous simple needle aspiration, subsequently prompting surgical resection. Overall, only one minor postoperative complication was mentioned in the published reports.

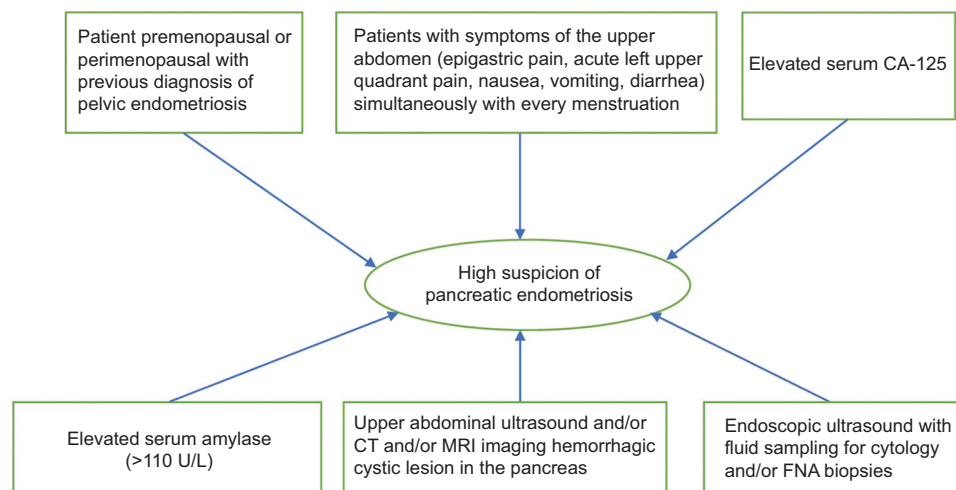
Although endometriosis is a quite common entity for gynecologists, its extrapelvic location and the fact that pancreatic lesions are quite rare mean that it is usually treated by non-gynecologists. For this reason, we aim to raise awareness of this rare entity among surgeons, especially in women of reproductive age with a previous diagnosis of endometriosis, patients with symptoms that mimic endometriosis or prior lower abdominal surgeries. Pancreatic endometriosis is a very rare entity, largely lacking striking features to make preoperative diagnosis common in the absence of histopathological confirmation [7,10,12,19,21,25]. The differential diagnosis is wide and includes a range of benign, premalignant and malignant neoplastic cystic lesions of the pancreas, as well as non-neoplastic lesions. The main problem lies with the fact that endometriotic pancreatic cysts may commonly mimic neoplastic cysts/tumors and, importantly, those with malignant potential, owing to overlapping radiographic and laboratory features [12]. Hence, the main differential diagnosis usually has to be made with mucinous tumors, such as mucinous cystic neoplasm (MCN) and intraductal papillary mucinous neoplasm (IPMN), or with solid pseudopapillary tumor (SPT), while serous cystadenoma and pseudocysts are also commonly included in the differential diagnosis [7,10,12]. However, partly because of the rarity of pancreatic endometriosis, no established laboratory or radiographic investigations exist to ensure successful differentiation [10,12]. In general, the diagnostic accuracy of preoperative imaging for pancreatic cysts has been reported between 68% and 86% [10], while distinguishing mucinous neoplastic from non-neoplastic epithelial cysts is often difficult. Consequently, a diagnosis is commonly made upon histological examination of the resected specimen [7]. The authors of a case report of a patient with a history of endometriosis and a previous cesarean section highlighted that on MRI there were soft tissue changes surrounding the pancreas, displaying a hyperintense T1 signal and a hypointense T2 signal in the absence of diffusion restriction and contrast enhancement. Their interpretation was that the hyperintense T1 signal with fat suppression was suggestive of blood products,

thus excluding a diagnosis of malignancy and supporting a diagnosis of pancreatic endometriosis. They concluded that, in the presence of these findings, pancreatic endometriosis can be recognized radiologically. It is noteworthy that this was the only case described so far in which pancreatic endometriosis was considered in the preoperative differential diagnosis [20]. In the majority of the included studies, suspicion of pancreatic endometriosis was included in the preoperative differential diagnosis, but the definitive diagnosis was identified as a clear surgical finding. It is of note that only a very small proportion of the patients included in our review had undergone MRI and endoscopic ultrasound (EUS) before surgery. However, these tests are now the tests of choice for pancreatic cysts. For this reason, we suggest that a specific algorithm should be followed to make a diagnosis of pancreatic endometriosis, similar to the one for every pancreatic cystic mass as proposed in the Consensus algorithm of the Virginia Mason Multi-Disciplinary Pancreas Work Group [26]. A simplified algorithmic model for the clinical approach to the diagnosis is presented in Fig. 2.

One of the main diagnostic tools for pancreatic cystic lesions is EUS with fluid sampling for cytology and biochemistry, as well as fine-needle aspiration (FNA) biopsies. Cyst fluid carcinoembryonic antigen (CEA) is considered a typical useful marker in differentiating mucinous pancreatic cysts from non-mucinous, with MCN being known to correlate with significantly higher cyst fluid CEA levels as opposed to other cystic lesions [7,10]. Various studies have reported different cutoff values with variable diagnostic reliability, sensitivity and specificity, ranging from 109.9-800 ng/mL [7,10]. However, very interestingly, it has to be underlined that several cases of pancreatic endometriotic cysts were found to have high cyst fluid CEA levels, a fact which severely reinforced a presumptive diagnosis of MCN and prompted resectional treatment [7]. More specifically, available fluid samples from endometriotic cysts so far have revealed CEA levels of 179 ng/mL [10], 940 ng/mL [7], and 951 ng/mL [12]. Moreover, the mural thickness is present in most endometriosis cysts in the

pancreas. In this setting, the presence of enhancing solid components or mural thickness could be misdiagnosed as a potentially malignant neoplasm [27]. Since EUS-guided tissue acquisition with FNA needles usually shows poor diagnostic accuracy, through-the-needle biopsy using microforceps has been used to increase the diagnostic yield in difficult cases, such as pancreatic endometriosis [28].

MCNs usually do not have elevated cyst fluid amylase, as they are not directly connected to the pancreatic duct [12]. Although endometriotic cysts are not connected to the pancreatic duct either, high fluid amylase levels have been detected in a number of cases [19], and more specifically >1000 U/L [12], 1850 U/L [7], 11,000 U/L [11], and 12,220 U/L [10]. A suspicion of MCN is also enhanced by the common location of endometriotic cysts at the pancreatic tail, while MCN typically affects middle-aged females [12]. MCN typically has a smooth contour and wall enhancement on imaging, while it may display calcifications, multiple loculations and thick internal septations, as well as papillary or nodular protrusions [12,19]. Such findings, however, have also been seen in cases of endometriotic cysts [21]. Histologically, MCN is characterized by mucinous epithelium with a varying degree of dysplasia and, typically, cellular ovarian-like stroma [12]. This type of stroma may microscopically resemble endometrial stroma. However, on immunohistochemistry it is often positive for inhibin, estrogen and progesterone receptor, while it is negative for CD10, a typical immunohistochemical marker for endometrial stroma [12]. In fact, 87.5% of reported cases of pancreatic endometriosis (14/16) have undergone resection owing to a preoperative suspicion of either a premalignant or malignant lesion [2,7-12,14-19,21], and the remaining 2 underwent surgical exploration with an uncertain preoperative diagnosis [13,20]. All cases were ultimately diagnosed only after surgical management. Equally, a number of cases were reported where mucin was identified from the cyst aspirate [7]. On EUS, a connection of the cystic lesion with a pancreatic duct is a strong diagnostic feature for IPMN, although this



**Figure 2** A simplified algorithm for the clinical approach to diagnosis  
CT, computed tomography; MRI, magnetic resonance imaging; FNA, fine-needle aspiration

finding has also been described in the case of a lesion ultimately proven to be endometriotic cyst, without confirmation of such connection on histological assessment [10,14,21].

Pancreatic pseudocysts are the most frequently encountered pancreatic cysts, commonly resulting from episodes of acute severe pancreatitis or pancreatic injury [7,14]. In the context of acute pancreatitis, they typically develop following a sequence, starting from peripancreatic fluid collections, to walled-off collections, and finally pseudocysts, usually over a 6- to 8-week period [12]. These pseudocysts are lined by inflammatory connective tissue and a fibrous wall, as opposed to true cysts, lined by different types of epithelium [11]. The time relation of a cyst with a previous episode of severe pancreatitis can be important; however, interestingly, a number of cases with endometriotic cysts presented with an episode or a recent history of pancreatitis [12]. Multiple pancreatic cysts can be seen in association with polycystic kidney disease [11], as well as in von Hippel-Lindau disease [29]. However, multiple cysts have also been described in the context of pancreatic endometriosis [14,17]. The presence of hemorrhagic content, and the absence of a polycystic or honeycomb morphology, may help differentiate from a serous cystic neoplasm [14]. A SPT commonly affects women of childbearing age, and usually presents as a complex mass with solid and cystic components, while calcifications and arterial enhancement of its walls may occasionally occur [19].

In general terms, pancreatic endometriosis is a rare entity and, therefore, a preoperative suspicion may be of pivotal importance. That being said, a female patient at premenopausal or perimenopausal age [4,14,19] with periodic cyclical abdominal pain correlating with her menstrual cycle [7,10,18,20,21] and a history of endometriosis [12,18,20], presenting with a cyst in the tail or body of the pancreas [21], which on MRI displays features of hyperintense T1-weighted when bleeding is present, and hypointense T1-weighted or T2-weighted imaging when bleeding is absent [10,14,20], and appears to have bloody content on EUS assessment [14,21], should raise suspicion for this extremely rare diagnosis.

The histological features of a well-encapsulated cyst lined by endometrial glands and stroma with associated hemorrhage and hemosiderin-laden macrophages [10,18,19,21], and positivity for CD10 on immunohistochemical staining when endometrial glands are not detected, or when only a small amount of endometrial stroma is present [12,18], are typical and diagnostic. On the other hand, for the described cases of pancreatic endometriosis, insufficient sampling has been reported so far to allow for such features to become available preoperatively. Nevertheless, the high diagnostic yield of EUS-guided through-the-needle microforceps biopsy, along with its increasing uptake, may allow for a preoperative diagnosis of pancreatic endometriosis to become available in future cases, even though the microforceps biopsy technique may carry a small risk of complications (e.g., bleeding) [30,31]. In a case of a sizeable retroperitoneal endometriotic cyst compressing the pancreas, EUS-FNA offered reliable preoperative sampling and diagnosis [8].

Concerning the management of pancreatic endometriosis, it has been highlighted that a preoperative diagnosis would enable an unnecessary pancreatic resection to be avoided, as well as the significant morbidity and mortality that may result [4,25]. First-line treatment is the suppression of ovarian function (gonadotropin-releasing hormone agonist therapy) and, equally, when there is significant suspicion of pancreatic endometriosis, hormone suppression can be offered as a diagnostic therapy whilst various investigations are in process [7,21,24]. If the effect of hormone suppression is insufficient in treating the pain, resection should be considered [10,21,24].

In case of a suspected diagnosis of pancreatic endometriosis, if the clinico-laboratory setting warrants surgical exploration, in the absence of concern for a malignant diagnosis, it has been advocated that intraoperative frozen sections may help confirm that suspected diagnosis and allow for a limited procedure, such as drainage, as opposed to pancreatic resection [4,14,20]. It also needs to be highlighted that if resection is deemed clinically mandatory in the presence of a confirmed preoperative diagnosis of pancreatic endometriosis, and in the absence of concern for the presence of malignancy, it is plausible that a spleen-preserving procedure is indicated. Moreover, it should be underlined that there are cases of ovarian endometriosis with malignant transformation, most commonly to adenocarcinoma [8]. This risk is known to be relatively low for extragonadal endometriosis [32]. It is vital that any possibility of malignant transformation should be treated aggressively. So far, no cases of pancreatic endometriosis with malignant transformation have been reported, and the potential for this site is therefore unknown. However, should a case of suspected or confirmed pancreatic endometriosis be evaluated, it should be taken into account by the relevant multidisciplinary meeting, while deciding on the appropriate means of treatment.

As in any systematic review, there are several limitations which should be considered in the analysis of the findings of this study. The limited number of patients included in our study is indicative of the rarity of pancreatic endometrial cysts, and as a result it is difficult to draw safe conclusions. Regarding the data extraction, several articles did not mention important details suggestive of a possible mechanism of endometrial cell spread, such as previous lower abdomen surgeries or previously diagnosed endometriosis. Equally, the limited number of relevant articles does not allow for a clear mechanism to be presumed. Furthermore, although our literature search was extensive, it could be considered selective in that we excluded abstracts, conference papers and editorials. Lastly, language restriction was an extra limitation in our search.

In conclusion, review of the available literature suggests that pancreatic endometriosis is an extremely rare condition that should, however, be included in the differential diagnosis of pancreatic masses, especially in patients who present with cyclic pain, dysmenorrhea, and especially a history of endometriosis or pelvic surgery. Further clinical and experimental studies are necessary to investigate the pathogenesis of extrapelvic and pancreatic endometriosis.

## Summary Box

### What is already known:

- Pancreatic endometriosis is an extremely rare condition
- The differential diagnosis of pancreatic endometriosis has a very broad range
- The pathogenesis of extrapelvic and pancreatic endometriosis is unknown

### What the new findings are:

- Pancreatic endometriosis may present as an emergency condition
- First-line treatment is the suppression of ovarian function, while in cases of great size and/or insufficient pain treatment, resection should be considered
- Endoscopic ultrasound-guided through-the-needle microforceps biopsy can be highly diagnostic

## References

- Howard JM. Cystic neoplasms and true cysts of the pancreas. *Surg Clin North Am* 1989;**69**:651-665.
- Lee DS, Baek JT, Ahn BM, et al. A case of pancreatic endometrial cyst. *Korean J Intern Med* 2002;**17**:266-269.
- Bulletti C, Coccia ME, Battistoni S, Borini A. Endometriosis and infertility. *J Assist Reprod Genet* 2010;**27**:441-447.
- Andres MP, Arcoverde FVL, Souza CCC, Fernandes LFC, Abrão MS, Kho RM. Extrapelvic endometriosis: a systematic review. *J Minim Invasive Gynecol* 2020;**27**:373-389.
- Nisolle M, Pasleau F, Foidart JM. [Extragenital endometriosis]. *J Gynecol Obstet Biol Reprod (Paris)* 2007;**36**:173-178.
- Liberati A, Altman DG, Tetzlaff J, et al. The PRISMA statement for reporting systematic reviews and meta-analyses of studies that evaluate health care interventions: explanation and elaboration. *PLoS Med* 2009;**6**:e1000100.
- Assifi MM, Nguyen PD, Agrawal N, et al. Non-neoplastic epithelial cysts of the pancreas: a rare, benign entity. *J Gastrointest Surg* 2014;**18**:523-531.
- Artifon EL, Franzini TA, Kumar A, et al. EUS-guided FNA facilitates the diagnosis of retroperitoneal endometriosis. *Gastrointest Endosc* 2007;**66**:620-622.
- Goswami AK, Sharma SK, Tandon SP, et al. Pancreatic endometriosis presenting as a hypovascular renal mass. *J Urol* 1986;**135**:112-113.
- Huang B, Mooser A, Carpenter D, Montenegro G, Luu C. A rare case of pancreatic endometriosis masquerading as pancreatic mucinous neoplasm. *Case Rep Surg* 2021;**2021**:5570290.
- Marchevsky AM, Zimmerman MJ, Aufses AH Jr, Weiss H. Endometrial cyst of the pancreas. *Gastroenterology* 1984;**86**:1589-1591.
- Mederos MA, Villafañe N, Dhingra S, et al. Pancreatic endometrial cyst mimics mucinous cystic neoplasm of the pancreas. *World J Gastroenterol* 2017;**23**:1113-1118.
- Loja Oropeza D, Alvizuri Escobedo J, Vilca Vasquez M, Altamirano Bautista J. [Endometriosis of the pancreas]. *Rev Gastroenterol Peru* 2009;**29**:55-60.
- Plodeck V, Sommer U, Baretton GB, et al. A rare case of pancreatic endometriosis in a postmenopausal woman and review of the literature. *Acta Radiol Open* 2016;**5**:2058460116669385.
- Sumiyoshi Y, Yamashita Y, Maekawa T, Sakai T, Shirakusa T. A case of hemorrhagic cyst of the pancreas resembling the cystic endometriosis. *Int Surg* 2000;**85**:67-70.
- Tunuguntla A, Van Buren N, Mathews MR, Ehrenfried JA. Endometriosis of the pancreas presenting as a cystic pancreatic neoplasm with possible metastasis. *South Med J* 2004;**97**:1020-1021.
- Verbeke C, Harle M, Sturm J. Cystic endometriosis of the upper abdominal organs. Report on three cases and review of the literature. *Pathol Res Pract* 1996;**192**:300-304.
- Yamamoto R, Konagaya K, Iijima H, et al. A rare case of pancreatic endometrial cyst and review of the literature. *Intern Med* 2019;**58**:1097-1101.
- Karaosmanoglu AD, Arslan S, Ozbay Y, Sokmensuer C, Ozogul E, Karcaaltincaba M. Pancreatic endometrioma presenting with spontaneous hemorrhagic rupture. *Pancreas* 2020;**49**:e23-e24.
- Monrad-Hansen PW, Buanes T, Young VS, Langebrenne A, Qvigstad E. Endometriosis of the pancreas. *J Minim Invasive Gynecol* 2012;**19**:521-523.
- Oishi M, Hashida H, Yuba Y, Takabayashi A. Pancreatic endometrial cyst: report of a case. *Surg Today* 2011;**41**:1011-1015.
- Ludwig C, Kopacz A, Warren ML, Onkendi E. Symptomatic pancreatic body endometrial cyst requiring en bloc distal pancreatectomy. *BMJ Case Rep* 2021;**14**:e244911.
- Culley L, Law C, Hudson N, et al. The social and psychological impact of endometriosis on women's lives: a critical narrative review. *Hum Reprod Update* 2013;**19**:625-639.
- Veeraswamy A, Lewis M, Mann A, Kotikela S, Hajhosseini B, Nezhat C. Extragenital endometriosis. *Clin Obstet Gynecol* 2010;**53**:449-466.
- Okun SD, Lewin DN. Non-neoplastic pancreatic lesions that may mimic malignancy. *Semin Diagn Pathol* 2016;**33**:31-42.
- Oh SY, Irani S, Kozarek RA. Cystic neoplasms of the pancreas: where do we stand? *J Hepatol Gastroint Dis* 2016;**2**:140.
- Lisotti A, Napoleon B, Facciorusso A, et al. Contrast-enhanced EUS for the characterization of mural nodules within pancreatic cystic neoplasms: systematic review and meta-analysis. *Gastrointest Endosc* 2021;**94**:881-889.
- Facciorusso A, Ramai D, Gkolfakis P, et al. Through-the-needle biopsy of pancreatic cystic lesions: current evidence and implications for clinical practice. *Expert Rev Med Devices* 2021;**18**:1165-1174.
- Giorgakis E, Mavroeidis V, Tsironis D, Davidson B. Vascular endothelial growth factor detection in serous pancreatic cysts: have we really reached a breakthrough? *J Am Coll Surg* 2014;**219**:591.
- Tanaka M, Fernández-Del Castillo C, Kamisawa T, et al. Revisions of international consensus Fukuoka guidelines for the management of IPMN of the pancreas. *Pancreatol* 2017;**17**:738-753.
- Westerveld DR, Ponniah SA, Draganov PV, Yang D. Diagnostic yield of EUS-guided through-the-needle microforceps biopsy versus EUS-FNA of pancreatic cystic lesions: a systematic review and meta-analysis. *Endosc Int Open* 2020;**8**:E656-E667.
- Song L, Xing A, Li Q, Wang G. High-grade serous carcinoma resulting from rectal endometriosis and complicated with ovarian cancer. *Front Oncol* 2019;**9**:1252.