

A decade's experience of managing suspected pancreatic adenocarcinoma at a tertiary cancer center

Ikenna K. Emelogu^a, Donald R. Campbell^b, Gandhi Lanke^b, Abraham C. Yu^c,
Graciela Nogueras-Gonzalez^b, Phillip Lum^b, Emmanuel Coronel^b, Phillip S. Ge^b, William A. Ross^b,
Brian R. Weston^b, Matthew H. Katz^b, Jeffrey H. Lee^b

Baylor College of Medicine; The University of Texas MD Anderson Cancer Center; University of Texas Health Sciences Center, Houston, Texas, USA

Abstract

Background We present our experience and established management strategy for endoscopic ultrasonography-guided fine-needle aspiration (EUS-FNA) in diagnosing suspected pancreatic neoplasms at a tertiary referral cancer hospital.

Method Relevant data were extracted from our database for patients who underwent EUS-FNA for suspected pancreatic neoplasms at our institution between 2007 and 2016.

Results Among the 309 patients, the median age was 67 years and 56% were men. The most common presenting symptoms were abdominal pain (37%) and jaundice (29%). Concordance between radiographic diagnosis and final pathology was 89%. The mean lesion size was 34.9 mm on computed tomography and 31.5 mm on EUS. There were 197 patients (64%) with localized disease, of whom 115 (58%) had resectable lesions, 61 (31%) had borderline resectable, and 21 (11%) had unresectable lesions (mean CA 19-9 levels 1705 U/mL, 2490 U/mL, and 479 U/mL, respectively). A median of 3 FNA passes were performed to establish a pathologic diagnosis. Two patients (1%) had postprocedural adverse events. Median overall survival was 47 months in those who underwent surgery after EUS and 12 months in those who did not ($P < 0.001$).

Conclusions A multidisciplinary approach is employed for management of suspected pancreatic neoplasm at our tertiary cancer center. A combination of cross-sectional imaging and EUS-FNA serves as a highly effective duo in establishing a tissue diagnosis and staging with a low adverse event rate. Counterintuitively, CA 19-9 is not necessarily higher with resectable lesions than with unresectable lesions, indicating the limitation of CA 19-9 as a pancreatic tumor marker.

Keywords Endoscopic ultrasound, fine-needle aspiration, pancreatic adenocarcinoma, CA 19-9, cross-sectional imaging

Ann Gastroenterol 2023; 36 (1): 81-86

^aDepartment of Medicine, Baylor College of Medicine (Ikenna K. Emelogu); ^bDivision of Gastroenterology, Hepatology and Nutrition, The University of Texas MD Anderson Cancer Center (Donald R. Campbell, Gandhi Lanke, Graciela Nogueras-Gonzalez, Phillip Lum, Emmanuel Coronel, Phillip S. Ge, William A. Ross, Brian R. Weston, Matthew H. Katz, Jeffrey H. Lee); ^cDepartment of Medicine, University of Texas Health Sciences Center (Abraham C. Yu), Houston, Texas, USA

Conflict of Interest: None

Correspondence to: Jeffrey H. Lee, MD, MPH, Division of Gastroenterology, Hepatology, and Nutrition, The University of Texas MD Anderson Cancer Center, 1515 Holcombe Blvd, Houston, TX 77030, USA, e-mail: jefflee@mdanderson.org

Received 12 November 2021; accepted 3 November 2022; published online 15 November 2022

DOI: <https://doi.org/10.20524/aog.2023.0763>

This is an open access journal, and articles are distributed under the terms of the Creative Commons Attribution-NonCommercial-ShareAlike 4.0 License, which allows others to remix, tweak, and build upon the work non-commercially, as long as appropriate credit is given and the new creations are licensed under the identical terms

Introduction

Pancreatic cancer is the third leading cause of cancer-related death in the United States. Among the various pancreatic cancer cell types, pancreatic ductal adenocarcinoma (PDAC) is the most prevalent type, with an exceedingly high mortality rate [1]. While advancements in prevention and treatment have resulted in significant improvements compared to many other cancers, the incidence of pancreatic cancer continues to rise and the 5-year survival rate remains unchanged, ranging from 2-9% [2].

Currently, screening for pancreatic cancer is neither feasible nor recommended in patients without known risk factors [3,4]. Multiple published data on the management of pancreatic cancer emphasize that the key to improving survival is early detection [4-7]. Unfortunately, no available tumor marker has been demonstrated to aid significantly in the early detection of pancreatic cancer. For a lack of better alternatives, CA 19-9 is currently used as a serum tumor marker, but it carries

poor sensitivity, specificity and accuracy [7,8]. While its role in postoperative surveillance of PDAC is well-documented, further studies are needed to fully determine the utility of CA 19-9 for early diagnosis [9].

Imaging offers another important avenue for early detection of pancreatic malignancies. Computed tomography (CT) has been shown to have a sensitivity of 76-92% and a specificity of 67% for diagnosing pancreatic ductal adenocarcinoma [4]. The magnetic resonance imaging (MRI) pancreas protocol is more sensitive for detecting pancreatic lesions, with the added benefit of avoiding ionizing radiation exposure. However, MRI has been limited in its application because of higher costs, longer imaging time, and risk of patient claustrophobia.

Endoscopic ultrasonography-guided fine-needle aspiration (EUS-FNA) is an established technique in the evaluation and pathologic diagnosis of pancreatic cancer [10,11]. It is generally considered to be the most sensitive diagnostic tool for the early detection of pancreatic cancer [4]. In a recent meta-analysis, EUS had overall sensitivity and specificity of 91% and 94%, respectively [12]. However, a number of other studies have shown variable results comparing EUS to cross-sectional imaging techniques. For example, in the evaluation of high-risk individuals, one prospective study found that EUS was more sensitive than CT or MRI for detecting small, solid lesions, whereas MRI was particularly sensitive for detecting small cystic lesions; the investigators therefore concluded that EUS and MRI are complementary rather than interchangeable modalities [3,13]. Additionally, several factors that may contribute to false negative results with EUS include a recent episode of acute pancreatitis, chronic pancreatitis, presence of a biliary stent, and diffusely infiltrating carcinoma [14]. Nevertheless, EUS-FNA has a clear advantage over conventional cross-sectional imaging in its ability to simultaneously obtain tissue for a pathologic diagnosis. In addition, EUS-FNA has been shown to have a relatively low adverse event rate, especially compared to other invasive diagnostic interventions [15,16]. The aim of our study, therefore, was to share our experience and established management strategy in EUS-FNA for the diagnosis of suspected pancreatic neoplasm at a tertiary referral cancer hospital.

Patients and methods

Patient selection and characteristics

This is a retrospective study of patients who underwent EUS-FNA at the University of Texas MD Anderson Cancer Center for suspected pancreatic neoplasm between 2007 and 2016. Approval for this study was obtained from the Institutional Review Board at MD Anderson (registered March 10, 2010).

Data regarding patient characteristics, medical and oncologic history, laboratory values, imaging, endoscopic procedures, surgeries, and outcomes were collected. Patient

characteristics included age, sex, and race. Medical history included data pertaining to symptoms at presentation, history of diabetes, and alcohol or tobacco use. Oncologic history included type of malignancy. Laboratory values recorded included CA 19-9 levels. Data pertaining to cross-sectional imaging were collected, including type of imaging (CT vs. MRI vs. positron emission tomography), lesion location, lesion size, presence of lymphadenopathy, presence of liver metastases, and radiologic diagnosis.

Endoscopic and surgical procedure data

Data relating to the endoscopic procedure and procedural adverse events (AEs) were obtained from individual endoscopy reports and the electronic medical record. AEs were divided into intraprocedural and postprocedural complications. EUS-FNA was performed under conscious sedation with the administration of intravenous anesthetic. Various types and sizes of needles were employed, at the discretion of the endosonographer (22-G FNA, 25-G FNA, 22-G Core, and 25-G Core; Boston Scientific Corporation, Marlborough, MA, USA; EchoTip Ultra, Cook Medical, Bloomington, IN, USA; NA10J1, NA11JKB, NA-200H-8022; Olympus Medical Systems, Tokyo, Japan or Sono Tip Pro Control; Medi-Globe Corp., Rosenheim, Bavaria, Germany).

Cytological diagnoses were interpreted as “insufficient”, “no atypia” (normal pancreatic tissue), “atypical” (including regenerative atypia by inflammatory changes), “suspicious” or “malignant”. After obtaining tissue from a pancreatic lesion via EUS-FNA, the tissue was reviewed immediately (rapid on-site cytopathological evaluation [ROSE]) by a cytopathologist.

Procedural data obtained for EUS-FNA included lesion location, lesion size, presence of cystic component, needle size and type, use of a second needle, number of passes, procedure duration, endoscopic diagnosis, and whether endoscopic retrograde cholangiopancreatography was performed concurrently. Data regarding intraprocedural and postprocedural AEs, including the need for repeat endoscopic procedures, were recorded. Data on medical oncology treatment, including adjuvant or neoadjuvant chemotherapy and radiation, were obtained. Surgical data were recorded, including time from EUS-FNA to surgery, type of surgery performed, AEs, and postoperative pathologic diagnosis. Finally, follow-up duration, from time of EUS-FNA procedure to date of last follow up or death, was recorded.

Statistical analysis

Descriptive statistics were provided for continuous variables. Frequency tables were used to summarize categorical variables. Wilcoxon's rank sum or the Kruskal-Wallis test were used to evaluate the association between patients' prognostic

factors and outcomes. The distribution of time-to-event endpoints, including overall survival, was estimated using the method of Kaplan and Meier.

Results

A total of 309 patients were identified who underwent EUS-FNA for suspected pancreatic neoplasm and met the search criteria during the study period. The median age at the time of procedure was 67 (range 41-88) years, and 174 patients (56%) were men (Table 1). Two hundred twenty-seven patients (73%) self-identified as non-Hispanic white, 29 patients (9%) as African American or African, 39 patients (13%) as Hispanic or Latino, and 10 patients (3%) as Asian or Pacific Islander. These demographics were roughly equal to those found in the 2010 US National Census. Abdominal pain (113; 37%) and jaundice (90; 29%) were the most common presenting symptoms. Other presenting symptoms included weight loss (43; 14%), nausea and vomiting (3; 1%), new-onset diabetes (4; 1%), and worsening diabetes mellitus (7; 2%). Notably, in 38 patients (12%) the pancreatic lesion was an incidental finding.

Cross-sectional imaging

A total of 304 patients (98%) had a cross-sectional imaging study available, whereas 5 patients (2%) did not have imaging available within the MD Anderson system prior to EUS. Among the cross-sectional imaging studies, CT of the abdomen was the most common modality (284; 93%), followed by MRI (20; 7%). On cross-sectional imaging, the lesions were predominantly found in the head of the pancreas (159; 52%), with a distribution in the head/neck (45; 15%), body (46; 15%), body/tail (15; 5%), and tail alone (25; 8%) (Table 2). In 13 patients (4%), a pancreatic lesion was not visualized on cross-sectional imaging despite being seen on EUS. The mean size of the pancreatic lesions seen on CT imaging was 34.9 mm (standard deviation [SD] ±14.4) (Table 3).

In 169 patients (56%), enlarged regional lymph nodes were identified, while 135 patients (44%) had no evidence of lymphadenopathy. Notably, 7 patients (2%) had both regional and distant lymphadenopathy on initial imaging with signs of metastatic disease (Table 2).

The most common radiographic diagnosis was PDAC in 268 patients (88%), followed by “no mass seen” (9; 3%), intraductal papillary mucinous neoplasm (IPMN) (11; 4%), and “suspicious for metastatic disease” (4; 1%). In 270 (89%) of the 304 patients with cross-sectional imaging, the diagnoses suggested by CT or MRI were consistent with the cytological findings after EUS-FNA. Surgical specimens were available in 63 (21%) of the 304 patients who had cross-sectional imaging. In this subgroup of patients, 48 patients (76%) had

Table 1 Patient characteristics (n=309), demographics, and presenting symptoms

Characteristic	Value
Age, years (median, range)	67 (41-88)
Male sex	174 (56)
Race/ethnicity	
White (non-Hispanic)	227 (73)
African American or African	29 (9)
Hispanic/Latino	39 (13)
Asian/Pacific Islander	10 (3)
Other	4 (1)
Symptom at presentation	
Abdominal pain	113 (37)
Jaundice	90 (29)
Weight loss	43 (14)
New-onset diabetes	4 (1)
Worsening diabetes	7 (2)
Nausea, vomiting	3 (1)
None/Incidental finding	38 (12)

Values are n (%) unless otherwise defined

Table 2 Pancreatic lesion characteristics on computed tomography imaging (n=304)

Location of pancreatic lesion	Value
Head	159 (52)
Head/neck	45 (15)
Body	46 (15)
Body/Tail	15 (5)
Tail	25 (8)
Lymph node involvement	
No lymphadenopathy	135 (44)
Regional lymphadenopathy	162 (53)
Distant lymphadenopathy	7 (2)

Values are n (%)

Table 3 Average size and range of lesions on CT and EUS

Imaging modality	Lesion size (mm), mean±standard deviation	Lesion size (mm), median and range
CT scan	34.9±14.4	33.0 (3.5-89.0)
EUS	31.0±9.8	31.0 (10.0-90.0)

CT, computed tomography; EUS, endoscopic ultrasound

a cancer diagnosis on both imaging and surgical pathology, while 2 patients (3%) were negative for malignancy on both imaging and surgical pathology: i.e., concordance of 79%. Four patients (6%) had a cancer diagnosis on imaging but a benign process on surgical pathology, while 9 patients (21%) had a cancer diagnosis on surgical pathology alone. Notably, of the 4 patients with benign surgical pathology, 3 underwent preoperative chemotherapy and one did not (this patient was noted to have a diagnosis of IPMN with high-grade dysplasia on pathology).

EUS, CA 19-9, surgery and AEs

On EUS, the mean cross-sectional dimension was 31.5 mm (SD±9.8) (Table 3). With involvement of an advanced fellow, the median procedure duration was 56 min (range 17-246) min. FNA was performed during EUS for all 309 patients examined and a median of 3 (range 1-7) passes were performed to establish a pathologic diagnosis (Fig. 1). FNA was performed using a 25-G needle in 275 patients (89%), a 22-G needle in 8 patients (3%), a 22-G Core needle in 4 patients (1%), and a 25-G Core needle in 13 patients (4%). Needle size was not specified in the procedure notes in the remaining 9 patients (3%).

Regarding AEs, none of the patients had intraprocedural complications. Two patients (1%) had postprocedural complications. One patient developed abdominal pain, nausea and vomiting shortly after discharge, managed conservatively in the emergency department. The other patient had mild pancreatitis 3 days after EUS-FNA, diagnosed by clinical symptoms and CT imaging, and requiring a 3-day hospitalization; this patient had a long history of smoking prior to EUS. No significant bleeding, perforations or deaths were noted.

There were 197 patients (64%) with localized disease and among them, 4 (2%) had a lesion size smaller than 2 cm (T1). One hundred fifteen of the 197 patients (58%) showed no involvement of the superior mesenteric artery (SMA) or celiac artery (resectable T1 lesion), 61 patients (31%) had less than 180 degrees of SMA or celiac artery involvement, or had encasement or narrowing of the superior mesenteric vein (SMV) or portal vein (borderline resectable lesion), and 21 patients (11%) had greater than 180 degrees of SMA or celiac artery involvement (unresectable lesion). A serum CA 19-9 measurement (in U/mL) was obtained prior to EUS in 201 patients (65%); however, values were recorded for only 87 patients (28%) after patients with jaundice were excluded. In patients without jaundice, the mean CA 19-9 was 1705.2 U/mL (SD±4641.4) in patients with resectable disease (50; 57%), 2490.1 U/mL (SD±4685.0) in patients with borderline resectable disease (26; 30%), and 478.9 U/mL (SD±1152.7) in patients with unresectable disease (11; 13%) (P=0.078) (Table 4).

After EUS with FNA, 63 patients (23%) underwent surgery, including distal pancreatectomy (11; 17%), duodenojejunostomy (1; 2%), pancreaticoduodenectomy (43; 68%), pylorus-preserving pancreaticoduodenectomy (6; 10%), diagnostic laparoscopy (1; 2%), and total pancreatectomy (1; 2%). The diagnoses made on surgical pathology were adenocarcinoma (57; 90%), "IPMN or high-grade dysplasia" (1; 2%), "no viable tumor cells" (2; 3%), "normal pancreas" (1; 2%), chronic pancreatitis (1; 2%), and "no evidence of malignancy" (1; 2%). The diagnosis made on cytology after EUS-FNA was consistent with surgical pathology results in 57 patients (90%), thus showing a sensitivity of 100% and positive predictive value of 90%. Seventeen (27%) of the 63 patients who underwent surgical interventions had some variety of post-surgical AEs. The most common AEs were

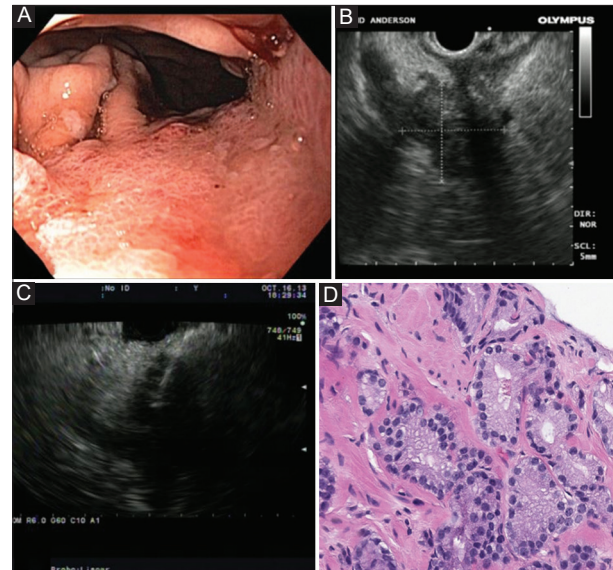


Figure 1 (A) Endoscopic view of depressed area within proximal gastric body. (B) Endo-ultrasonographic view of pancreatic mass extending to the stomach. (C) Ultrasonography-guided fine-needle aspiration (yellow arrow) of pancreatic head mass. (D) Cytopathology slide of pancreatic adenocarcinoma at 200× total magnification

Table 4 Resectability status and CA 19-9 levels in patients without jaundice and with localized disease (n=134)

Resectability status	Number of patients, n (%)	CA 19-9 levels (U/mL)
Resectable	71 (53)	1705
Borderline resectable	45 (34)	2490
Unresectable	18 (13)	479

chylous leak (4; 6%), intra-abdominal fluid collection (3; 5%), and surgical site infection (2; 3%).

Follow up and outcomes

Three-hundred eight patients had follow-up information. A total of 63 patients underwent surgery after EUS-FNA, and 26 of the 63 patients (41%) were deceased by the time of this study. In contrast, 246 patients did not undergo surgery after EUS-FNA, of whom 196 (80%) were deceased at the time of this study. The median overall survival (OS) was 47 months (95% confidence interval [CI] 37-not estimable) for surgery patients compared to 12 months (95%CI 11-14) for non-surgery patients (P<0.001). In the surgery group, 7 patients survived beyond 5 years from the time of the procedure and the 5-year OS was 48% (95%CI 32-63%). Of the remaining 37 patients (59%) who underwent surgery and were alive at the time of this study, the median follow-up duration was 34 (range 4-68) months. In the non-surgery group, one patient survived beyond 5 years from the time of the procedure and the 5-year OS was 4% (95%CI 1-8%). Of the remaining 50 patients (59%)

without surgery who were alive at the time of this study, the median follow up was 11 (range 23-61) months.

Discussion

The objective of this study was to compare the various diagnostic modalities, evaluate the safety and efficacy of EUS-FNA, and share our experience relating to the diagnosis of suspected pancreatic neoplasm. Although cross-sectional imaging is fairly sensitive for detecting lesions suggestive of pancreatic cancer, EUS-FNA has been shown to be equally effective, if not superior, for detecting such lesions. In this study, the average percent variance in lesion size measured on EUS compared to cross-sectional imaging was only 26% (range 0-158%). This is consistent with the report by Du *et al*, who showed that, in a cohort of 93 patients, CT and EUS agreed on mass detection in 88% of cases and mass size in 67% of cases, concluding that CT and EUS performed similarly in identifying characteristics of pancreatic masses, although some discrepancies may exist in other areas such as vascular and lymphatic involvement [17]. EUS-FNA, however, has the added benefit of obtaining tissue for pathologic diagnosis at the same time as endo-ultrasonographic assessment. In the 72 patients who underwent surgery after EUS, a comparison of EUS-FNA cytology with surgical pathology yielded a sensitivity of 100% and positive predictive value of 90% for detecting pancreatic adenocarcinoma. These results may be related, in part, to the experience of the advanced endoscopists and cytopathologists, as well as the high volume of patients seen at this institution. It should be noted that our standard of practice is to utilize ROSE, whereby all pancreatic cytology specimens are reviewed immediately by a cytology specialist at any time of the day when EUS-FNA of a pancreatic lesion is performed. This often resulted in a single pass in establishing a diagnosis, which was beneficial for patients with concerns about increased risk for bleeding and/or infection.

Regarding procedural safety, EUS has offered a less invasive modality to establish a tissue diagnosis in contrast to surgery. One of the main advantages of this approach is its lower risk of postprocedural AEs. The current literature shows that EUS-FNA is generally safe, with some studies reporting AE rates as low as 0.29-1.6% [15,18]. In this study, only 2 patients out of 309 (0.6%) had AEs (i.e., abdominal pain and nausea/vomiting; mild pancreatitis) after EUS-FNA, as opposed to 19 of the 72 patients (23%) who underwent surgery after EUS-FNA. This suggests that there is a significant increase in morbidity in those patients who go on to have surgery. Therefore, the use of EUS-FNA may obviate the need for surgery as a diagnostic intervention, perhaps moving us to an era where surgery can be strictly therapeutic in nature.

Although the observed median overall survival was higher in patients who underwent surgery compared to those who did not (i.e., 47 vs. 12 months), it is important to note that

the sample size was considerably smaller in the former group, so this finding may not reflect a true direct comparison for survival between the 2 groups. In addition, patients who were deemed to be appropriate surgical candidates tended to have fewer comorbidities and were earlier in their disease course compared to those who did not have surgery, and hence would be expected to survive longer.

Another interesting finding in our study was the discrepancies in serum CA 19-9 levels within the various groups of patients based on tumor resectability. According to the National Comprehensive Cancer Network guidelines for surgical management of pancreatic cancer, tumors are divided into resectable, borderline resectable, and unresectable groups, with a positive predictive value of >90% on imaging [19,20]. Resectable lesions do not adhere to large vessels, i.e., celiac artery (CA), superior mesenteric artery (SMA), or common hepatic artery. Borderline resectable lesions involve less than 180 degrees of the SMA or CA, or have encasement or narrowing of the SMV or portal vein. Unresectable lesions have greater than 180 degrees of involvement of the SMA or CA. Essentially, the more advanced the lesion is at the time of diagnosis, the lower the likelihood that it will fall into a resectable group. Despite this fact, average CA 19-9 levels were significantly higher in patients with resectable lesions compared to those with unresectable lesions (1377 U/mL vs. 625 U/mL), contrary to the expected values, thus confirming the limited reliability of CA 19-9 as a marker for predicting the stage of cancer.

It is not clear why this tumor marker trend was observed. As previously mentioned, a limitation of CA 19-9 is its propensity to be elevated in both benign and malignant diseases [21,22]. Although many studies have shown a positive correlation between CA 19-9 and advanced disease, an 11-year retrospective study showed no significant correlation between margin status and preoperative CA 19-9 levels, where positive margins are highly associated with larger, higher stage tumors and worse outcomes [23]. Further studies, therefore, are necessary to fully investigate the diagnostic utility of CA 19-9 as a serum tumor marker in pancreatic cancer.

In conclusion, when a patient with a suspected pancreatic neoplasm presents at our tertiary care center, the patient is managed in a multidisciplinary approach involving medical oncologists, surgical oncologists, radiologists, cytologists and interventional gastroenterologists, who meet weekly. A combination of a cross-sectional imaging study and EUS with FNA serves as a highly effective duo in establishing tissue diagnosis and staging in patients who have a suspected pancreatic neoplasm with a low AE rate. The invaluable support from our cytology specialists, available to read pancreatic specimens at all hours of the day, minimizes the number of FNA passes required to confirm the diagnosis, thus reducing the risk of unwanted AEs. Counterintuitively, CA 19-9 is not necessarily higher with resectable lesions than with unresectable lesions, highlighting the limitation of CA 19-9 as a pancreatic tumor marker.

Summary Box

What is already known:

- Cross-sectional imaging with computed tomography or magnetic resonance imaging is an established modality that allows for early detection of pancreatic malignancies while being a relatively noninvasive test
- Ultrasonography-guided fine-needle aspiration (EUS-FNA) offers the added benefit of obtaining a tissue diagnosis in pancreatic adenocarcinoma, with better sensitivity and specificity compared to cross-sectional imaging alone
- CA 19-9 is an important tumor marker in pancreatic adenocarcinoma; while its role in the postoperative surveillance of pancreatic adenocarcinoma is well-documented, its utility for early diagnosis is yet to be fully determined

What the new findings are:

- At our center, a multidisciplinary approach, including the use of on-site cytopathology along with EUS-FNA, minimizes the number of FNA passes required to confirm the diagnosis of pancreatic adenocarcinoma, thus reducing the risks of unwanted adverse events
- A combination of a cross-sectional imaging study and EUS with FNA serves as a highly effective duo in establishing tissue diagnosis and staging in patients who have a suspected pancreatic neoplasm with a low adverse event rate
- Counterintuitively, CA 19-9 is not necessarily higher with resectable lesions than with unresectable lesions, depicting the limitation of CA 19-9 as a pancreatic tumor marker

References

1. Kanno A, Masamune A, Hanada K, et al; Japan Study Group on the Early Detection of Pancreatic Cancer (JEDPAC). Multicenter study of early pancreatic cancer in Japan. *Pancreatol* 2018;**18**:61-67.
2. McGuigan A, Kelly P, Turkington RC, Jones C, Coleman HG, McCain RS. Pancreatic cancer: a review of clinical diagnosis, epidemiology, treatment and outcomes. *World J Gastroenterol* 2018;**24**:4846-4861.
3. Petrone MC, Arcidiacono PG. New strategies for the early detection of pancreatic cancer. *Expert Rev Gastroenterol Hepatol* 2016;**10**:157-159.
4. Singhi AD, Koay EJ, Chari ST, Maitra A. Early detection of pancreatic cancer: opportunities and challenges. *Gastroenterology* 2019;**156**:2024-2040.
5. Henrikson NB, Aiello Bowles EJ, Blasi PR, et al. Screening for pancreatic cancer: updated evidence report and systematic review for the US preventive services task force. *JAMA* 2019;**322**:445-454.
6. Lindquist CM, Miller FH, Hammond NA, Nikolaidis P. Pancreatic cancer screening. *Abdom Radiol (NY)* 2018;**43**:264-272.
7. Zhou B, Xu J, Cheng Y, et al. Early detection of pancreatic cancer: where are we now and where are we going? *Int J Cancer* 2017;**141**:231-241.
8. Xing H, Wang J, Wang Y, et al. Diagnostic value of CA 19-9 and carcinoembryonic antigen for pancreatic cancer: a meta-analysis. *Gastroenterol Res Pract* 2018;**2018**:8704751.
9. Rieser CJ, Zenati M, Hamad A, et al. CA19-9 on postoperative surveillance in pancreatic ductal adenocarcinoma: predicting recurrence and changing prognosis over time. *Ann Surg Oncol* 2018;**25**:3483-3491.
10. Kitano M, Yoshida T, Itonaga M, Tamura T, Hatamaru K, Yamashita Y. Impact of endoscopic ultrasonography on diagnosis of pancreatic cancer. *J Gastroenterol* 2019;**54**:19-32.
11. Yang L, Iwai T, Kida M, et al. Analysis of the diagnostic yield of endoscopic ultrasonography-guided fine-needle aspiration in patients with a suspected pancreatic malignancy. *Rev Esp Enferm Dig* 2018;**110**:544-550.
12. Hewitt MJ, McPhail MJ, Possamai L, Dhar A, Vlavianos P, Monahan KJ. EUS-guided FNA for diagnosis of solid pancreatic neoplasms: a meta-analysis. *Gastrointest Endosc* 2012;**75**:319-331.
13. Harinck F, Konings IC, Kluij I, et al; Dutch research group on pancreatic cancer surveillance in high-risk individuals. A multicentre comparative prospective blinded analysis of EUS and MRI for screening of pancreatic cancer in high-risk individuals. *Gut* 2016;**65**:1505-1513.
14. Bhattacharya A, Gandhi NS, Baker ME, Chahal P. Gastroenterology and pancreatic adenocarcinoma: what the radiologist needs to know. *Abdom Radiol (NY)* 2018;**43**:364-373.
15. Carrara S, Arcidiacono PG, Mezzi G, Petrone MC, Boemo C, Testoni PA. Pancreatic endoscopic ultrasound-guided fine needle aspiration: complication rate and clinical course in a single centre. *Dig Liver Dis* 2010;**42**:520-523.
16. Gress F, Michael H, Gelrud D, et al. EUS-guided fine-needle aspiration of the pancreas: evaluation of pancreatitis as a complication. *Gastrointest Endosc* 2002;**56**:864-867.
17. Du T, Bill KA, Ford J, et al. The diagnosis and staging of pancreatic cancer: A comparison of endoscopic ultrasound and computed tomography with pancreas protocol. *Am J Surg* 2018;**215**:472-475.
18. Tsutsumi H, Hara K, Mizuno N, et al. Clinical impact of preoperative endoscopic ultrasound-guided fine-needle aspiration for pancreatic ductal adenocarcinoma. *Endosc Ultrasound* 2016;**5**:94-100.
19. Tempero MA, Malafa MP, Al-Hawary M, et al. Pancreatic adenocarcinoma, version 2.2017: clinical practice guidelines in Oncology. *J Natl Compr Cancer Netw* 2017;**15**:1028-1061.
20. Ducreux M, Cuhna AS, Caramella C, et al; ESMO Guidelines Committee. Cancer of the pancreas: ESMO Clinical Practice Guidelines for diagnosis, treatment and follow-up. *Ann Oncol* 2015;**26**(Suppl 5):v56-v68.
21. Cooperman AM, Iskandar ME, Wayne MG, Steele JG. Prevention and early detection of pancreatic cancer. *Surg Clin North Am* 2018;**98**:1-12.
22. Kunovsky L, Tesarikova P, Kala Z, et al. The use of biomarkers in early diagnostics of pancreatic cancer. *Can J Gastroenterol Hepatol* 2018;**2018**:5389820.
23. Mosquera C, Johnson HM, Mitsakos AT, et al. Predictive value of preoperative serum CA19-9 on margin status. *Am Surg* 2019;**85**:965-972.