

Original article

Serum apoptotic caspase activity as a marker of severity in chronic hepatitis C virus infection

G.V. Papatheodoridis¹, Emilia Hadziyannis¹, E. Tsochatzis¹, Anastasia Georgiou¹, Georgia Kafiri², S. Manolakopoulos¹, E.K. Manesis¹, A.J. Archimandritis¹

SUMMARY

Background & Aim: Apoptotic caspases are substantially activated in liver of patients with chronic hepatitis C and preliminary data suggest that serum caspase activity may represent a sensitive marker of early liver injury. We investigated whether the serum levels of caspase-generated fragments of cytokeratin-18 are associated with the severity of liver histological lesions in chronic hepatitis C virus (HCV) infection. **Methods:** We included 134 patients with chronic HCV infection who consecutively underwent liver biopsy as well as 30 healthy controls. Histological liver lesions were evaluated according to the Ishak's classification. Chronic hepatitis C was considered to be present in cases with grading score ≥ 4 and/or stage ≥ 2 , while cases with grading score < 4 and stage < 2 were classified into chronic HCV infection with minimal histological lesions. The levels of caspase-generated cytokeratin-18 fragments were blindly measured in stored serum samples. **Results:** Cytokeratin-18 fragments levels (U/L) were significantly lower in the 30 healthy subjects (154 ± 31) than in the 28 HCV-positive patients with minimal histological lesions (196 ± 71 , $P=0.006$) than in the 106 patients with histological chronic hepatitis C (295 ± 202 , $P<0.001$). ROC curve analysis showed that serum levels of CK-18 fragments offered moderate diagnostic accuracy for differentiating chronic hepatitis C patients from chronic HCV patients with minimal histological lesions [c-statistic: 0.67 (95% CI: 0.56-0.77)].

Conclusions: Serum apoptotic caspase activity is associated with the severity of liver histological lesions in chronic HCV infection, but it has moderate diagnostic accuracy in differentiating chronic HCV patients with and without histological lesions of chronic hepatitis.

Key-words: Apoptosis, hepatitis C, fibrosis

INTRODUCTION

Chronic viral hepatitis is a major health problem worldwide. The severity of liver histological lesions in patients with chronic infection with hepatitis C virus (HCV) may range from almost normal liver or minimal necroinflammation without fibrosis to severe liver injury and even cirrhosis.^{1,2} In clinical practice, it is rather difficult to differentiate patients with minimal lesions from those with chronic hepatitis C having active necroinflammation and fibrosis based on the currently available noninvasive methods, usually determinations of aminotransferases and viremia levels.^{1,2}

Active liver injury results in hepatocellular death with apoptosis representing an important mechanism in chronic hepatitis C.³ Regardless of the type of triggering stimuli, apoptosis eventually leads to activation of several cysteine-aspartate proteases, called caspases, which cleave several cellular proteins including cytokeratin-18 (CK-18).³ In particular, CK-18, which represents a major intermediate filament protein in liver cells,⁴ is cleaved by caspases at two conserved aspartate residues.^{5,6} Recently, a novel enzyme-linked immunosorbent assay has been developed and shown to selectively detect a caspase cleavage-generated neoepitope of CK-18 at aspartate residue 396.⁷ Two initial reports suggested that the serum levels of caspase-generated fragments of CK-18 determined by this assay are associated with the severity of liver disease in both chronic HCV infection and non-alcoholic fatty liver disease (NAFLD).^{7,8}

¹2nd Department of Internal Medicine, Athens University Medical School, Hippokraton General Hospital, Athens, Greece;

²Department of Pathology, Hippokraton General Hospital, Athens, Greece.

Author for correspondence:

G.V. Papatheodoridis, MD. 2nd Department of Internal Medicine, Athens University Medical School, Hippokraton General Hospital of Athens, 114 Vas. Sophias Ave., 115 27 Athens, Greece.
Tel: +30-210-7774742, Fax: +30-210-7706871,
e-mail: gepapath@med.uoa.gr

The aim of this study was to further investigate whether serum levels of caspase-generated fragments of CK-18, as a marker of apoptotic caspase activity, are associated with the severity of liver histological lesions in patients with chronic HCV infection.

PATIENTS AND METHODS

Patient population

We included 134 treatment naïve patients with chronic HCV infection consecutively admitted to our Department between January 2004 and March 2006 in order to undergo a liver biopsy. All these patients had been followed for at least 6 months at outpatient liver clinics before admission for liver biopsy. Patients with malignancy or any type of antiviral therapy in the past or any type of immunomodulatory therapy within the last 12 months as well as those with an inadequate biopsy specimen were excluded. Patients with positive hepatitis B surface antigen (HBsAg) or detectable antibodies against human immunodeficiency virus (anti-HIV) were also excluded. No patient had decompensated liver disease (evidence or history of ascites, variceal bleeding, hepatic encephalopathy or jaundice). Informed consent was obtained from all patients for the performance of liver biopsy. The study was approved by the local ethics committee.

The diagnosis of chronic HCV infection was based on detectable antibodies to HCV (anti-HCV) and detectable serum HCV RNA. Patients with chronic HCV infection were further separated into those with minimal histological lesions and those with chronic hepatitis C according to their histological findings.

Thirty volunteer health care workers [males/females: 13/17, mean age: 44±14 (18-65) years] were also studied as healthy controls. All of them had normal aminotransferases activity and were negative for HBsAg, anti-HCV and anti-HIV.

Methods

Epidemiological and anthropometrical characteristics as well as routine laboratory data [including complete blood count, prothrombin time and serum levels of glucose, cholesterol, triglycerides, ALT, aspartate aminotransferase (AST), alkaline phosphatase (ALP), gamma-glutamyl-transpeptidase (GGT)] were prospectively obtained for all patients on the liver biopsy day. Alcohol abuse was defined as average daily alcohol consumption of more than 30 g in male or 20 g in female patients during the last 12 months.

Commercially available assays were used for all sero-

logical determinations. All patients were tested for HBsAg, anti-HCV, and anti-HIV by enzyme immunoassays. In patients with chronic HCV infection, the presence of serum HCV RNA was determined by a qualitative polymerase chain reaction (PCR) assay (Amplicor Roche; sensitivity 50 IU/L), serum HCV RNA levels were determined by a branch DNA assay (HCV RNA Versant 3.0, Bayern Healthcare, NY) and HCV genotype was also determined by a commercially available assay (HCV Genotype Assay, LIPA, Versant, Bayer Healthcare, Tarrytown, NY, USA).

Measurement of caspase-generated CK-18 fragments in serum

The levels of caspase-generated CK-18 fragments were blindly measured in serum samples (one from each patient) stored at -80°C on the liver biopsy day. We used the M30-Apoptosense ELISA assay (PEVIVA, Alexis, Grönwald, Germany), which has been designed to detect specifically apoptosis of CK-18 positive cells in human serum and plasma and to quantitatively measure the apoptosis-associated neoepitope in the C-terminal domain of CK-18 (amino acids 387-396). The specificity of this assay has been previously confirmed via immunoprecipitation of CK-18 fragments in serum samples.⁷ Determinations for the first 40 samples from patients with chronic HCV infection as well as determinations for 40 samples from patients with NAFLD and 40 samples from patients with chronic hepatitis B virus (HBV) infection were performed in duplicate under blinded code conditions. The mean intra-assay variation was 1.8% (maximum: 8.8%).

Liver histology

All 171 liver biopsies had an adequate specimen with length ≥ 1.5 cm. Two additional biopsies were excluded because of an inadequate liver specimen, as predefined if no portal tracts were identified or the specimen size itself made it impossible to make a proper evaluation. All liver biopsies were evaluated blindly by a single liver histopathologist (GK).

The histological changes of chronic HCV infection were classified according to the classification proposed by Ishak et al.⁹ Chronic hepatitis C was considered to be present in cases with grading score ≥ 4 and/or stage ≥ 2 , while HCV positive cases with grading score < 4 and stage < 2 were classified into chronic HCV infection with minimal histological lesions. Advanced histological lesions were considered to be present in cases with grading score ≥ 8 and/or stage ≥ 3 . In addition to grading score and stage, hepatic steatosis was also graded according to the percentage of hepatocytes containing fat droplets as no ($\leq 5\%$), mild (6-33% of hepatocytes affected), moderate (34%-66% of

hepatocytes affected) and severe steatosis (>66% of hepatocytes affected).

Statistical analysis

All data were analyzed using the statistical package SPSS (version 13.0, SPSS Inc., Chicago, IL). Results were expressed as mean values \pm [standard deviation (SD)] or as median values (range). Statistical analysis was performed using t-test or Mann-Whitney test for comparisons of continuous variables between groups, corrected chi-squared method or two-tailed Fisher's exact test for qualitative data and Spearman correlation for evaluation of relations between two quantitative variables, when appropriate. The accuracy of levels of CK-18 fragments for estimating the severity of liver diseases was evaluated through the area under the receiver operating characteristic (ROC) curve by the concordance (c)-statistic. Diagnostic accuracy was considered to be good in case of a c-statistic 0.71-0.80 and excellent in case of a c-statistic >0.80. Logistic or linear regression analysis was used for multivariate analysis with only variables with a P value \leq 0.10 at univariate analysis entering in the multivariate models. A two-tailed P value <0.05 was considered to be statistically significant.

RESULTS

According to the histological findings, among the 134 patients with chronic HCV infection, there were 28 (21%) with minimal histological lesions and 106 (79%) with histological evidence of chronic hepatitis C. The main characteristics of all patients are presented in Table 1. As expected, there were significant differences in several baseline characteristics between patients with chronic HCV infection and minimal histological lesions and those with chronic hepatitis C.

In all 134 patients with chronic HCV infection, the mean levels of CK-18 fragments were 274 ± 187 (98-1021) U/L being significantly lower in the 28 patients with minimal histological lesions than in the 106 patients with histological chronic hepatitis C [196 ± 71 (136-397) U/L vs 295 ± 202 (98-1021) U/L, $P < 0.001$] (Figure 1). The mean levels of CK-18 fragments were significantly lower in the 30 healthy controls [154 ± 31 (117-227) U/L] than in chronic HCV patients with minimal histological lesions ($P = 0.006$) (Figure 1). ROC curve analysis showed that levels of CK-18 fragments offered good diagnostic accuracy for differentiating chronic HCV patients with minimal

Table 1. Main characteristics of 134 patients with chronic hepatitis C virus (HCV) infection

Patient characteristic	Minimal histological lesions (N=28)	Chronic hepatitis C (N=106)
Age, years	39 \pm 11 ⁵	45 \pm 13 ⁵
Sex, males (%)	16 (57)	48 (45)
BMI, kg/m ²	25 \pm 4	25 \pm 4
ALT, IU/L	57 (17-177) ¹	71 (11-263) ¹
ALT \leq ULN*, n (%)	7 (25) ⁶	7 (7) ⁶
AST, IU/L	33 (20-64) ²	50 (13-179) ²
GGT, xULN	0.5 (0.2-3.2) ⁵	0.7 (0.2-4.7) ⁵
Cholesterol, mg/dL	187 \pm 46	175 \pm 40
Triglycerides, mg/dL	80 \pm 40	93 \pm 65
Hb, g/dL	13.9 \pm 1.5	14.0 \pm 1.7
WBC, x10 ³ /mm ³	7.3 \pm 2.6	7.0 \pm 2.3
Platelets, x10 ³ /mm ³	252 \pm 64 ⁵	215 \pm 72 ⁵
Diabetes, n (%)	0	7 (7)
Serum HCV RNA, x10 ³ IU/mL	376 (9-9812)	842 (34-3x10 ⁷)
Grading score	3.5 \pm 0.7 ^{2*}	6.7 \pm 1.8 ^{2*}
Stage	0.8 \pm 0.4 ^{2*}	2.8 \pm 1.4 ^{2*}
Cirrhosis, n (%)	0 ⁷	14 (13) ⁷
Steatosis, n/n (%)	3	3
No/Mild	14/11 (89)	17/53 (66)
Moderate/Severe	3/0 (11)	24/12 (34)

BMI: body mass index, ALT: alanine aminotransferase, ULN: upper limit of normal, AST: aspartate aminotransferase, GGT: gamma-glutamyl-transpeptidase, WBC: white blood cells; *Patients with persistently normal ALT activity.

¹P=0.002, ²P<0.001, ³P=0.001, ⁴P=0.07, ⁵P=0.02, ⁶P=0.01, ⁷P=0.04.

*Grading score and stage according to Ishak et al classification⁹.

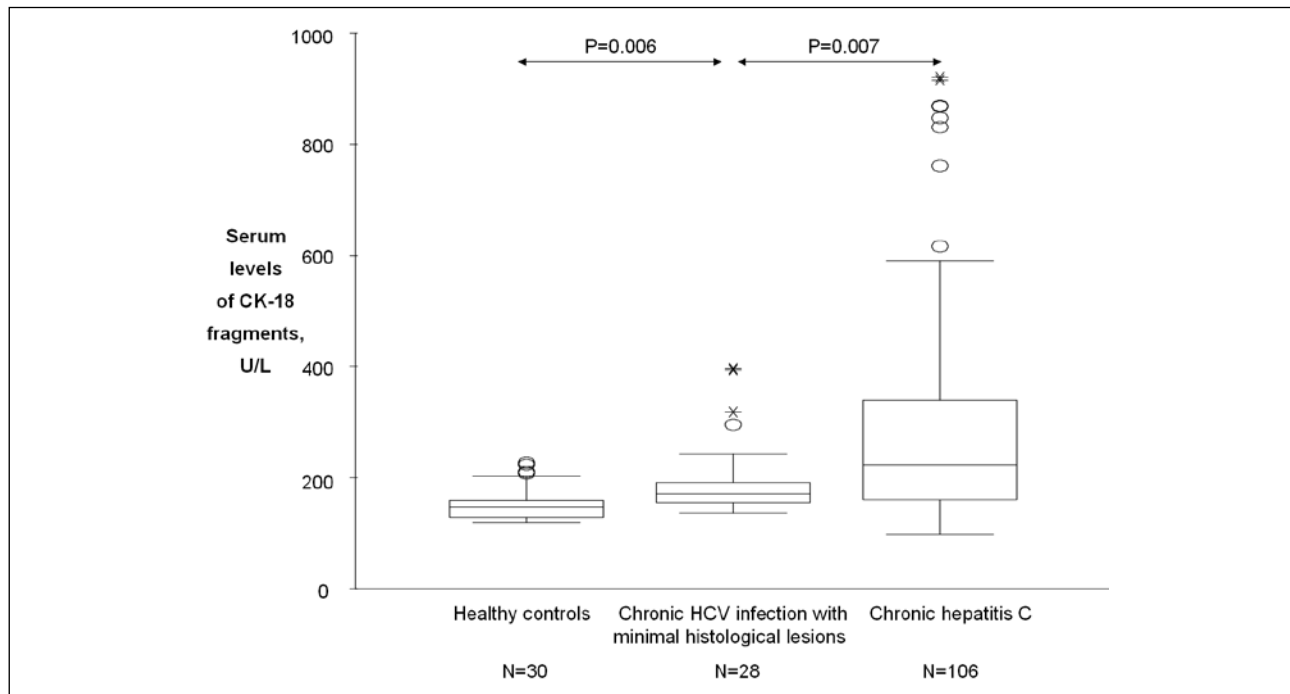


Figure 1. Serum levels of cytokeratin-18 (CK-18) fragments in 30 healthy controls and 134 patients with chronic hepatitis C virus (HCV) infection. Box and whiskers plots express medians, and interquartile and overall ranges. The outlying values are plotted individually.

histological lesions from healthy controls [c-statistic: 0.76 (95% CI: 0.64-0.88)] and moderate accuracy for differentiating chronic hepatitis C patients from chronic HCV patients with minimal histological lesions [c-statistic: 0.67 (95% CI: 0.56-0.77)] (Figure 2A). In particular among the 14 chronic HCV patients with persistently normal ALT and AST activity, levels of CK-18 fragments were relatively high (239 U/L) in 1 (14%) of the 7 patients with histological evidence of chronic hepatitis C and rather low (<180 U/L) in the remaining 13 cases.

Analysing all HCV positive patients together, levels of CK-18 fragments were found to significantly correlate with grading score ($r=0.38$, $P<0.001$), stage ($r=0.36$, $P<0.001$) and steatosis severity ($r=0.31$, $P<0.001$) and to be higher in stages 5-6 (412 ± 254 U/L) than stages 3-4 (324 ± 217 U/L) than stages 0-2 (229 ± 144 U/L) ($P<0.001$) as well as in moderate or severe steatosis (394 ± 251 U/L) than no or mild steatosis (225 ± 124 U/L) ($P<0.001$). ROC curves showed that levels of CK-18 fragments had moderate diagnostic accuracy for differentiating patients with grading score ≥ 4 (c-statistic: 0.67) or grading score ≥ 8 (c-statistic: 0.70) and better diagnostic accuracy for differentiating patients with stage ≥ 4 (c-statistic: 0.73), stage ≥ 5 (c-statistic: 0.76) or advanced histological lesions (c-statistic: 0.74) (Figure 2B). CK-18 fragments ≥ 225 U/L or ≥ 300 U/L had sensitivity of 67% or 42%, specificity of 77% or

87%, positive predictive value (PPV) of 70% or 74% and negative predictive value (NPV) of 74% or 65% for the diagnosis of advanced histology, respectively.

Serum levels of CK-18 fragments were generally higher in males than females (296 ± 184 vs 255 ± 189 U/L, $P=0.016$) and correlated positively with ALT ($r=0.69$, $P<0.001$), AST ($r=0.60$, $P<0.001$) and GGT values ($r=0.34$, $P<0.001$) and negatively with cholesterol levels ($r=-0.30$, $P=0.002$) and platelet counts ($r=-0.286$, $P=0.001$). There was no correlation between levels of CK-18 fragments and serum HCV RNA levels or HCV genotypes. The patients' characteristics in relation to presence of serum levels of CK-18 fragments ≥ 225 U/L and <225 U/L are shown in Table 2. Multivariate analysis showed that levels CK-18 fragments ≥ 225 U/L were independently associated with male sex (OR: 6.0, 95% CI: 1.5-23.2; $P=0.01$), higher ALT values (OR: 1.04, 95% CI: 1.01-1.6; $P=0.002$), higher grading score (OR: 1.5, 95% CI: 1.03-2.2, $P=0.035$) and presence of moderate or severe steatosis (OR: 4.6, 95% CI: 1.3-16.4; $P=0.02$).

DISCUSSION

Apoptosis, which represents the execution of a cell death program usually initiated by rather specific stimuli and leading to the orderly resorption and shrinkage of in-

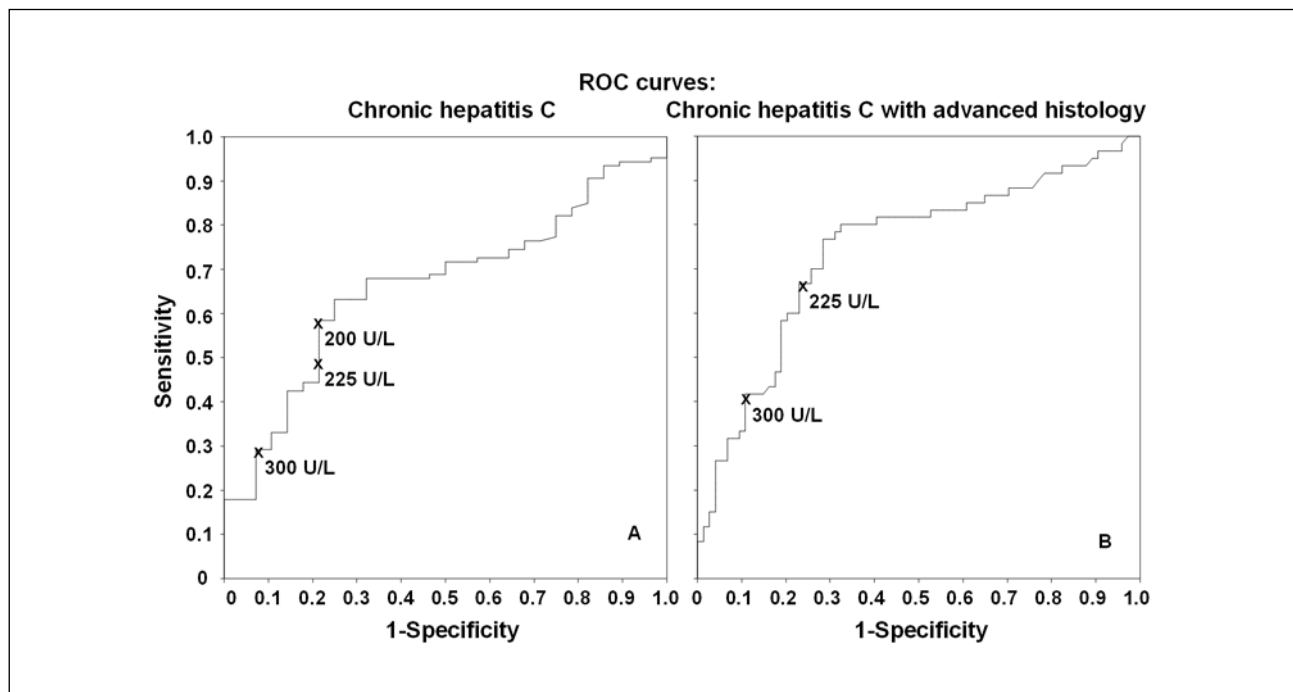


Figure 2. Receiver operating characteristic (ROC) curves of serum levels of cytokeratin-18 fragments with moderate diagnostic accuracy for prediction of chronic hepatitis C [c-statistic: 0.67 (95% CI: 0.56-0.77)] (A) and good diagnostic accuracy for prediction of advanced histological lesions (grading score ≥ 8 and/or stage ≥ 3) [c-statistic: 0.74 (95% CI: 0.66-0.83)] (B) among 134 patients with chronic hepatitis C virus infection.

dividual cells, is definitely an important cause of liver cell death in most cases of liver injury.^{3,10} The activation of a caspase cascade is a common process of apoptosis with the activated caspases cleaving aspartate residues of cell proteins.³ Detecting caspase-specific cleavage products of the hepatocyte protein CK-18, Bantel et al have shown that CK-18 cleavage is increased in liver biopsies of patients with several types of hepatobiliary diseases including chronic hepatitis C^{7,11} and that serum levels of CK-18 fragments determined by an enzyme-linked immunosorbent assay are increased in patients with chronic HCV infection compared to healthy controls.⁷ The same group also suggested that the serum levels of CK-18 fragments may be a more sensitive marker compared to aminotransferases for the detection of early liver injury in patients with chronic HCV infection,⁷ while Wieckowska et al recently reported that this test may be useful for differentiating NASH from simple fatty liver.⁸ Since the initial data by Bantel et al for a serum marker of hepatocyte apoptosis determined by a simple ELISA seemed to be extremely interesting,⁷ we evaluated the significance of serum levels of CK-18 fragments in patients with chronic HCV infection.

Apoptotic caspase activity was significantly associated with the severity of histological lesions in our patients

with chronic HCV infection, since serum levels of CK-18 fragments were found to be higher in patients with worse necroinflammation and/or worse fibrosis. This finding is in contrast with the report by Bantel et al,⁷ in which no significant correlation between the severity of histological lesions and the serum levels of CK-18 fragments was observed. Whether the smaller number of patients and/or the different index for evaluation of liver histology used in the latter study⁷ might be responsible for this discrepancy is unclear. We also tried to use the serum caspase activity for the diagnosis of patients with histological evidence of chronic hepatitis C, which could have implications on therapeutic indications. Levels of CK-18 fragments were indeed significantly higher in patients with chronic hepatitis C than in chronic HCV patients with minimal histological lesions, but the differentiation was moderate with an area under ROC curve of 0.67. The test was slightly better for the diagnosis of patients with advanced histological lesions with an area under ROC curve of 0.74. Similar accuracy of serum CK-18 fragments for the diagnosis of at least moderate fibrosis among 25 HCV positive patients with normal aminotransferases activity was reported in the study of Bantel et al.⁷ Thus, it was suggested that serum apoptotic caspase activity may be a useful marker

for diagnosing liver histological lesions in chronic HCV patients with normal aminotransferases.⁷ However, only 14% (1 of 7) of our HCV positive patients with normal ALT activity and histological evidence of chronic hepatitis had relatively high serum levels of CK-18 fragments and thus the significance of this test should be evaluated further in this setting.

An interesting observation in patients with chronic HCV infection was the strong and independent association of higher serum apoptotic caspase activity with more severe hepatic steatosis, which is in agreement with another previous report.¹² Such findings further support the reported association between hepatic steatosis and apoptosis in chronic hepatitis C¹³ as well as the activation of proapoptotic mechanisms by lipid accumulation in nonadipose tissues.^{14,15}

Serum CK-18 fragment levels were significantly higher in chronic HCV patients with minimal histological lesions than in healthy controls, but there were wide overlaps in the ranges (136-397 vs 119-227 U/L) which did not allow very accurate differentiations of such patients from healthy individuals (areas under ROC curve: 0.73-0.76). These findings are in agreement with previous reports.^{7,11} The higher serum CK-18 fragment levels in chronic HCV patients compared to healthy subjects might be associated with some degree of apoptotic injury, at least in some patients of these groups. However, it is currently unclear whether such elevated apoptotic markers may have any clinical significance and whether they might be predictors of progression of the liver disease. Moreover, a new marker that may differentiate healthy subjects from chronic HCV patients will not have clinical relevance, since such a differentiation can be easily made by the currently available routine HCV markers (usually anti-HCV).

In conclusion, serum apoptotic caspase activity is strongly associated with the severity of liver histological lesions in patients with chronic HCV infection. However, the assessment of serum levels of CK-18 fragments does not seem to offer high accuracy for the estimation of the severity of liver histological lesions in patients with chronic HCV infection, which might be associated with the rarity of true inactive carrier state among such cases.

REFERENCES

1. Dusheiko GM. The natural course of chronic hepatitis C: implications for clinical practice. *J Viral Hepat* 1998; 5 (Suppl. 1): 9-12.
2. National Institute of Health Consensus Development Conference Statement: Management of hepatitis C: 2002 - June 10-12, 2002. *Hepatology* 2002; 36 (Suppl. 1): S3-S20
3. Malhi H, Gores GJ, Lemasters JJ. Apoptosis and necrosis in the liver: a tale of two deaths? *Hepatology* 2006; 43: S31-S44
4. Van Eyken P, Desmet VJ. Cytokeratins and the liver. *Liver* 1993; 13: 113-22.
5. Ku NO, Liao J, Omary MB. Apoptosis generates stable fragments of human type I keratins. *J Biol Chem* 1997; 272: 33197-203.
6. Leers MPG, Kolgen W, Bjorklund V, et al. Immunohistochemical detection and mapping of a cytokeratin 18 neopeptide exposed during early apoptosis. *J Pathol* 1999; 187: 567-72.
7. Bantel H, Luger A, Heidemann J, et al. Detection of apoptotic caspase activation in sera from patients with chronic HCV infection is associated with fibrotic liver injury. *Hepatology* 2004; 40: 1078-87.
8. Wieckowska A, Zein NN, Yerian LM, et al. In vivo assessment of liver cell apoptosis as a novel biomarker of disease severity in nonalcoholic fatty liver disease. *Hepatology* 2006; 44: 27-33.
9. Ishak K, Baptista A, Bianchi L, et al. Histological grading and staging of chronic hepatitis. *J Hepatol* 1995; 22: 696-9.
10. Guicciardi ME, Gores GJ. Apoptosis: a mechanism of acute and chronic liver injury. *Gut* 2005; 54: 1024-33.
11. Bantel H, Ruck P, Gregor M, et al. Detection of elevated caspase activation and early apoptosis in liver diseases. *Eur J Cell Biol* 2001; 80: 230-9.
12. Seidel N, Volkmann X, Langer F, et al. The extent of liver steatosis in chronic hepatitis C virus infection is mirrored by caspase activity in serum. *Hepatology* 2005; 42: 113-20.
13. Walsh MJ, Vanags DM, Clouston AD, et al. Steatosis and liver cell apoptosis in chronic hepatitis C: a mechanism for increased liver injury. *Hepatology* 2004; 39: 1230-8.
14. Unger RH, Orci L. Lipoapoptosis: its mechanism and its diseases. *Biochim Biophys Acta* 2002; 1585: 202-12.
15. Feldstein AE, Werneburg NW, Canbay A, et al. Free fatty acids promote hepatic lipotoxicity by stimulating TNF- α expression via a lysosomal pathway. *Hepatology* 2004; 40: 185-94.