

Review

Endoscopic resection of colonic polyps – A review

D.Christodoulou^{1,2}, G. Kandel¹, E.V. Tsianos², N. Marcon¹

SUMMARY

Endoscopic polypectomy has become standard care for the treatment of colonic polyps. While about 90% of polyps are small in size and easy to resect, a small percentage of polyps are of large size (>2 cm) and broad base and endoscopic resection is a real challenge for the endoscopist. An appropriate technique for safe removal of these large colorectal polyps has been developed and includes submucosal injection of large amounts of normal saline with diluted epinephrine and piecemeal resection. We address the importance of adding a few drops of methylene blue in the submucosally injected fluid to enhance the margins of the lesion and increase the accuracy of resection. The success rate of polypectomy of large polyps is more than 90%, while up to 10% of patients may finally require surgical treatment due to malignancy or incomplete resection. Small pieces of the polyp that remain unresected at the margins during polypectomy can be destroyed by argon plasma coagulator. Immediate bleeding after polypectomy can usually be successfully treated with diluted epinephrine injection and placement of hemoclips or loops, while delayed bleeding is rare (1%). Perforation of the bowel using this technique is very rare (0.3%). In addition, all modern and new techniques for the resection of colorectal polyps are described. Colonoscopic polypectomy is con-

sidered among the high-risk procedures to induce significant bleeding, so, prior to polypectomy, adjustment in anticoagulation is necessary. For patients with high-risk conditions for a thromboembolic event, warfarin therapy should be discontinued 3 to 5 days before the procedure. The decision to administer heparin once INR falls below the therapeutic levels should be individualized. For elective high-risk procedures, temporary discontinuation of newer antiplatelet medications (such as clopidogrel), particularly if the patient is on concomitant aspirin, is desirable, preferably for 7-10 days. In the absence of a pre-existing bleeding disorder, endoscopic procedures including polypectomy may be performed in patients taking aspirin and other NSAIDs in standard doses. Antibiotic prophylaxis in patients undergoing polypectomy should be limited to patients with a prosthetic valve, history of endocarditis, presence of systemic-pulmonary shunt or a synthetic vascular graft less than 1 year old.

INTRODUCTION

The incidence of colorectal cancer is very high in North America and Europe. Polyps are found in up to 30% of patients over 60 years of age.^{1,2} The adenoma – carcinoma sequence is now well established.³⁻⁵ In addition, Japanese authors have described flat adenomas and small depressed lesions, the latter with high rate of submucosal invasion⁶⁻⁸, and these lesions have also been identified in western populations⁹. Much clinical and epidemiological evidence suggests that a timely colonoscopy and removal of colonic polyps may reduce the risk for cancer in the colon and rectum¹⁰. Medications such as sulindac that have some effect on the prevention of polyps in familial adenomatous polyposis syndromes, did not result in significant reduction of size of sporadic adenomatous polyps¹¹. Endoscopic procedures of the large bowel reduce the risk for developing colon and rectal cancer by 50-90%, their protective influence lasting 6 years.^{5,12-14} This fact has supported the removal of all adenomatous polyps detected at colonoscopy.

¹ Centre for Therapeutic Endoscopy and Endoscopic Oncology, St Michael's Hospital, University of Toronto, Toronto, Ontario, Canada, ²Hepato-Gastroenterology Unit and Therapeutic Endoscopy Unit, 1st Department of Internal Medicine, Medical School of Ioannina, Greece, Dr Christodoulou has received a grant – scholarship by the Greek Association of Gastroenterology for postgraduate training at St Michael's Hospital in Toronto.

Author for correspondence:

E.V. Tsianos, Professor of Internal Medicine, 1st Department of Internal Medicine, Medical School, University of Ioannina, Leoforos Panepistimiou, 451 00 Ioannina, Greece, Tel: 0030-26510-97501, Fax: 0030-26510-97016, e-mail: etsianos@cc.uoi.gr

Of course, not all polyps are neoplastic. An extended classification of all polyps is shown in **Table 1**.⁴ Neoplastic polyps, called in general adenomatous, are the ones with the potential for malignant transformation. Adenomatous polyps with villous pattern and size larger than 2cm have the highest malignant potential.¹⁵ While there is no controversy about the endoscopic follow-up of patients with adenomatous polyps, hyperplastic polyps are considered in general innocent. Despite that, some recent studies have suggested that hyperplastic polyps share some histochemical changes with colon cancer.^{16,17} It was also found in a study with limited number of patients that patients with hyperplastic polyps were 2.4 times more likely to have further adenomas than were those without polyps¹⁸.

Polypectomy with flexible instruments has been performed for the last 30 years. The removal of premalignant polyps has had an impact on the incidence, morbidity and mortality of colorectal cancer. The removal of colonic polyps is one of the major landmarks of progress in gastroenterology during the past 50 years. The technique of polypectomy has not changed much over the years, using the snare as the principal instrument for polypectomy, but newer options have become available, such as submucosal injection at the base of the polyp or argon plasma coagulation of remnant tissue, allowing for more advanced and technically difficult successful polypectomy. In fact, newer techniques such as resection of large flat lesions or endoscopic dissection have brought colonoscopic polypectomy to its limits and further attempts may increase the risks without improving the efficacy of the technique. Finally, the improvement of endoscopic accessories and electrosurgical generators permitted the performance of easier and safer polypectomy.

Nowadays, the standard method for the resection of colorectal polyps is snare polypectomy. The method is

easy to learn for an endoscopist with adequate experience in diagnostic colonoscopy and the results are excellent. It also gives the opportunity to retrieve the resected polyp to examine the adequacy of resection and the pathological features of the polyp. But while most polyps are easy to resect and retrieve, this is not the case for large sessile polyps or for polyps with a thick stalk. In these cases, adherence to strict guidelines in combination with skill and experience are required for safe and effective removal. In some particularly large and spreading polyps where several sessions could be anticipated, colon resection might be a better option. In addition, one must be able to deal with the complications that may take place, mainly bleeding. In this review, the local experience in endoscopic polypectomy of large polyps along with worldwide used techniques is presented.

Guidelines for polyp management and postpolypectomy follow-up

Before describing the techniques of resection of large polyps it is useful to present in brief the guidelines for treatment and follow-up of polyps according to the American College of Gastroenterology.¹⁹

First, all patients with polyps detected with flexible sigmoidoscopy or barium enema should undergo colonoscopy to the cecum to excise and remove all adenomatous polyps. If only one polyp with size smaller than 0.5cm is detected in flexible sigmoidoscopy, the decision to perform colonoscopy or not should be individualized according to the age of the patient, comorbidity, past or family history of colorectal cancer and the patient's preference.^{20,21} A hyperplastic polyp found during sigmoidoscopy is not by itself an indication for full colonoscopy.²²

Patients with sessile polyps larger than 2cm require careful follow-up after polypectomy to ensure complete resection. In these cases, the colonoscopy should be repeated in 3-6 months for 1-2 times. This is a safe interval being influenced by the histological report of the retrieved tissue. If complete resection is not possible after 2-3 examinations, the patient should be referred either for surgical resection or to a more experienced endoscopist.²³

For the patients that undergo successful polypectomy of single or only a few adenomas, the post-polypectomy surveillance colonoscopy should be in 3 years time and thereafter every 5 years if no more polyps are found. Selected patients with multiple adenomas or those who had a suboptimal clearing examination might require surveillance colonoscopy at 1 and 4 years. The presence of severe or high-grade dysplasia in a polyp does not modify per se the above recommendations.^{10,19-21} Endoscopic fol-

Table 1. Histologic classification of polyps⁴

Non-neoplastic polyps	Neoplastic polyps
Hamartomas	Adenomatous
Juvenile	Tubular adenoma
Peutz-Jeghers	Tubulovillous adenoma
Lipoma	Villous adenoma
Hyperplastic (metaplastic)	Flat adenoma
Postinflammatory	Mixed polyps (e.g. serrated adenomas)
Lymphoid	
Other (e.g. hemangiomas, neurofibromas, leiomyomas)	

low-up should be discontinued when it appears unlikely that the continued follow-up is capable of prolonging life expectancy. The discontinuation of surveillance depends on patient's understanding and medical history. If the patient is in good health, surveillance should be continued until the age of 80, but this can be further extended as life expectancy is rising. If the patient is well at the age of 80, screening can be continued probably up to the age of 90.

For the patients with polyps have mucosal cancer the strategy is different.²⁴ Endoscopic resection is considered adequate when the polyp is completely excised, retrieved and sent for pathology; the pathologist can evaluate exactly the depth of invasion, the degree of the differentiation and the completeness of resection of the carcinoma; the cancer is not poorly differentiated; there is no vascular or lymphatic involvement; and the margin of excision is not involved.^{19,25} There are some problems with pathologist determining complete excision and non-invasiveness when the polyp is delivered in many non-orientated pieces as is the case with piecemeal resection. This can be obviated when the polyp is resected en bloc in one piece by the new technique of endoscopic submucosal dissection (ESD).^{26,27}

According to the Japanese classification, the colorectal neoplasms are classified into polypoid (protruded type) and non-polypoid. Non-polypoid neoplasms are classified into slightly elevated type (flat adenoma), laterally spreading type and depressed type. The degree of submucosal invasion is classified into three types based on the depth of invasion^{6,8,28,29}. When less than one-third of the submucosa is invaded the stage is sm1; if more than two-thirds is invaded the stage is sm3. The stage sm2 is intermediate. Stage sm1 is subclassified into a, b, and c, according to the degree of horizontal extension of cancer into the submucosal layer (a: horizontal extent of cancer invasion in the mucosal layer, b: horizontal extent of cancer in the submucosal layer, c: horizontal extent of cancer in the mucosal and submucosal layer). This staging of submucosal invasion reflects the prognosis of the lesion. For example, an sm1b cancer without vessel invasion or an sm1a cancer never metastasizes but more extensive or deeper lesions have a possibility of metastasis. If evaluation of the resected specimen shows that the cancer has penetrated to sm2 or more, additional surgery with lymph node-dissection becomes necessary. Lateral spreading tumor is usually adenoma or mucosal cancer, which is also suitable for mucosal resection. The first endoscopic follow-up in patients with malignant polyps should be in three months and thereafter according to the criteria of follow-up for benign polyps.³⁰

Chromoendoscopy and narrow band imaging (NBI)

can assist in the recognition of superficial flat and depressed lesions, which are detected as small erosions or tiny deformities of the mucosal surface. Elevation of the lesion is clearly demonstrated by dye spraying. Indigo carmine solution is the most widely used dye. The character of the lesion is diagnosed by evaluating the pit pattern (especially with use of magnifying endoscope), or by histological assessment of the lesion. In clinical practice, endoscopists tend to resect the lesion if it is amenable to endoscopic therapy. The resected lesion is examined by the pathologist, and histological evaluation guides further therapeutic decisions or follow-up.³¹

Instruments and accessories for endoscopic polypectomy

A variety of instruments and accessories are used for colonoscopic polypectomy.³² It is a prerequisite for the endoscopist to be familiar with all the accessories, instruments and the electrosurgical unit to perform the procedure effectively and safely. A short description follows.

Snares

Several types of snares are available for polypectomy. Most of them are of oval or crescent shape, while hexagonal ones are less popular. The standard large snare is 6cm in length and 2-3cm in width and the standard small snare is 3cm in length and 1 cm in width. Both a large and a small snare should be available for a polypectomy and the decision which one to use when is based on the size, the shape and the location of a polyp. Snares with thinner wires tend to cut faster than those with a thick wire, so it is better for the endoscopist to be familiar with a certain type of snares for a controlled polypectomy. A special type of snare is the thorn-type snare, which can facilitate capture of a polyp that cannot be grasped with the regular snares. We prefer to use in most instances an oval-type snare with a needle-tip (large and small). The needle-shaped tip of the snare allows to test the snare or burn a very small lesion (like a monopolar probe, but take care, prolonged burning carries out a high risk of perforation) and to position the snare by gently hooking to the bowel wall. As snares do not easily maintain shape it is advisable to stretch for maximal width by grasping between fingers and pulling apart before each attempt.

Injection catheters

An injection catheter is a necessary component of polypectomy and should be always available. It can be used either to pre-inject the base of the polyp, as will be described, or to treat post-polypectomy bleeding, by injecting diluted epinephrine solution. Although a good injec-

tion catheter, with an adjustable length of needle, a short bevel of the needle and a rather stiff plastic sheath is desirable, care should be given to observe the result of the injection and to avoid injecting deeper than 1.5mm into the bowel wall (theoretical risk of extravasation, although complications do not occur by that). In most instances it is better to inject at an angle to reach the submucosal space, but again the crucial matter is to adjust the injection –needle by pushing in and out until the desirable lifting of the submucosal space occurs in each injected spot.

Electrosurgical unit

Many different trademarks of electrosurgical units are available. They all offer cutting current, coagulation current and a combination of them (blended or endocut current). A low to medium setting is preferred and coagulation or endocut current is used in most instances. Coagulation current offers better hemostasis, but also causes deeper burn into the bowel wall, so the decision of which current to use is case-dependent, unit-dependent and experience-dependent. Other experts use coagulation current, others endocut and others combine both of them, especially for large polyps (start with coagulation current and alternating the resection with endocut current; endocut current is an automated combination of coagulation and cut current to increase efficacy and safety, it provides better control than traditional blended current). Maintenance of the electrosurgical unit in good condition and testing it before polypectomy is of paramount importance. Usually a standard setting is used for most cases.

Detachable loops

The detachable snares or loops are nylon snares that can be placed tightly at the stalk of a pedunculated or semipedunculated polyp either to prevent or treat bleeding related to polypectomy. The nylon loop is attached a metal hook and the metal wire with the hook and the loop is withdrawn within a plastic sheath. The device is inserted through the biopsy channel of the colonoscope and the loop is opened by pulling back the plastic sheath. The loop is positioned around the stalk of the lesion near the intestinal wall and this may be difficult because the loop is very floppy. Then the plastic sheath is advanced again to tighten the loop. If the loop is in a good position, the sheath is gradually withdrawn while simultaneously the one-way silicone rubber stopper of the loop is tightened. The polyp is observed to change colour, because of strangulation of its stalk and then the loop is released from the plastic sheath and left in position. The loop is very useful to prevent bleeding after polypectomy of pedunculated polyps with a thick stalk. Although it is a little tricky to handle, its application is re-

warding and effective. The loop and carrier are manufactured by Olympus (HX-20) and the loop is available in two sizes (2.5cm and 4.0cm).³²⁻³⁴ Then conventional polypectomy is carried out, taking care not to remove the loop with the common snare. To avoid this, the snare should be placed at a distance from the loop. The loops slough spontaneously after 4-7 days, leaving behind shallow ulcers.

Clips

The clips or hemoclips are mainly used to treat post-polypectomy bleeding, either from flat or pedunculated lesions. They can also be applied at base of a stalk of a pedunculated polyp to strangulate the vessels of the stalk and allow safer polypectomy. In this case one should be cautious not to touch the clips with the snare, to avoid contralateral burns and diffusion of thermal energy. The clips can also be used as temporary markers everywhere in the gastrointestinal tract.

To load a clip, it is placed on the metal hook of the clipping device (Olympus) and then the hook is withdrawn in the metal wire. Then the metal wire is withdrawn into the plastic sheath and the device is ready to be inserted from the biopsy channel of the instrument. To deploy the clip, the metal wire is advanced through the plastic sheath first. Then the clip is loaded by bringing it closer to the end of the metal wire. The clip is positioned at the desired spot of the bowel wall (e.g. visible vessel). New clipping devices offer the possibility to rotate the clip for better positioning. Finally the clip is fired and released from the clipping device. More than one clips can be used to control bleeding. The clips tend to fall after some time, but can stay in place for a long time in some cases. A new clipping device has recently become available by Wilson-Cook, which is easy to use and is designed as a three arms clip.

Caps

The caps are plastic cylinders that can be attached at the tip of the colonoscope. There are available in various sizes and shapes (crescent-shaped, round, soft or stiff). They are used to suck flat lesions into the cap and thus capture them with the snare for polypectomy^{35,36}. Submucosal injection of normal saline is a prerequisite to use a cap to avoid involving the deeper layers of the bowel wall. The caps are used in our days for most endoscopic mucosal resection (EMR) cases of the upper gastrointestinal tract. In the lower gastrointestinal tract though, their use is less frequent and the reason is that the bowel walls are thinner than those of esophagus or stomach (so the risk of perforation is higher) and that most colonic lesions are not flat and can be captured with a snare. When used though, the piece sucked in the cap should be smaller than that sucked

in lesions of the upper gastrointestinal tract. Commercial kits for EMR with a cap are available by Olympus. This technique can be used especially in the rectum.

Endoscopes

A standard colonoscope, 168cm long with a biopsy channel of 3.8-4.2mm is used in most cases for colonoscopy and polypectomy. A variable stiffness pediatric colonoscope with a biopsy channel of 3.2mm may be helpful in cases with diverticular disease or fixed angles, while it is suitable for polypectomy. In some cases the endoscopist has to work partially with the scope in a retroflexed position, to remove a difficult polyp. In this cases a pediatric colonoscope, a gastroscope, a pediatric gastroscope or even a transnasal gastroscope (with a specific thin snare) can be used. In addition, in rare instances an oblique endoscope can facilitate the resection of a polyp located in a very difficult position, by allowing better visualization of the polyp and its margins.

A double channel colonoscope is somehow stiffer and less flexible, so intubation of the colon is more difficult. It can be used in cases where the endoscopist needs a second accessory to present the polyp to the snare at a favourable position.

On some occasions where intubation to the cecum is unsuccessful due to sigmoid looping in previous colonoscopies, the use of fluoroscopy with an overtube stiffening device will enable an easier intubation and success in total endoscopy.

Hot biopsy forceps (monopolar)

This is a special forceps that allows burning of the base of the polyp with electrical current while the small polyp is grasped by the biopsy forceps. The polyp should be lifted away from the bowel wall and current should be applied only for a short time, observing only the adjacent to the biopsy forceps tissue to become whitish from burning (Mount Fiji phenomenon)³⁷. Then the grasped polyp is cut and sent for pathologic evaluation. Coagulating forceps with monopolar current is the new way of coagulation of bleeding vessels.

Heater probe and Bipolar probe

These contact thermal devices have been used extensively in the past to treat postpolypectomy bleeding. The current power used at the lower gastrointestinal tract should be almost half of that used at the upper gastrointestinal tract and great force against the wall should be avoided.³⁸ Following these recommendations, the application of thermal devices in the bowel wall is safe, but many en-

doscopists in our days prefer the use of hemoclips or argon plasma coagulator to treat postpolypectomy bleeding.³²

Argon Plasma Coagulator

Argon Plasma Coagulator (APC) is a non-contact thermal device that delivers energy (ionized argon gas) to the bowel wall through a monopolar probe. The correct setting for the right colonic wall is 40W with a relatively low gas flow (0.8-2L/min) and the tip of the probe should be kept at a short distance from the wall but without touching it (to avoid deeper penetration of thermal energy). Using these precautions and the pulsed mode the penetration of thermal energy to the colonic tissue is limited. APC is used mainly to destroy remaining polypoid tissue after polypectomy, but it can also be used to treat postpolypectomy bleeding, usually in combination with clips.³⁹

When coagulating angiodysplasias in the cecum and right colon, a safety margin can be enhanced by a submucosal injection of saline prior to coagulation.

Submucosal injection solutions

The usual and cheapest solution used for submucosal injection is normal saline in volumes up to 30 or 40 cc depending on size of the sessile polyp. A few drops of methylene blue or indigo carmine are used to define the edges of the polyp and also the depth to allow the clear identification of the muscularis propria. The addition of dilute epinephrine is useful. Care must be used if large volumes of solution are injected that increases the systemic effect of the epinephrine and can lead to tachycardia and arrhythmia especially in elderly patients.

The limitation of submucosal saline injection is its speed diffusion. From Japan, newer solutions are becoming popular because of their longer duration of effect, especially when carrying out ESD with procedures lasting 2-3 hours. These solutions include hyaluronic acid, glycerol etc.⁴⁰⁻⁴²

Principles of endoscopic polypectomy

Before describing the technique for resection of large polyps, a general description of the principles of polypectomy will be made. First of all, the patient should be informed about the risks of polypectomy before the procedure and before giving sedation. It is preferable to have examined the entire colon before performing polypectomy. This for example obviates the need of removing a medium-size polyp if a large tumor is found at a close distance. On the contrary, if a very small polyp is found during insertion of the instrument, it is usually better to remove it immediately, because it is sometimes difficult to identify the polyp again when the instrument is withdrawn and the colon shortened.^{37,43}

Small polyps, usually of 0.5cm or less can be removed by biopsy forceps, in one or more pieces. This gives the additional advantage to remove a small polyp at a difficult position that is difficult to catch with the snare. Some polyps of this size or even larger can be destroyed by hot biopsy forceps. This technique involves holding the polyp with the biopsy forceps and retracting it from the intestinal wall, while applying current to destroy the adjacent tissue. Excessive burning should be avoided and the risk of perforation is slightly higher than that of the conventional snare polypectomy.⁴

All visible polypoid lesions of the colon should be removed. Small polyps have been found to be adenomas in 56% of cases, hyperplastic in 43% and of other type in 1%.⁴⁴ Resection of small polyps ($\leq 5\text{mm}$) with a snare is possible and can be done with or without application of thermal energy. Cold snare excision of small polyps ($\leq 5\text{mm}$) is safe and effective alternative method in patients without clotting problems. The slight bleeding following the cold snare excision of small polyps is usually not greater than that caused by a biopsy forceps and is almost always self-limiting after a few moments or easily treated with injection of diluted epinephrine around the wound or hemoclips if necessary. Besides, diathermic removal of these polyps by snare or hot biopsy forceps is not without risk, as there is a small but significant percentage of complications, such as perforation and serious delayed hemorrhage.

The principles of snare polypectomy include the following. The endoscopist should be familiar with the electrosurgical unit and should test the snare and the unit before polypectomy.³⁷ Stalks with up to 1.5cm in diameter can be removed in a single portion, but for stalks larger than 1 cm the endoscopist should preinject the base of the polyp (preinjection technique for snare polypectomy) or place an endoloop (detachable snare) as it will be described in detail in the next session.⁴ For large sessile polyps, piecemeal resection after preinjection technique is the safest approach.

In snare polypectomy, it is always better to position the polyp between 5 and 10 o'clock at the visual field, ideally at the 5-6 o'clock position and this is achieved by rotating the scope. The reason for this is that the biopsy channel of the instrument is located at the 5 o'clock position and so the snare will appear at the 5 o'clock position and progress diagonally at the 10 o'clock position of the field. The snare is advanced through the biopsy channel of the endoscope and is opened to grasp the polyp. Then it is slowly tightened to grasp the base or the stalk of the polyp and

this is facilitated by positioning the proximal end of the snare near the base of the polyp. Attention should be paid not to grasp folds of the bowel inside the snare because this will result in perforation. After the snare has grasped the polyp, the snare is moved in and out slowly to ensure that only the area of the polyp is moving and not the entire bowel wall, which would mean that more tissue is grasped and the risk of deep burning is high. Finally, when it is made certain that the snare was placed in a good position, the snare with the polyp is pulled from the adjacent wall (to avoid lateral burning) and current is applied in short bursts, while gradually the snare is further tightened. When the polyp is cut, the endoscopist should try to see where the polyp moves after polypectomy so that he can identify it and grasp it with the retrieval device.

If in doubt about the position of the snare on a polyp, it is always better to open the snare or reposition it. Only when a reasonable view is obtained and the snare is not trapping bowel wall but only the polyp, current is applied.

There is no limit in the number of polyps that can be removed in one session. If many polyps are found (>10), it is better to resect first those in the right colon, and then in a subsequent session the polyps in the left colon. If resection of a polyp is complicated with bleeding, after treating bleeding, it is sometimes better not to resect other polyps at the same session, but follow up the patient. In any case decisions are individualized according to the experience and preference of the endoscopist and no strict guidelines have been established regarding this matter.

Principles of removing large sessile and giant polyps

Large sessile polyps ($>2\text{cm}$), also called giant polyps if larger than 3cm, are a real challenge for the endoscopist. The decision about performing polypectomy or not should be based on certain criteria. First, the endoscopist must be experienced in polypectomy and adequate facilities for treating any complication should be available, preferably in a tertiary facility setting. Secondly, the endoscopist must have examined the whole colon before proceeding to polypectomy, to rule out any additional lesions that may require surgery. The view should be optimized by adequate flush of irrigation water to the polyp area and the polyp should be positioned at the lower part of the optical field, if possible. All the accessories for polypectomy should be available. Well-functioning electrosurgical unit, large and small-size snare, endoscopic injection catheters, retrieval baskets (Roth net), suction traps, clipping devices hemoclips and endoloops. Most of all, an experienced endos-

copy assistant or nurse is crucial to achieve a successful difficult polypectomy.

The endoscopist should spend some time to assess the polyp and set a plan for the polypectomy procedure. Then, the crucial part of the procedure starts and it is the pre-injection of normal saline at the base of the polyp. The addition of epinephrine 1:10,000-20,000 in the injected normal saline reduces the risk of bleeding during polypectomy and can keep clear the endoscopic field. Even if bleeding occurs, the rate is less and it is more easily controlled. The personal experience of our center has shown that the addition of a few (2-3) drops of methylene blue in the syringe with saline and diluted epinephrine is helpful because it enhances the definition margins of the polyp and demonstrates completeness of resection. A crucial step during submucosal injection of the polyp is to watch the polyp “being lifted” on its whole surface above the injected and enlarged submucosal space. (Figure 1) Failure of the polyp to lift after adequate submucosal injection of fluid (10-50cc) probably means that the polyp is invading the submucosal tissue and polypectomy should not be carried out. The submucosal injection, as it is known, should be started from the proximal part of the polyp and extended gradually to the whole circumference of the polyp. If a lesion is submucosal, it will disappear after submucosal injection technique, while if it is mucosal (e.g. polyp) it will be enhanced. This is a good rule to discriminate between mucosal and submucosal lesions and can lead the endoscopist to correct judgement about the nature of a colonic lesion. The submucosal injection of large amounts of normal saline (with diluted epinephrine and methylene-blue) provides a safety layer that permits

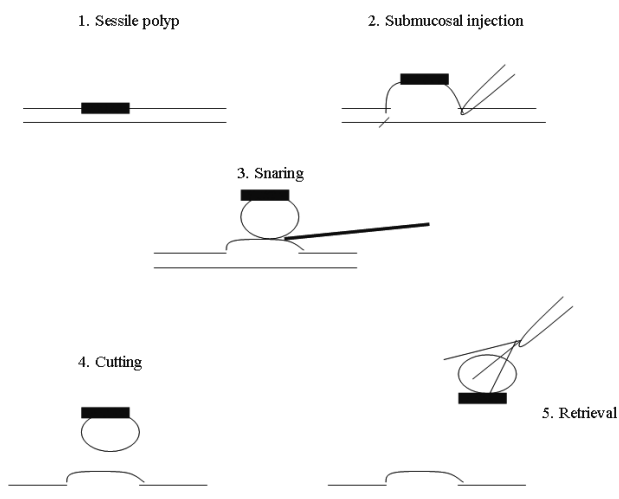


Figure 1. Example of a well lifted sessile polyp after submucosal injection and technique of polypectomy

polypectomy of large lesions. In a study by Iishi et al⁴⁵, it was shown that post-polypectomy ulcers after submucosal saline injection were confined to the submucosa in all cases, while 44% of post-polypectomy ulcers without submucosal saline injection reached the muscle layer or deeper. The same study suggested that submucosal saline injection reduced the chance of post-polypectomy bleeding because the injected fluid compressed the blood vessels while it had no adverse effect on the healing process.

After the submucosal injection has been carried out the endoscopist starts the resection process, which should be piecemeal in general. It is always safer to remove pieces of less than 1.5cm in size, to avoid trapping the muscle layer of the bowel wall or deeper in the snare. The snare is advanced into the visual field and the bowel wall to the polyp is touched momentarily with its tip while current is applied to check the electro-surgical unit. Then the snare is opened proximally to the polyp and then directed towards the polyp. Slight suction is applied to bring the polyp into the snare. After a good piece is caught, the snare is slightly tightened and the blended current is preferably applied (combination of coagulation and cutting current) at a low to medium setting. The procedure is continued until the whole base of the polyp is cleared and the underlying muscular layer can be seen with its characteristic blue colour, due to the injection of methylene blue stained solution. (Figures 2,3) Position change, flush with irrigation water, reforming the proper loop of the snare, re-injection with normal saline when necessary are all helpful to carry out a successful difficult polypectomy. Air insufflation should be kept at a minimum level to have a good view and the patient should be encouraged to pass gas and to give notice of bloating or discomfort.

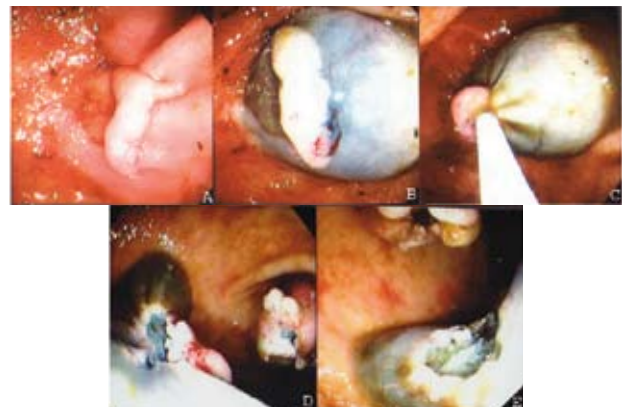


Figure 2. Endoscopic views of a piecemeal resection of a polyp after submucosal injection of normal saline with a few drops of methylene blue (A-E)

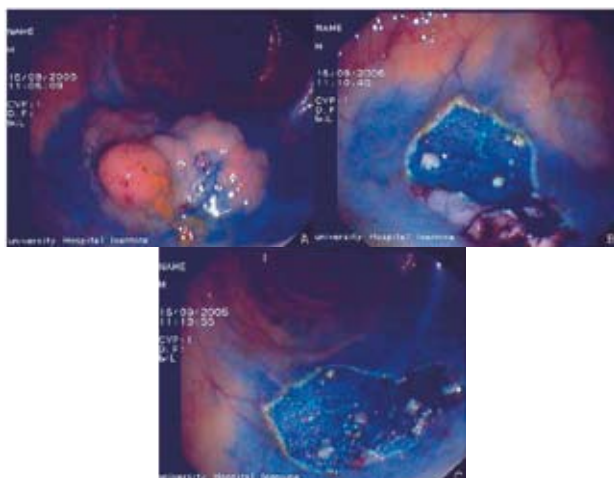


Figure 3. Another case of piecemeal polypectomy of a large sessile lesion after submucosal injection

After the pieces of the polyp have successfully been removed the retrieval process should be started and all the resected pieces should be collected for pathological evaluation if possible, depending on the location of the polyp and the number of resected pieces. For this purpose, the use of a specifically designed net basket, the Roth net is precious and can reduce the number of insertions of the scope for the retrieval of the polyp pieces.⁴⁶

After polypectomy of the large polyp and retrieval of the polyp pieces have been accomplished, the next step is to observe the site of polypectomy for any remaining small pieces of polypoid tissue. In case there are tiny pieces of the polyp left on the base that cannot be captured with a small snare, these pieces can be destroyed successfully with Argon Plasma Coagulation (APC) at a low setting (40 Watts at the right colon). Care should be given not to touch the tissue with the tip of APC probe during treatment as this increases the depth of destruction and to avoid applying APC at areas where the submucosal tissue is exposed after the polypectomy. This technique involves especially APC treatment of the margins of the resected polyp and any small residual pieces of the polyp. APC ablation of residual adenomatous polyp at the polypectomy base is safe and useful and enables to complete the eradication of large sessile polyps when there is visible evidence of residual polyp.^{47,48}

The final stage of polypectomy of a large sessile polyp includes observation of the polypectomy site for any signs of pending complication. Perforation can often be easily recognized. If not large, can be clipped closed. Most will usually require an operation. Transmural or serosal burn, caused by deep penetration of thermal energy into the bowel wall can cause localized inflammation, with pain, fever and localized peritoneal irritation. It can usually be

treated conservatively with bowel rest and prophylactic administration of antibiotics. Any bleeding point or any visible vessel should be treated by placement of hemoclips to reduce the risk of delayed post-polypectomy bleeding. (Figure 4) Lastly, close observation of the patient and follow-up endoscopy after 3-6 months should be in the plan to secure efficacy and safety of the procedure. (Figure 5)

For the easy localization of a site of a previous polypectomy, some markers for endoscopic tattooing can be used³². These markers are also widely used for identification of a colonic lesion or tumor during open or laparoscopic surgery.⁴⁹ The markers are injected into four quadrants so that the antimesenteric aspect of the colon can be stained for the surgeon, or into one-two sites very close to the polyp for postpolypectomy endoscopic localization. After injection of the marker, a dark bleb should be formed confirming presence of the marker in the submucosal space. To achieve this, the injection should be carried out tangentially to the bowel wall, adjusting the depth of insertion of the needle according to the result. Another trick, is to inject dye into submucosal bleb of saline. Two main markers are available. Ingocyanine green is an excellent marker for a short term localization only, because it is visible only for 7 days.⁵⁰ On the contrary, Indian ink is a permanent for life marker and gives the mucosa a characteristic black colour. Indian ink can rarely cause complications, such as tissue inflammation⁵¹, but dilution 1:100 minimizes this risk. An improved, sterile and diluted so-

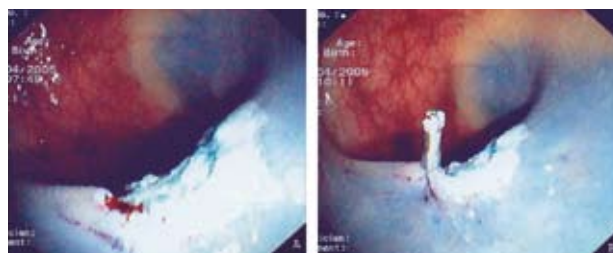


Figure 4. Prevention of delayed post-polypectomy bleeding by endoscopic placement of an hemoclip (A-B)

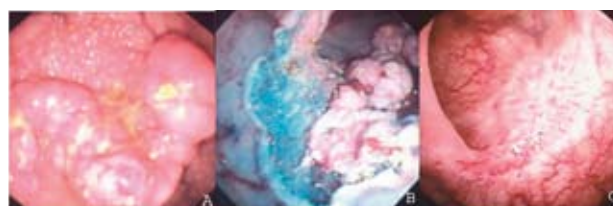


Figure 5. Regular follow-up post-polypectomy is necessary. In this case: complete healing 3 months after piecemeal resection of a large sessile polypoid lesion

lution of carbon particles in suspension is now available and ready to use in prepackaged syringes. It is FDA approved and ideal for short-term surgical marking. Endoscopic tattooing takes only a few minutes and it can save time for the endoscopist in future procedures.

There are also some additional advanced techniques that can be used for polyps that present unusual difficulty to the endoscopist. For large polyps at the cecum, ascending colon or rectum, the retroflexion of the endoscope can give a favorable position and resection of a large polyp, especially of the proximal to a fold part of it (clamshell polyp). In these occasions, the distal to the fold part of the polyp is removed with the tip of the instrument straight and if the proximal part cannot be well visualized after resection of the distal to the fold part, then the endoscope is advanced proximally to the polyp, retroflexed and then resection of the proximal part of the polyp is carried out in piecemeal fashion. As already mentioned, the submucosal injection of saline provides a safety layer for these difficult procedures and there is no alternative for the skill, experience and correct judgment of the endoscopist required. Care should be given to gently retroflex the tip of the instrument at the widest part of the lumen. A pediatric colonoscope can be helpful for retroflexion during difficult polypectomy. For polyps located at the rectum a regular gastroscope makes the procedure significantly easier.

In general, for large or difficult polyps located at the rectum or in a tortuous sigmoid colon the use of a standard gastroscope can be of help, because the gastroscope is thinner and more flexible, has a tighter bending ratio at the tip and is easier to manipulate. In some difficult cases an oblique endoscope, a pediatric gastroscope, or even a transnasal upper endoscope with specific thin snares can be used for polyps where extreme difficulty to snare is encountered.

Another specific problem that can be encountered are large rectal polyps involving the anal margin. In these cases endoscopic polypectomy can be performed, but the anal margin should be well infiltrated with local anesthetic and facilities to treat a complicating bleeding (clips, APC or other thermal device, diluted epinephrine) should be readily available. An alternative method is transanal endoscopic microsurgery, which is performed by a surgeon with the use of an operative proctoscope and special instruments. The method is effective, but should be reserved for cases that endoscopic removal was impossible or when extensive involvement of anal margin is present.⁵²

Another technique described for the resection of large polyps involves the laparoscopic-assisted colonoscopic polypectomy. In this method, after laparoscopic mobili-

zation of the involved section of the colon, the proximal colon is cross-clamped and the colonoscope is advanced to the involved portion of the colon. The polyp is then presented to the endoscopist by the laparoscopist facilitating removal. The serosal surface of the colon is monitored for any signs of transmural injury and the area is repaired if needed. The polyp undergoes immediate frozen section analysis and if pathologic evaluation indicates malignancy, then a segmental resection can be performed. As it is obvious, this technique should be reserved for selected cases or very large polyps and the option of pure surgery should be offered as an alternative.^{53,54}

En bloc dissection or endoscopic mucosal dissection (ESD)

ESD is a new Japanese endoscopic technique which is barely known to Western endoscopists. This technique removes in one piece sessile colonic lesions similar to Japanese experience for early stomach cancer. The main advantage is a well orientated and pinned out lesion for optimal pathological examination. The technique, because it can take 2-3 hours requires a long standing submucosal fluid. It also requires new endoscopic accessories. In this situation instead of using a snare the lesion is dissected off using cautery and cutting devices such as insulated needle knife, hook knife or flexi-knife. When this will be embraced by Western endoscopists is debatable, but hopefully in the next five years.^{26,27}

Principles of removing large pedunculated polyps with a thick stalk

Resection of large pedunculated polyps with a thick stalk represents a different task for the endoscopist. While conventional polypectomy with a single large diathermic snare can be carried out, there are additional techniques that can increase the efficacy and mainly the safety of the procedure.

Conventional polypectomy of large pedunculated polyps includes placement of the snare at the stalk, rather close to the head of the polyp and at some distance from the intestinal wall, to avoid full thickness injury from electrocoagulation. The snare is gradually tightened as coagulation current is applied. Usually the polyp is separated from the intestinal wall without any bleeding and the base of the stalk should be observed for any visible vessels that could cause delayed bleeding.

Currently, there are effective techniques that can add to the safety of the procedure. One simple but moderately effective technique is to pre-inject the base of the stalk with diluted epinephrine solution. This method simply com-

presses the blood vessels of the stalk and thus reduces the chance of bleeding. Even if bleeding occurs, the bleeding rate is less and the situation more controllable.

The most effective method to avoid bleeding from a polypectomy of a large pedunculated polyp is to place a specifically designed detachable snare (Endoloop) around the stalk of the polyp, near the intestinal wall.^{34,55} The detachable snare is actually an elliptical loop of heat-treated nylon thread with a silicone rubber stopper that maintains the tightness of the loop. After placement of the snare at the base of the stalk, the snare is gradually tightened and the polyp is observed for change of its color, caused by the strangulation of the blood vessels of the stalk. If the stalk is very large and long, one may place two loops. Excessive tightening may result in cutting the polyp without electrical cautery (guillotine) and this can result in severe bleeding. Finally, when the polyp is observed to become cyanotic the handle is detached with the snare in place. Then conventional polypectomy is carried out, paying attention to place the regular diathermic snare around the stalk closer to the head of the polyp at some distance from the detachable nylon snare, to prevent it from falling from the base of the stalk. This technique is much safer than conventional polypectomy when large pedunculated polyps with thick stalk are encountered. The technique can be combined with adrenaline injection at the base of the stalk.⁵⁶

The use of detachable snare is not always successful. The reasons for failure are insufficient tightening of the loop, transection of a thin (<5mm) stalk by the loop or slipping of the loop in a semipedunculated lesion.⁵⁷ With experience, patience and careful technique, these unsuccessful cases can be minimized. The nylon detachable snare can be used also post-polypectomy to prevent or manage bleeding from pedunculated polyps. In this case, the detachable snare is placed at the remaining part of stalk after polypectomy and it is tightened to strangulate the stalk and stop any occurring bleeding.

Some authors have used clips at the base of the stalk prior to polypectomy. In this case a small number of clips is placed near the base of the stalk, to achieve strangulation of the stalk blood vessels and then conventional polypectomy is carried out⁵⁸. The obstruction of blood flow at the base of the polyp protects from bleeding during and after polypectomy. Other authors, after ligating the polyp stalk with multiple clips, performed the polypectomy with a needle-knife papillotome.⁵⁹

Another technique used for the resection of large troublesome pedunculated polyps is the grasping forceps-assisted endoscopic resection of large pedunculated pol-

yps.⁶⁰ During this procedure, a two-channel endoscope with grasping forceps proved to be satisfactory for handling the detachable snare and the electrosurgical snare and for accurate recognition of the stalk under good visual control. This double-channel endoscopic polypectomy technique can be used effectively in the rare instance where the snare cannot be negotiated over the polyp using standard techniques⁶¹.

In general, polypectomy in the stomach follows the same principles described above. The wall of the stomach is thicker, permitting for a safer institution of interventional techniques, such as endoscopic mucosal dissection, endoscopic mucosal resection with a cap or with a ligation device. There is a tendency for gastric polyps to bleed more frequently after polypectomy, especially those with a thick stalk. Polypoid lesions in the stomach are frequently hyperplastic, while advanced endoscopic techniques are reserved for cases of early gastric cancer, which is more frequently recognized and treated endoscopically in Eastern Asia and Japan.

Polypectomy in patients receiving anticoagulation or antiplatelet therapy – Recommendations for antibiotic prophylaxis

Certain guidelines have been introduced by the American Society of Gastrointestinal Endoscopy (ASGE) on the management of anticoagulation and antiplatelet therapy for polypectomy and endoscopic procedures.⁶² Patients with low platelet count should not undergo polypectomy without prior platelet infusion. If there is underlying congenital or acquired deficiency of any of the coagulation factors, the patient may undergo polypectomy only after the achievement of therapeutic levels of the factor after exogenous administration. After polypectomy, the prophylactic placement of clips should be considered.

Endoscopic procedures vary in their potential to produce significant or uncontrolled bleeding and colonoscopic polypectomy is considered among the high-risk ones. So, prior to polypectomy, adjustment in anticoagulation is necessary. Low-risk conditions for thromboembolism include deep vein thrombosis, chronic or paroxysmal atrial fibrillation not associated with valvular heart disease, bioprosthetic valves and mechanical valve in the aortic position. For those patients with low-risk conditions for thromboembolism, warfarin therapy should be discontinued 4 to 7 days before the scheduled polypectomy. The decision to obtain a preprocedure prothrombin time should be individualized.

High-risk conditions for thromboembolism include atrial fibrillation associated with valvular heart disease,

mechanical valve in the mitral position and mechanical valves in patients who have suffered a previous thromboembolic event. For patients with high-risk conditions for a thromboembolic event, warfarin therapy should be discontinued 3 to 5 days before the procedure. The decision to administer heparin once INR falls below the therapeutic levels should be individualized⁶². Preliminary experience suggests there may be a role for a monitored reduction in the INR (1.5-2.5) without the use of heparin. Heparin, if used, should be discontinued 4 to 6 hours before the scheduled procedure and may be resumed 2 to 6 hours after the procedure. The administration of heparin usually requires hospitalization of the patient, but administering heparin subcutaneously, especially low molecular weight, appears to be an option, although no guidelines have been established. Warfarin therapy may generally be resumed the night of the procedure. Heparin infusion and warfarin therapy should overlap for a period of 4 to 5 days or until INR has achieved the target INR for 2 to 3 days.

Two new classes of anti-platelet agents include antagonists of the platelet cell surface adenosine diphosphate receptor (ticlopidine, clopidogrel) and antagonists of the glycoprotein IIb/IIIa receptor (eptifibatide, abciximab, tirofiban). The data on drugs affecting platelet function such as ticlopidine or dipyridamol are inadequate to make firm recommendations. For elective high-risk procedures, temporary discontinuation of these medications, particularly if the patient is on concomitant aspirin, is desirable, preferably for 7-10 days.⁶³

In the absence of a pre-existing bleeding disorder, endoscopic procedures including polypectomy may be performed in patients taking aspirin and other NSAIDs in standard doses (usual recommended therapeutic doses).⁶⁴ A study in a large number of patients showed that although the use of NSAIDs did increase the incidence of minor self-limited bleeding, an increase in the rate of major bleeding was not observed.⁶⁵ Another Japanese study showed that aspirin prolongs colon and skin bleeding time after experimentally induced incision of the mucosa, so endoscopists should be aware of a risk of abnormal bleeding after endoscopic biopsy and polypectomy in patients with aspirin use.⁶⁶ Two days were necessary for colon bleeding time to become normalized in patients with aspirin use. Despite these observations, a large study with 1657 patients who underwent polypectomy, showed that warfarin use was an independent risk factor for bleeding, while age, the location and size of polyp and the use of aspirin, NSAIDs or other antiplatelet drugs were not associated with a higher risk of polypectomy-associated bleeding.⁶⁷

Antibiotic prophylaxis

Antibiotic prophylaxis in patients undergoing polypectomy should be limited to patients with a prosthetic valve, history of endocarditis, presence of systemic-pulmonary shunt or a synthetic vascular graft less than 1 year old.⁶⁸ In most cases parenteral amoxicillin and gentamicin is recommended plus metronidazole for neutropenic patients. Vancomycin or teicoplanin replace amoxicillin in a case of allergy.

Complications and management of complications

Resection of large colonic polyps has in general a higher risk of complications than removal of smaller lesions. Having in mind the aforementioned techniques, this complication rate can be minimized. The two major complications of polypectomy are bleeding and perforation.^{4,69}

Perforation occurs in about 0.3% of patients undergoing polypectomy. It is due to full thickness injury of the bowel wall and can cause generalized peritonitis or localized postpolypectomy syndrome (localized perforation and serosal burn). The latter can be treated in many cases conservatively with bed rest, intravenous fluids, nil per mouth for a few days and broad-spectrum antibiotics. Peritonitis is an indication for surgery, and not recognizing this complication in time can result in significant morbidity and mortality. Endoscopic treatment of perforation, if obvious during the procedure, by placement of clips or detachable snare is usually unsuccessful and not tolerated by the patient.

Bleeding is a more common complication of polypectomy and occurs in approximately 1% of cases. It can be procedural, immediate within 24 hours or delayed (the most common) occurring between 24 hours and 14 days later. Procedural bleeding can be treated endoscopically in most cases with diluted epinephrine injection, placement of hemoclips or detachable snare. If the bleeding is severe, effort should be made to replace the snare on any residual stalk and strangulate it for 10-15 minutes. More rarely APC, heater probe or bipolar probe are used.

Intravenous pitressin or somatostatin, angiography and embolization of the bleeding vessel or even surgery may be required to handle severe bleeding that cannot be controlled endoscopically. To our experience but rarely used, in most cases procedural or immediate bleeding can be treated successfully endoscopically with the use of diluted epinephrine injection and hemoclips. Every endoscopist who performs polypectomy of large polyps should be familiar with these techniques of hemostasis.

Delayed bleeding can also be controlled endoscopically in many cases with the same techniques. In case there is a large amount of blood in the bowel, colonoscopy in flowing water or even flush of large amounts of water in the lumen can enable to identify the bleeding source.⁷⁰

The risk of post-polypectomy bleeding is higher in patients receiving anticoagulants, aspirin or other NSAIDs (they affect platelet function); patients with congenital and acquired platelet and coagulation disorders; those with sessile polyps > 2cm or those with a thick stalk >1cm.⁴ Cecal sessile polyps appear to bleed more commonly but this was not found statistically significant⁷¹. This location is thought to be at greater risk for hemorrhage, presumably because of its thinner wall and greater potential for coagulation injury to involve larger intramural vessels. Advanced age seems to be a predictive for transfusion requirement. In general, significant post-polypectomy bleeding develops most often in the elderly and within a median of 5 days after polypectomy. The outcome is generally excellent with only half of the patients requiring transfusion. Greater attention should be given to the removal of large sessile polyps and polyps located in the right colon.

DISCUSSION

Endoscopic resection of large polyps is a feasible and effective method of Therapeutic Endoscopy. Yokota et al⁷² removed a large number of sessile or semipedunculated lesions with this technique and had a high rate of complete removal (87%). Factors related to incomplete removal were size >2cm and large sessile-type configuration of the polyp. The complication rate was low (bleeding 0.4%, perforation 0.7%). Actually, as emphasized in this study, polypectomy assisted by submucosal saline injection represents an endoscopic mucosal resection technique.

Binmoeller et al⁷³ removed a large number (n=176) of giant polyps (>3cm). Of these lesions, 20% were tubular adenomas, 67% were tubulovillous and 13% were villous adenomas. Histology of the polyps showed coexistent malignancy in 12%. Sessile lesions were resected piecemeal and pedunculated ones transected at the stalk. They did not use extensive submucosal saline injection technique this time. Although their results were excellent, 24% of the cases were complicated by bleeding (during the procedure in most patients) but all cases of bleeding except one were treated successfully endoscopically. Eight of 176 polyps finally required surgery due to malignancy, while 1 of 7 malignant polyps with favorable criteria recurred and surgery was advised.

Iishi et al,³⁴ showed the importance of use of a detach-

able snare in patients with pedunculated polyps with a thick stalk (>1cm). In patients where a detachable snare was placed at the stalk of the polyp prior to polypectomy, no bleeding occurred during or after polypectomy, while 12% of patients where polypectomy was done without a detachable snare experienced bleeding. The limitations of the detachable snare have been described already but it seems that the most important factor in its success is the technique used during its placement.

The same authors⁷⁴ studied patients with sessile polyps 2cm or greater. The polyps were resected by the endoscopic submucosal saline injection technique described above. Of the 56 polyps 25% were resected en bloc and 75% piecemeal. Of the patients who underwent piecemeal resection 55% required additional endoscopic or surgical intervention and the final cure rate was high (83-100%). Arterial bleeding was seen in 4 patients and in all but one it was successfully treated by clipping (one patient underwent laparotomy).

As described above, treatment with APC probe of residual pieces of the large polyp can increase the efficacy of resection and reduce the recurrence rate.⁴⁷ In our experience, the use of a few drops of methylene blue in the submucosally injected fluid can enhance the view without any adverse effect. One should also not forget that the retrieval of the polyp is an essential part of the whole procedure.

Some authors have performed polypectomy with cutting current instead for the commonly used blend current (combination of cut and coagulation).⁷⁵ They had a bleeding rate of 1.1.% (66.1% immediate, 33.9% delayed) and had to place hemoclips in 12% of patients during the procedure. They concluded that use of pure cutting current is safe for polypectomy, provided hemoclips are available. In long thick stalks of pedunculated polyps, the pure coagulation current is the best option to achieve coagulation of the vessels of the stalk. Some experts first use coagulation current and then continue with mixed or cutting current during resection of the polyp.

And here comes the question: how far can the endoscopist can go?⁷⁶ Kanamori et al⁷⁷ injected large volumes of saline submucosally and performed a circumferential incision with a needle-knife a few millimeters from the lesion edge before removing the large polyp piecemeal by snare. Binmoeller et al⁷³ reported that up to 40% of their cases of large polyps required up to three sessions. The limits should be to help the patient without exposing him to unnecessary risks. Local experience and expertise is important and these procedures should be performed in centers

with surgical facilities and expert colorectal surgeons.

In conclusion endoscopic piecemeal resection with submucosal injection of saline, diluted epinephrine and a few drops of methylene blue is a safe and effective treatment for large, sessile colorectal polyps. An intensive follow-up program is necessary. Surgery is recommended for invasive malignant polyps.

REFERENCES

- Atkin WS, Morson B, Cuzick J. Long-term risk of colorectal cancer after excision of rectosigmoid adenomas. *N Engl J Med* 1992; 326:658-662.
- Papathodoridis GV, Kapranos N, Tzouvala M, Triantafyllou K, Elemenoglou I, Karamanolis DG. p53 and bcl-2 protein expression in rectosigmoid adenomas. *Am J Gastroenterol* 1998; 93:1136-1140.
- Bond JH. Interference with the adenoma-carcinoma sequence. *European Journal of Cancer* 1995; 31A(7-8):1115-1117.
- Williams CB, Talbot IC. Endoscopic managements of polyps. In: Sivac M, ed. *Gastroenterologic Endoscopy*. 2nd ed: W.B. Saunders Company, 1999: Chapter 85.
- Winawer SJ, Zauber AG, Ho MN, et al. Prevention of colorectal cancer by colonoscopic polypectomy. *N Engl J Med* 1993;329:1977-1981.
- Kudo S, Kashida H, Nakajima T, Tamura S, Nakajo K. Endoscopic diagnosis and treatment of early colorectal cancer. *World Journal of Surgery* 1997;21:694-701.
- Kudo S, Kashida H, Tamura T. Early colorectal cancer: flat or depressed type. *J Gastroenterol Hepatol* 2000; 15 Suppl: D66-70.
- Kudo S, Kashida H, Tamura T, et al. Colonoscopic diagnosis and management of nonpolypoid early colorectal cancer. *World J Surg* 2000; 24:1081-1090.
- Hart AR, Kudo S, Mackay EH, Mayberry JF, Atkin WS. Flat adenomas exist in asymptomatic people: important implications for colorectal cancer screening programmes. *Gut* 1998; 43:229-231.
- Bond JH. Follow-up after polypectomy: consensus? *European Journal of Cancer* 1995; 31A(7-8):1141-1144.
- Ladenheim J, Garcia G, Titzer D, et al. Effect of sulindac on sporadic colonic polyps. *Gastroenterology* 1995; 108:1083-1087.
- Muller AD, Sonnenberg A. Prevention of colorectal cancer by flexible endoscopy and polypectomy. *Ann Intern Med* 1995; 123:904-910.
- Winawer SJ, Zauber AG, Gerdes H, et al. Risk of colorectal cancer in the families of patients with adenomatous polyps. *N Engl J Med* 1996; 334:82-87.
- Citarda F, Tomaselli G, Capocaccia R, Barcherini S, Crespi M, Group TIMS. Efficacy in standard clinical practice of colonoscopic polypectomy in reducing colorectal cancer incidence. *Gut* 2001; 48:812-815.
- Hermanek P. Colorectal carcinoma: histopathological diagnosis and staging. *Baillieres Clinical Gastroenterology* 1989; 3:511-529.
- Jass JR, Filipe MI, Abbas S, Falcon CAJ, Wilson Y, Lovell D. A morphologic and histochemical study of metaplastic polyps of the colorectum. *Cancer* 1984; 53:510-515.
- Grondin MV, Chang WWL, Gaskins RD. Crypt alterations and collagen deposition in hyperplastic polyps of colorectum. *Dig Dis Sci* 1990; 35:12-19.
- Croizet O, Moreau J, Arany Y, Delvaux M, Rumeau JL, Escourrou J. Follow-up of patients with hyperplastic polyps of the large bowel. *Gastrointest Endosc* 1997; 46:119-123.
- Bond JH. Polyp guideline: diagnosis, treatment, and surveillance for patients with nonfamilial colorectal polyps. The Practice Parameters Committee of the American College of Gastroenterology. *Annals of Internal Medicine* 1993; 119:836-843.
- Winawer SJ, Zauber AG, O'Brien MJ, et al. Randomized comparison of surveillance intervals after colonoscopic removal of newly diagnosed adenomatous polyps. *N Engl J Med* 1993; 328:901-906.
- Fleischer DE, Goldberg SB, Browning TH, et al. Detection and surveillance of colorectal cancer. *JAMA* 1989; 261:580-585.
- Ransohoff DE, Lang CA, Kuo HS. Colonoscopic surveillance after polypectomy: considerations of cost-effectiveness. *Ann Intern Med* 1991; 114:177-182.
- Cohen LB, Wayne JD. Treatment of colonic polyps-practical considerations. *Clin Gastroenterol* 1986; 15:359-376.
- Wilcox GM, Beck JR. Early invasive cancer in adenomatous colonic polyps ("malignant polyps"). Evaluation of the therapeutic options by decision analysis. *Gastroenterology* 1987; 92:1159-1168.
- Cranley JP, Petras RE, Carey WD, Paradis K, Sivac MV. When is endoscopic polypectomy adequate therapy for colonic polyps containing invasive carcinoma? *Gastroenterology* 1986; 91:419-427.
- Yahagi N, Fujishiro M, Imagawa A, Kakushima N, Iguchi M, Omata M. Endoscopic submucosal dissection for the reliable en bloc resection of colorectal mucosal tumors. *Digestive Endoscopy* 2004; 16 (Suppl):S89-S92.
- Sano Y, Machida H, Fu KI, Ito H, Fujii T. Endoscopic mucosal resection and submucosal dissection method for large colorectal tumors. *Digestive Endoscopy* 2004; 2004(16 (Suppl)):S93-S96.
- Kudo S. Endoscopic mucosal resection of flat and depressed types of early colorectal cancer. *Endoscopy* 1993;25:455.
- Kudo S, Tamura S, Nakajima T, et al. Depressed type of colorectal cancer. *Endoscopy* 1995; 27:54.
- Coverlizza S, Risio M, Ferrari A, Fenoglio-Preiser CM, Rosini FP. Colorectal adenomas containing invasive carcinoma. Pathologic assessment of lymph node metastatic potential. *Cancer* 1989; 64:1937-1947.
- Inoue H, Kudo S. Endoscopic mucosal resection of gastrointestinal mucosal cancers. In: Classen M, Tytgat GNJ, Lightdale CJ, eds. *Gastroenterological Endoscopy*. Stuttgart - New York: Thieme, 2002: 302-321.
- Wayne JD. Colonoscopic Polypectomy. In: Classen M, Tytgat GNJ, Lightdale CJ, eds. *Gastroenterological Endoscopy*. 1st ed: Thieme, 2002: 302-321.

33. Rey JF, Marek TA. Endoloop in the prevention of the post-polypectomy bleeding: preliminary results. *Gastrointest Endosc* 1997; 46:387-389.
34. Iishi H, Tatsuta M, Narahara H, Iseki K, Sakai N. Endoscopic resection of large pedunculated colorectal polyps using a detachable snare. *Gastrointest Endosc* 1996; 44:594-597.
35. Inoue H, Kawano T, Tani M, Takeshita K, Iwai T. *Can J Gastroenterol* 1999; 13:477-480.
36. Inoue H. Endoscopic mucosal resection for the entire gastrointestinal mucosal lesions. *Gastrointest Endosc Clin N Am* 2001; 11:459-748.
37. Cotton P, Williams CB. Colonoscopic Polypectomy and Therapeutic Procedures. In: Cotton P, Williams CB, eds. *Practical Gastrointestinal Endoscopy*. 4th ed: Blackwell Science, 1996: 275-302.
38. Paspatis GA, Vardas E, Charoniti I, Papanikolaou N, Barbatzas C, Zois E. Bipolar electrocoagulation vs conventional monopolar hot biopsy forceps in the endoscopic treatment of diminutive rectal adenomas. *Colorectal Dis* 2005; 7:138-142.
39. Grund KE. Argon plasma coagulation (APC): ballyhoo or breakthrough? *Endoscopy* 1997; 29:196-198.
40. Fujishiro M, Yahagi N, Kashimura K, et al. Comparison of various submucosal injection solutions for maintaining mucosal elevation during endoscopic mucosal resection. *Endoscopy* 2004; 36:579-583.
41. Fujishiro M, Yahagi N, Kashimura K, et al. Different mixtures of sodium hyaluronate and their ability to create submucosal fluid cushions for endoscopic mucosal resection. *Endoscopy* 2004; 36:584-589.
42. Yeh RW, Triadafilopoulos G. Submucosal injection: safety cushion at what cost? *Gastrointest Endosc* 2005; 62:943-944.
43. Wayne JD. Colonoscopic polypectomy. In: Tytgat GNJ, Classen M, eds. *Practice of Therapeutic Endoscopy*. 1st ed: Churchill Livingstone, 1994: 193-223.
44. Tappero G, Gaia E, De Giuli P, Martini S, Gubetta L, Emanuelli G. Cold snare excision of small colorectal polyps. *Gastrointest Endosc* 1992; 38:310-313.
45. Iishi H, Tatsuta M, Kitamura S, Narahara H, Iseki K, Ishiguro S. Endoscopic resection of large sessile colorectal polyps using a submucosal saline injection technique. *Hepato-Gastroenterology* 1997; 44:698-702.
46. Miller K, Wayne JD. Polyp retrieval after colonoscopic polypectomy: use of Roth retrieval net. *Endoscopy* 2001; 54(4):505-507.
47. Ziatanic J, Wayne JD, Kim PS, Baiocco PJ, Gleim GW. Large sessile colorectal adenomas: use of argon plasma coagulator to supplement piecemeal snare polypectomy. *Gastrointest Endosc* 1999; 49:731-735.
48. Wahab PJ, Mulder CJJ, den Hartog G, Thies JE. Argon plasma coagulation in flexible gastrointestinal endoscopy: pilot experiences. *Endoscopy* 1997; 29:176-181.
49. Poulard JB, Shatz BA, Kodner I. Preoperative tattooing of polypectomy site. *Endoscopy* 1985; 17:84-85.
50. Price N, Gottfried MR, Clary E, et al. Safety and efficacy of India ink and indocyanine green as colonic tattooing agents. *Gastrointest Endosc* 2000; 51:438-442.
51. Gopal DV, Morava-Protzner I, Miller HAB, Hemphill DJ. Idiopathic inflammatory bowel disease associated with colonic tattooing with India ink preparation. *Gastrointest Endosc* 1999; 49:636-639.
52. Church JM. Polyp treatment. In: Church JM, ed. *Endoscopy of the colon, rectum and anus*: Igaku-Shoin Medical Publishers Inc., 1995: 156-178.
53. Franklin ME, Diaz-E JA, Abrego D, Parra-Davilla E, Glass JL. Laparoscopic-assisted colonoscopic polypectomy. *Dis Colon Rectum* 2000; 43:1246-1249.
54. Prohm P, Weber J, Bonner C. Laparoscopic-assisted colonoscopic polypectomy. *Dis Colon Rectum* 2001; 44:746-748.
55. Brandimarte G, Tursi A. Endoscopic snare excision of large pedunculated colorectal polyps: a new safe and effective technique. *Endoscopy* 2001; 33:854-857.
56. Paspatis GA, Paraskeva K, Theodoropoulou A, et al. A prospective, randomized comparison of adrenaline injection in combination with detachable snare versus adrenaline injection alone in the prevention of postpolypectomy bleeding in large colonic polyps. *Am J Gastroenterol* 2006; 101:2805-2809.
57. Matsushita M, Hajiro K, Takakuwa H, et al. Ineffective use of a detachable snare for colonoscopic polypectomy of large polyps. *Gastrointest Endosc* 1998; 47:496-499.
58. Iida Y, Miura S, Munemoto Y, et al. Endoscopic resection of large colorectal polyps using a clipping device. *Dis Colon Rectum* 1994; 37:179-180.
59. Cipolletta L, Bianco MA, Rotondano G, Catalano M, Prisco A, De Simone T. Endoclip-assisted resection of large pedunculated colon polyps. *Gastrointest Endosc* 1999; 50(3):405-407.
60. Akahoshi K, Kojima H, Fujimaru T, et al. Grasping forceps-assisted endoscopic resection of large pedunculated GI polypoid lesions. *Gastrointest Endosc* 1999; 50:95-98.
61. Valentine JF. Double-channel endoscopic polypectomy technique for the removal of large pedunculated polyps. *Gastrointest Endosc* 1998; 48:314-316.
62. Endoscopy ASfG. Guideline on the management of anticoagulation and antiplatelet therapy for endoscopic procedures. *Gastrointest Endosc* 2002; 55:775-779.
63. Hittlet A, Deviere J. Management of anticoagulants before and after endoscopy. *Can J Gastroenterol* 2003; 17:329-332.
64. Wayne JD. Colonoscopy 'my way': preparation, anticoagulants, antibiotics and sedation. *Can J Gastroenterol* 1999; 13:473-476.
65. Shiffman ML, Farrel MT, Yee YS. Risk of bleeding after endoscopic biopsy or polypectomy in patients taking aspirin or other NSAIDs. *Gastrointest Endosc* 1994; 40:458-462.
66. Nakajima H, Takami H, Yamagata K, Kariya K, Tamai Y, Nara H. Aspirin effects on colonic mucosal bleeding: implications for colonic biopsy and polypectomy. *Dis Colon Rectum* 1997; 40:1484-1488.
67. Hui AJ, Wong RM, Ching JY, Hung LC, Chung SC, Sung JJ. Risk of colonoscopic polypectomy bleeding with anticoagulants and antiplatelet agents: analysis of 1657 cases. *Gastrointest Endosc* 2004; 59:44.
68. Rey JR, Axon A, Budzynska A, Kruse A, Nowak A. Guide-

- lines of the European Society of Gastrointestinal Endoscopy (E.S.G.E.) antibiotic prophylaxis for gastrointestinal endoscopy. *European Society of Gastrointestinal Endoscopy. Endoscopy* 1998; 30:318-324.
69. Dafnis G, Ekbohm A, Pahiman L, Blomqvist P. Complications of diagnostic and therapeutic colonoscopy within a defined population in Sweden. *Gastrointest Endosc* 2001; 54:302-309.
70. Yamamoto H, Koiwai H, Sekine Y, et al. Colonoscopy in flowing water for lower GI bleeding: a reliable method for confirmation of bleeding points for endoscopic treatment. *Gastrointest Endosc* 2000; 52(5):678-681.
71. Sorbi D, Norton I, Conio M, Balm R, Zinsmeister A, Go-stout CJ. Postpolypectomy lower GI bleeding: descriptive analysis. *Gastrointest Endosc* 2000; 51:690-696.
72. Yokota T, Sugihara K, Yoshida S. Endoscopic mucosal resection for colorectal neoplastic lesions. *Dis Colon Rectum* 1994; 37:1108-1111.
73. Binmoeller KF, Bohnacker S, Seifert H, Thonke F, Valdeyar H, Soehendra N. Endoscopic snare excision of "giant" colorectal polyps. 1996 1996; 43:183-188.
74. Iishi H, Tatsuta M, Iseki K, et al. Endoscopic piecemeal resection with submucosal saline injection of large sessile colorectal polyps. *Gastrointest Endosc* 2000; 51:697-700.
75. Parra-Blanco A, Kaminaga N, Kojima T, Endo Y, Tajiri A, Fujita R. Colonoscopic polypectomy with cutting current: is it safe? *Gastrointest Endosc* 2000; 51:676-681.
76. Dorais J, Marcon N. Endoscopic resection of gastrointestinal tumors: how far can the endoscopist go? *Endoscopy* 1997; 29:192-195.
77. Kanamori T, Itoh M, Yokoyama V, Tsuchida K. Injection-incision assisted snare resection of large sessile colorectal polyps. *Gastrointest Endosc* 1996; 43:189-195.