

Endoscopic Quiz

Quiz

V. Balatsos

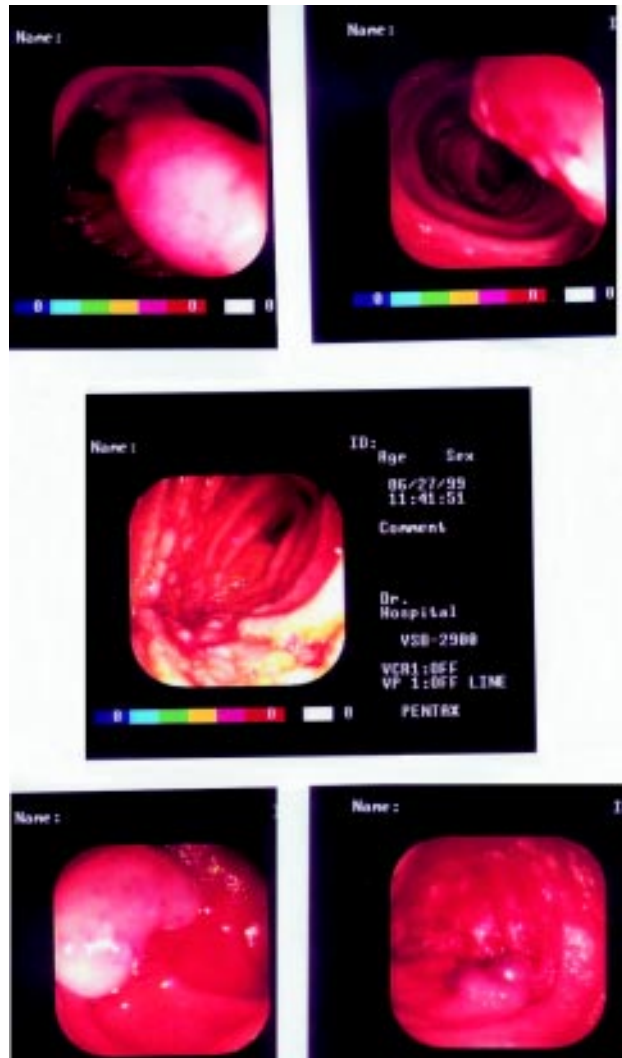
A) A 34 yr. old female patient readmitted to our Hospital presented with iron deficiency anaemia. X-rays and endoscopic studies (included colonoscopy and gastroscopy) performed during the first and the second admission were negative. She was, then, referred for push enteroscopy. A polypoid mass lesion 2 X 5cm with wide peduncle, friable with erosions was observed 25 cm below the ligament of Treitz. When the polypoid surface was pressed with the tip of a biopsy forceps, a "pillow sign" was observed. Which of the follow is correct:

- 1) Juvenile polyp;
- 2) Lipoma;
- 3) Inverted Diverticulum;
- 4) Lymphoma;
- 5) Do you perform polypectomy;

B) A 55 yr. old obese man was admitted to our Hospital for generalised purpuric rash. During his hospitalisation, he presented incomplete ileum, arthralgias, and melenas. Personal history: diabetes mellitus under treatment. Gastroscopy was unrevealing, but in colonoscopy 3 adenomatous polyps were found. A push enteroscopy was, then, performed. The lesions from the 4th part of the duodenum till 70 cm below the ligament of Treitz that are shown in the pictures below, are more probably compatible with:

- 1) Crohn's Disease;
- 2) Drug lesions;
- 3) Vasculitis;
- 4) Zollinger-Ellison's syndrome
- 5) Celiac sprue;

C) A 15 yr. old children has been referred to our Gastroenterology Dept. from another Hospital, being hospitalised for recurrent episodes of melenas, in order to perform push enteroscopy. The radiological and endoscopic examination of the upper and lower GI tract was unrevealing. The lesions that were in parts of the



small bowel observed and are shown in the pictures below, are more probably compatible with:

- 1) Peutz Jeghers syndrome;
- 2) Juvenile polyps;
- 3) Pseudopolyposis IBD
- 4) Blue Rubber Bleb Naevus Syndrome;
- 5) Familiar adenomatosis polypos

ANSWERS:

Case A.

2. The "pillow sign" after compression with the tip of a biopsy forceps is typical endoscopic finding of the lipoma. The mucosal biopsy is likely to be normal.

Case B.

3. The lesions of the picture are not typical to any of the above diseases. The history of the patient and the indication for the enteroscopy help to find out the diagnosis, that is in common histopathological.

Case C.

4. Angiomas of this type may be found in the colon, as well as in the skin and the small bowel. The probable bleeding source in 10% of cases with enteroscopy.