

Original article

## Capsule Endoscopy in the investigation of renal transplant recipients with chronic diarrhea

S. Karagiannis<sup>1</sup>, S. Goulas<sup>1</sup>, G. Kosmadakis<sup>2</sup>, Polyxeni Metaxaki<sup>3</sup>, P. Galanis<sup>1</sup>,  
A. Kantianis<sup>1</sup>, J.N. Boletis<sup>2</sup>, C. Mavrogiannis<sup>1</sup>

### SUMMARY

**Aim of the study:** Diarrhea is a common but mostly unexplained symptom in renal transplant recipients (RTRs). We used capsule endoscopy to investigate the small bowel of RTRs with chronic diarrhea and normal upper and lower tract endoscopy. **Patients and methods:** We prospectively enrolled RTRs with chronic diarrhea and non-immunocompromised patients with normal renal function and diarrhea (control group) that underwent capsule endoscopy. **Results:** Eighteen RTRs and 26 controls were included in the study. Findings were noted in 65.9% of the RTRs and in 19.2% of the controls. Findings considered as causative were detected in 33.3% of the RTRs and in 7.7% of the controls (Fisher's Exact Test  $\chi^2=4.701$ ,  $p<0.05$ ). Among RTRs, abnormalities included lymphangiectasia in 4 (3 of them exhibited laboratory findings compatible with protein-losing enteropathy), mucosal alterations compatible with mycophenolate mofetil toxicity in 2 and CMV enterocolitis in 1, while among controls, Crohn's enteritis in 1 and celiac disease in 1. Symptomatic improvement as a result of undertaken therapeutic measures was observed in all cases. **Conclusions:** Capsule endoscopy proved to be a helpful diagnostic tool in RTRs with chronic diarrhea. Aphthoid ulcers probably constitute the endoscopic image of mycophenolate mofetil toxicity on the small bowel.

**Key Words:** capsule endoscopy, chronic diarrhea, renal transplant recipients

### INTRODUCTION

Renal transplantation is the treatment of choice for the majority of patients with end-stage renal disease.<sup>1</sup> Postoperatively, immunosuppressive therapy plays a crucial role in maintaining a functional graft. During the last 20 years, clinical outcomes of renal transplantation treatment have remarkably improved, as a result of a more effective and safer immunosuppressive treatment that ensured excellent survival rates for both patients and grafts.<sup>2</sup>

However, treatment with immunosuppressive agents is frequently associated with gastrointestinal complications and diarrhea is a common and mostly unexplained symptom.<sup>3</sup> Although quite often diarrhea is caused by bacteria, there is a significant number of cases where no evidence of infection exists. In these cases, non-infectious diarrhea is considered to be a side effect of immunosuppressive therapy but the pathogenetic mechanisms remain unclear.<sup>4-6</sup> Non-infectious diarrhea in renal transplant recipients (RTRs) remains a real diagnostic and therapeutic challenge.<sup>7</sup>

Capsule endoscopy (CE) is a novel method of direct visualization of the small bowel (SB) that provides non-invasive examination of areas of the gut that are not accessible by conventional endoscopy.<sup>8</sup> It can be used as an outpatient procedure and it can detect even small lesions or alterations of the intestinal mucosa. As a consequence, the diagnostic yield of CE has been proved significantly higher of any other endoscopic or imaging modality of the SB, including gastroscopy, colonoscopy, push enteroscopy, small bowel follow through, computed tomography and angiography.<sup>9</sup>

<sup>1</sup>Department of Gastroenterology, Faculty of Nursing, Athens University, General Hospital of Athens "Helena Venizelou", Greece, <sup>2</sup>Department of Nephrology and Transplantation Center, Laiko General Hospital, Athens, Greece, <sup>3</sup>Department of Nephrology, A. Fleming General Hospital, Athens, Greece

#### Author for correspondence:

Stephanos S. Karagiannis, M.D., Nestoros 21A, Neo Iraklio Attikis, 141 21 Athens, Greece, Tel: +30 210 6427379, Fax: +30 210 6400500, E-mail address: [stkaragiannis@yahoo.gr](mailto:stkaragiannis@yahoo.gr)

Data on SB pathology in RTRs with chronic diarrhea are limited. In view of the scarcity of information we used CE to explore the entire SB in RTRs with stable renal function and diarrhea. To our knowledge, this is the first published endoscopic study in this topic.

## PATIENTS AND METHODS

This prospective study was conducted from May 2004 until December 2006, and included consecutive RTRs with stable renal function and chronic afebrile diarrhea who were referred to our institution for SB investigation. Chronic diarrhea was defined as watery and unformed stools lasting for at least 3 weeks, 2 to 5 times daily, with no fever. All patients had been initially investigated with esophagogastroduodenoscopy (EGD) and colonoscopy in other institutions and, if negative or non-diagnostic, were subsequently referred for CE. Consecutive non-immunocompromised patients with normal renal function investigated for chronic diarrhea with CE during the same period were used as control group.

Contraindications for the CE procedure were the generally accepted.<sup>8</sup> Written informed consent was obtained in all cases. Patients' clinical characteristics, including sex, age, time since transplantation and etiology of renal failure were recorded. Biochemical tests of renal function (creatinine clearance), albumin, cholesterol, and white blood cell count were also obtained.

### CE Procedure

For patients' preparation a 2-liter solution of polyethylene glycol was given the day before the procedure. All patients ingested the capsule endoscope (M2A; Given Imaging, Ltd., Yoqneam, Israel) after an overnight fast. The data recorder was disconnected after 9 hours and images were downloaded.

## Interpretation of CE Results

A single gastroenterologist initially screened all videos and selected images of potential abnormalities. Then, two experienced in interpreting CE gastroenterologists independently reviewed the selected images. All videos were extensively discussed and findings identified by both reviewers were considered as definitive and included in the report. The procedure was defined as incomplete if the capsule failed to pass into the cecum during the 9-hour duration of the examination. CE findings such as erosions or aphthoid ulcers of the SB mucosa, in the absence of NSAID's or aspirin consumption, were considered as compatible with MMF toxicity, based on the study of Maes et al.<sup>10</sup> The diagnostic yield of CE was calculated for both groups of patients.

### Statistics

The Statistical Package for Social Sciences (SPSS) program, version 13.0 (Chicago, Illinois) was used for statistical analysis. Continuous data with normal distribution are summarized as mean  $\pm$  standard error of mean, while those without as median (range). Differences between groups were evaluated by the  $\chi^2$  test or Fisher's exact test for qualitative variables. The Student t-test was used to compare quantitative variables. A p-value of less than 0.05 was considered statistically significant.

## RESULTS

A total of 17 RTRs and 26 controls fulfilled the inclusion criteria during the study period. Demographic and clinical characteristics of each group are shown in Table 1. Immunosuppressive treatment among RTRs consisted of mycophenolate mofetil (MMF) and prednisone in combination with cyclosporine (11 patients), or tacrolimus (7 patients).

All patients completed the procedure uneventfully. No case of capsule retention was observed. Complete visual-

**Table 1.** Patients' demographic and clinical characteristics

	RTRs	Controls	Statistics
No of patients	18	26	
Male/female	11/7	12/14	$\chi^2 = 0.95$ , p = NS
Mean age ( $\pm$ SEM), years	44.4 $\pm$ 3.1	48.5 $\pm$ 3.2	t = -0.91, dF = 42, p = NS
Mean creatinine clearance ( $\pm$ SEM), ml/min	41.3 $\pm$ 3.8	89.2 $\pm$ 2.2	t = -11.76, dF = 42, p = 0.000
Mean post-transplantation period ( $\pm$ SEM), months	74.1 $\pm$ 12.2	N/A	
Aetiology of renal failure, n		N/A	
Glomerulonephritis	6		
Nephrosclerosis	2		
Diabetic nephropathy	1		
Chronic pyelonephritis	1		
Other aetiologies	2		
Unknown	6		

ization of the SB was achieved in 16/18 (88.9%) RTRs and in 24/26 (92.3%) controls. In 4 (9.1%) patients, the capsule did not reach the colon, and, therefore, the entire SB was not imaged. Causes of failure of the capsule to reach the colon within the recording time were: presence of food impairing capsule progression in 1, and no clear reason in 3 patients. Gastric emptying time ranged from 4 to 222 minutes (median: 41.0) in RTRs and from 1 to 167 (median: 26.5) in controls. SB transit time was  $289.2 \pm 24.3$  and  $236.0 \pm 17.1$  minutes in RTRs and controls respectively.

CE findings of SB are listed in Table 2. All but 6 RTRs (66.7%) presented with some gastrointestinal abnormalities. Among controls abnormal findings were present in 5 (19.2%).

Non-specific and non-diagnostic findings compatible with extensive SB inflammation, such as erythema plus edema, were recognized in 3/18 (16.7%) RTRs and in 3/26 (11.5%) controls ( $\chi^2 = 0.24$ ,  $p = 0.68$ ). Multiple aphthoid ulcers (Fig. 1) were identified only in RTRs (2 patients), of whom none reported history of NSAID's or aspirin consumption. Those findings were characterized as compatible with MMF toxicity.

Erythema, edema and submucosal bleeding in the distal ileum (Fig. 2A) as well as erosions and aphthoid ulcers in the right colon (Fig. 2B) were present in one RTR. Tissue diagnosis of cytomegalovirus (CMV) enterocolitis was subsequently made by means of a new ileocolonoscopy and biopsies; preceded colonoscopy had been reported as normal.

Lymphangiectasia, in a pattern of continuous involvement was identified in 4/18 (22.2%) RTRs and in none of the controls. Endoscopically, lymphangiectasia was characterized by a large group of villi with whitened tips (Fig. 3). In 3 of them lesions involved only the jejunum while in

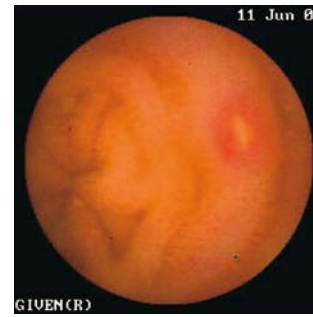

Fig. 1. Aphthoid ulcer in the jejunum compatible with MMF toxicity

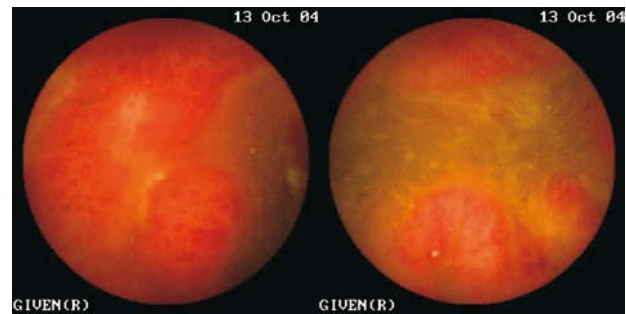


Fig. 2A. Erythema, edema, erosions and submucosal bleeding in the distal ileum (CMV enterocolitis) B. Erosions and aphthoid ulcers in the right colon (CMV enterocolitis)

the other 1 both the jejunum and ileum. Three out of these 4 patients exhibited laboratory findings compatible with protein-losing enteropathy (PLE). Laboratory values were: normal 24-hour urinary protein with low serum albumin (mean: 2.5 g/dl), low lymphocyte count (mean:  $890/\text{mm}^3$ ) and low serum cholesterol (mean: 138 mg/dl).

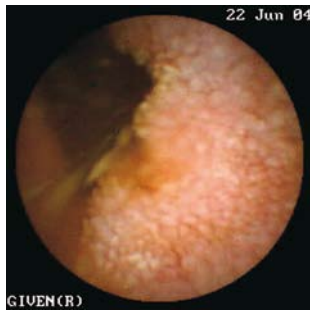White spots, covering large areas of intestinal mucosa and probably reflecting focally dilated lymphatic vessels, were identified in 1/18 (5.6%) RTRs (Fig. 4) and they were extending in the duodenum and the proximal jejunum. A new EGD with biopsy was performed and histologic examination showed dilated lymphatic vessels.

Edematous appearance of intestinal mucosa (Fig. 5) in the whole length of SB was found in 1/18 (5.6%) RTRs. Ulceration with cobblestoning and stricturing (Fig. 6) suggestive of Crohn's disease was identified in 1 of the controls and scalloping, as an endoscopic marker of villous atrophy (Fig. 7) suggestive of celiac disease, in another one.

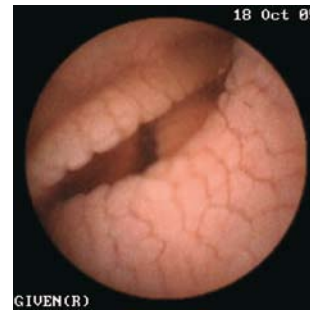The diagnostic yield of CE in RTRs was 33.3% (6/18) and 7.7% (2/26) in the controls (1 case of Crohn's disease and 1 case of celiac disease) – Fisher's Exact Test  $\chi^2 = 4.701$ ,  $p < 0.05$ .

Table 2. SB findings by CE

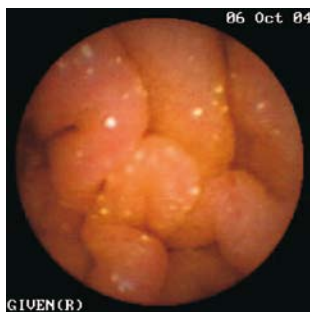Findings	RTRs (n = 18)	Controls (n = 26)
Jejunal and ileal inflammatory lesions (edema + erythema)	3	3
Erythema, edema, erosions and submucosal bleeding	1	-
Multiple aphthoid ulcers	2	-
Lymphangiectasia	4	-
White spots	1	-
Edema	1	-
Ulceration with cobblestoning and stricturing	-	1
Scalloping and villous atrophy	-	1
No findings	6	21



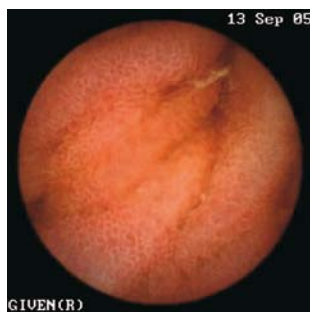**Fig. 3.** Lymphangiectasia in the jejunum in a patient with laboratory findings compatible with protein-losing enteropathy



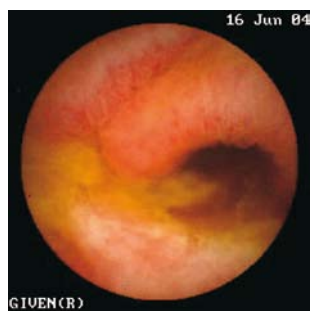**Fig. 7.** Scalloping, as an endoscopic marker of villous atrophy, suggestive of celiac disease



**Fig. 4.** White spots in the distal duodenum



**Fig. 5.** Edematous appearance of intestinal mucosa in the whole length of SB of a RTR



**Fig. 6.** Ulceration with cobblestoning and stricturing suggestive of Crohn's disease

Following CE, therapeutic measures were undertaken in 6/18 RTRs and in 2/26 controls. Pharmacotherapy was provided in the patient with CMV enterocolitis and in the one with Crohn's disease. The dose of MMF was decreased in RTRs with the MMF enteritis, resulting in cessation of diarrhea. A low-fat diet, enriched with medium-chain triglycerides was suggested to RTRs with lymphangiectasia and PLE. Clinical and laboratory improvement followed. In the patient with celiac disease, a gluten-free diet was suggested resulting in symptomatic improvement.

## DISCUSSION

Diarrhea is a common symptom in RTRs receiving immunosuppressive treatment but the etiology and the exact pathogenesis of this symptom remain unclear. The most commonly used drugs in RTRs are MMF, tacrolimus, cyclosporine sirolimus, and cortisone. Diarrhea is widely accepted as a side effect of MMF<sup>4</sup> and tacrolimus<sup>6</sup> and more rarely of sirolimus.<sup>5</sup>

In one study, among 41 cases of diarrhea in RTRs, 41.4% of them proved to be of infectious origin while 34% were attributed to drug toxicity.<sup>11</sup> In another study, among 26 RTRs with persistent afebrile diarrhea, 60% of cases were of infectious origin while 40% were attributed to MMF toxicity.<sup>10</sup> Among RTRs with diarrhea secondary to MMF toxicity, endoscopy revealed findings of erosive enterocolitis and histology showed abnormalities of a Crohn's disease-like pattern.<sup>10</sup>

Our findings confirmed those of Maes et al,<sup>10</sup> and small bowel aphthoid ulcers were the endoscopic findings in RTRs on MMF treatment presenting with diarrhea. Although in our cases macroscopic signs of colitis were absent, enteritis was prominent. Aphthoid ulcers probably constitute the endoscopic image of MMF toxicity on the small bowel but further studies in a larger group of patients are necessary.

Disorders of the intestinal lymphatic transport system are rare and typically associated with PLE.<sup>12</sup> Surprisingly, CE detected lymphangiectasia in 4/18 (22.2%) patients. This non-specific finding may represent a manifestation of various pathological entities or may be an incidental finding without clinical significance. The 3 RTRs with lymphangiectasia had laboratory findings compatible with PLE although nuclear medicine studies were not available. PLE diagnosis was further confirmed by the clinical and laboratory improvement, which followed the low-fat diet, enriched with medium-chain triglycerides. The role of CE in the diagnostic investigation of PLE has not been studied and only a few case reports, in abstract form, are available till today.<sup>13-15</sup>

CMV infection occurs in a large proportion of transplant recipients and is the most common viral cause of clinical disorders in these patients.<sup>3</sup> In immunocompetent individuals, CMV infection usually remains unrecognized (subclinical) but recovery is followed by persistence of the virus in a latent state. Re-activation occurs with immunosuppression following HIV infection, allogeneic bone marrow transplantation, solid organ transplantation or less commonly antineoplastic chemotherapy.<sup>16</sup> In 5% of RTRs CMV infection can affect the gastrointestinal tract at any level from the oropharynx to the anus.<sup>17</sup> In our case, CMV enterocolitis was diagnosed by CE and was confirmed by typical histological and immunohistochemical findings in intestinal biopsies and PCR-based technologies.

Our endoscopic findings possibly compatible with extensive SB inflammation, such as erythema plus edema, with or without erosions proved to be non-diagnostic and were recognized in the same frequency in both RTRs and general population. White spots and edema found in the SB of RTRs were also considered as non-specific.

Among not immunocompromised patients with normal renal function with diarrhea, SB findings that could be considered as causative were detected in 7.7% of cases, a percentage similar to what is reported by others.<sup>18-21</sup> On the other hand the diagnostic yield of CE in RTRs with diarrhea was significantly higher. It should be noted that in all cases the therapeutic yield was equal to the diagnostic yield and symptoms improved in all cases.

In summary, despite the limited number of our patients, CE proved to be a helpful tool in the investigation of RTRs with diarrhea, with a significantly higher diagnostic yield than in general population with diarrhea. Final diagnosis in these cases included PLE, MMF toxicity and infections of gastrointestinal tract. Aphthoid ulcers prob-

ably constitute the endoscopic findings of MMF toxicity on the small bowel.

## REFERENCES

1. Levey AS, Coresh J, Balk E et al. National Kidney Foundation practice guidelines for chronic kidney disease: evaluation, classification, and stratification. *Ann Intern Med* 2003; 139: 137-147
2. US Renal Data System: USRDS 2004 Annual Data Report. National Institutes of Health, National Institute of Diabetes and Digestive and Kidney Diseases, Bethesda, Maryland. www.usrds.org
3. Helderman JH, Goral S. Gastrointestinal complications of transplant immunosuppression. *J Am Soc Nephrol* 2002; 13: 277-287
4. Gonwa TA. Mycophenolate mofetil for maintenance therapy in kidney transplantation. *Clin Transplant* 1996; 10: 128-130
5. Vasquez EM. Sirolimus: a new agent for prevention of renal allograft rejection. *Am J Health Syst Pharm* 2000; 57: 437-448
6. Scott LJ, McKeage K, Keam SJ, Plosker GL. Tacrolimus: a further update of its use in the management of organ transplantation. *Drugs* 2003; 63: 1247-1297
7. Ponticelli C, Passerini C. Gastrointestinal complications in renal transplant recipients. *Transpl Int* 2005; 18: 643-650
8. ASGE: Technology status evaluation report: wireless capsule endoscopy. August 2002. *Gastrointest Endosc* 2002; 56: 621-624
9. Friedman S. Comparison of capsule endoscopy to other modalities in small bowel. *Gastrointest Endoscopy Clin N Am*. 2004; 14: 51-60
10. Maes BD, Dalle I, Geboes K et al. Erosive enterocolitis in mycophenolate mofetil-treated renal-transplant recipients with persistent afebrile diarrhea. *Transplantation* 2003; 75: 665-672
11. Altiparmak MR, Trablus S, Pamuk ON et al. Diarrhoea following renal transplantation. *Clin Transplant* 2002; 16: 212-216
12. Fox U, Lucani G. Disorders of the intestinal mesenteric lymphatic system. *Lymphology* 1993; 26: 61-66
13. Mrevlje Z, Jansa R, Mrevlje B. WCE as a diagnostic tool in protein-losing enteropathy [abstract]. Proceedings of the 4<sup>th</sup> International Conference on Capsule Endoscopy, Miami Florida, 2005. Miami, Florida, 2005. Yoqneam, Israel: Given Imaging, 2005: 143
14. Peretti N, Sant'Anna A.M.G.A, Dirks M.H, Seidman E.G. Capsule endoscopy defects lymphangiectasia missed by other means [abstract]. Proceedings of the 4<sup>th</sup> International Conference on Capsule Endoscopy, Miami Florida, 2005. Miami, Florida, 2005. Yoqneam, Israel: Given Imaging, 2005: 189
15. Danielsson A, Toth E, Thorlacius H. Value of wireless capsule endoscopy in the management of small bowel lymphangiectasia in yellow nail syndrome [abstract]. Proceedings of the 4<sup>th</sup> International Conference on Capsule Endoscopy, Miami Florida, 2005. Miami, Florida, 2005. Yoqneam, Israel:

- Given Imaging, 2005: 221
16. Buckner FS, Pomeroy C. Cytomegalovirus disease of the gastrointestinal tract in patients without AIDS. *Clin Infect Dis* 1993; 17: 644-656
  17. Shrestha BM, Parton D, Gray A et al. Cytomegalovirus involving gastrointestinal tract in renal transplant recipients. *Clin Transplant* 1996; 10: 170-175
  18. Maieron A, Hubner D, Blaha B et al. Multicenter retrospective evaluation of capsule endoscopy in clinical routine. *Endoscopy* 2004; 36: 864-868
  19. Sriram PV, Rao GV, Reddy DN. Wireless capsule endoscopy: experience in a tropical country. *J Gastroenterol Hepatol* 2004; 19: 63-67
  20. Fleischer D. Capsule imaging. *Clin Gastroenterol Hepatol* 2005; 3: S30-S32
  21. Fry LC, Carey EJ, Shiff AD et al. The yield of capsule endoscopy in patients with abdominal pain or diarrhea. *Endoscopy* 2006; 38: 498-502