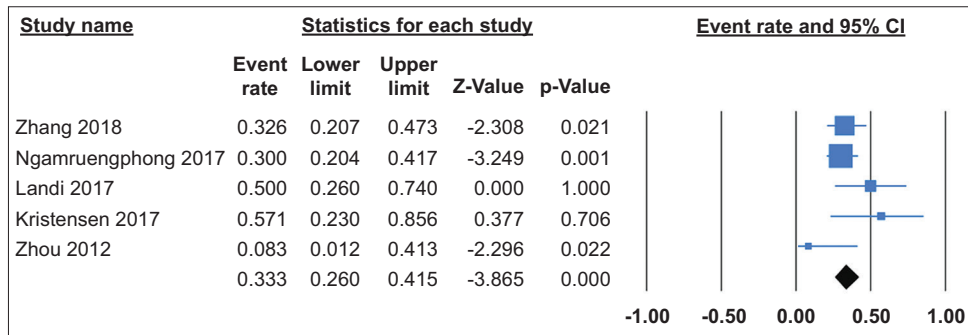
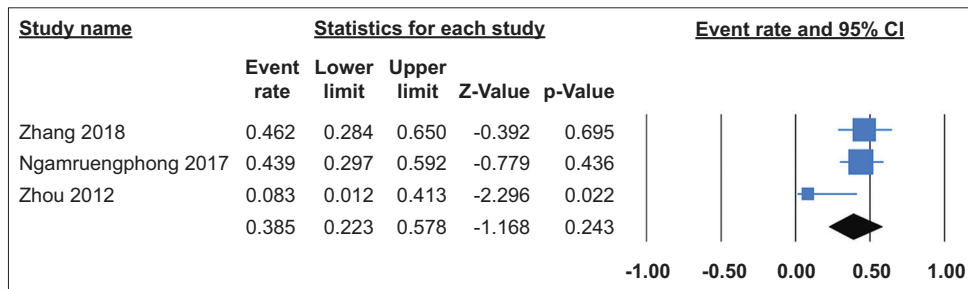


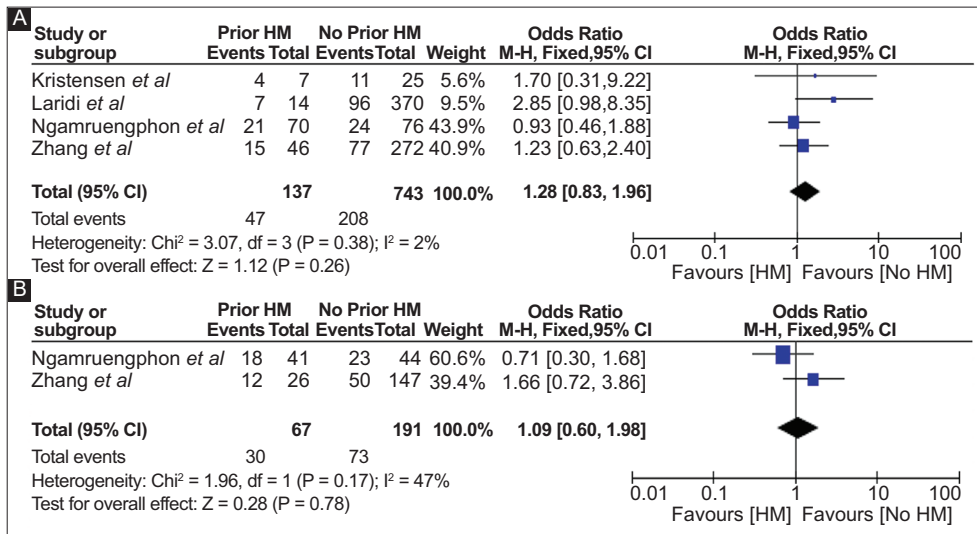
Supplementary material



Supplementary Figure 1 Overall risk of gastroesophageal reflux disease with peroral endoscopic myotomy after failed Heller myotomy
CI, confidence interval



Supplementary Figure 2 Overall risk of esophagitis with peroral endoscopic myotomy after failed Heller myotomy
CI, confidence interval



Supplementary Figure 3 (A) Risk of gastroesophageal reflux disease in patients with prior Heller myotomy (HM) vs. no prior HM (B) Risk of esophagitis in patients with prior HM vs. no prior HM
CI, confidence interval