

Timing of endoscopic therapy for acute bilio-pancreatic diseases: a practical overview

Matteo Rossano Buonocore^a, Ugo Germani^a, Danilo Castellani^a, Leonidas Petrogiannopoulos^a, Socrate Pallio^b, Matteo Piciocchi^c, Andrea Sbrozzi-Vanni^d, Angelo Zullo^e, Raffaele Manta^a

General Hospital of Perugia; ^a“G. Martino” General Hospital of Messina; General Hospital of Orvieto; Apuane General Hospital of Massa; ^e“Nuovo Regina Margherita” Hospital, Rome, Italy

Abstract

Diseases of the pancreas and hepatobiliary tree often require a therapeutic approach with endoscopic retrograde cholangiopancreatography (ERCP), generally following noninvasive imaging techniques. Appropriate indications and the correct timing for urgent ERCP would benefit both patients and clinicians and allow optimal utilization of health resources. Indications for urgent (<24 h) ERCP include severe acute cholangitis, acute biliary pancreatitis with cholangitis, biliary or pancreatic leaks, in the absence of percutaneous drainage, and severe acute cholecystitis in patients who are unfit for surgery and do not respond to conservative management. In patients who have severe acute biliary pancreatitis with ongoing biliary obstruction but without cholangitis, early (<48-72 h) ERCP is indicated. This overview aims to provide decisional flowcharts that can be easily used for managing patients with acute bilio-pancreatic disorders when they are referred to the Emergency Department.

Keywords Cholangitis, pancreatitis, cholecystitis, biliary leak, ERCP, EUS

Ann Gastroenterol 2021; 34 (2): 125-129

Introduction

Diseases of the pancreas and hepatobiliary tree often require a therapeutic approach with endoscopic retrograde cholangiopancreatography (ERCP), particularly following noninvasive imaging techniques. Indeed, a combination of abdominal ultrasound (US), computed tomography (CT), magnetic resonance cholangiopancreatography (MRCP), and endoscopic ultrasonography (EUS), together with blood

biochemistry, generally allow both benign and malignant bilio-pancreatic diseases to be diagnosed accurately. The majority of these disorders are susceptible to curative or palliative endoscopic treatment with ERCP and, less frequently, with EUS. Therefore, ERCP is currently applied as a mere therapeutic endoscopic tool. In acute bilio-pancreatic disease the timing of ERCP is crucial, procedures performed too early or too late being equally harmful. However, besides the risks associated with sedation and the use of ionizing radiation, ERCP is a technically demanding procedure with potentially serious complications, even in expert hands [1]. The most frequent complications include: acute pancreatitis (3.5-9.7%), infections (cholangitis up to 3%, cholecystitis up to 5.2%), bleeding (0.3-9.6%), and perforation (up to 0.6%) [1]. Therefore, it is clinically useful to define the situations that require urgent endoscopic treatment for patients managed in the Emergency Department, or admitted to the clinical wards for acute bilio-pancreatic diseases. This overview aims to provide practical decision processes for approaching these potential life-threatening clinical conditions.

^aGastroenterology and Digestive Endoscopy Unit, General Hospital of Perugia (Matteo Rossano Buonocore, Ugo Germani, Danilo Castellani, Leonidas Petrogiannopoulos, Raffaele Manta); ^bDigestive Endoscopy Unit “G. Martino”, General Hospital Messina (Socrate Pallio);

^cGastroenterology and Digestive Endoscopy Unit, General Hospital of Orvieto (Matteo Piciocchi); ^dDigestive Endoscopy Unit, Apuane General Hospital of Massa (Andrea Sbrozzi-Vanni); ^eGastroenterology and Digestive Endoscopy, “Nuovo Regina Margherita” Hospital, Rome (Angelo Zullo), Italy

Conflict of Interest: None

Correspondence to: Dr. Raffaele Manta, Gastroenterologia e Endoscopia Digestiva, Azienda Ospedaliera-Universitaria di Perugia, Ospedale Santa Maria della Misericordia, Piazzale Menghini, 1 – 06129 Loc. San Sisto, Perugia, Italy, e-mail: raffaelemanta4@gmail.com; raffaele.manta@ospedale.perugia.it

Received 27 June 2020; accepted 13 August 2020; published online 27 January 2021

DOI: <https://doi.org/10.20524/aog.2021.0580>

bacterial migration in the biliary tree. In case of biliary tract obstruction, bile flow is impaired and there is a retrograde migration of pathogens with bacterial proliferation in the biliary tree, which leads to the development of acute cholangitis. The Tokyo Guidelines on the management of acute cholangitis and cholecystitis, issued by the Japanese Society of Hepatobiliary Surgery in 2018, represent the reference for the recognition, diagnosis and staging of acute cholangitis severity [2]. The diagnosis of acute cholangitis is based on the following criteria: 1) clinical, including jaundice, pain and fever (Charcot triad); 2) serological, with cholestasis signs (bilirubin), with or without elevation of transaminases; and 3) radiological, which allows the recognition of common bile duct dilation (CBD >6 mm with gallbladder in place, >10 mm in case of previous surgical cholecystectomy) and the cause of the obstruction (e.g., stenosis, lithiasis, neoplasia). Once the diagnosis of acute cholangitis has been established, stratifying patients according to the severity of the clinical scenario is mandatory. In particular, severe (or grade III) acute cholangitis is characterized by its association with signs of organ failure (Table 1).

A recent systematic review and meta-analysis, which evaluated data from 9 observational studies involving a total of 7534 patients, showed that ERCP performed within 48 h of symptom onset is associated with a reduction in early and late mortality, organ failure, and length of hospitalization [3]. According to the Tokyo guidelines [2], ERCP should be performed within 24 h, whilst the European Society of Digestive Endoscopy (ESGE) guidelines recommend biliary drainage as soon as possible, and within 12 h in patients with septic shock [4]. Therefore, in case of severe acute cholangitis, ERCP with biliary sphincterotomy becomes a life-saving therapeutic procedure and should be performed as soon as possible (within 12-24 h). Otherwise, in case of non-severe acute cholangitis, conservative management with antibiotic

therapy for 24 h should be attempted before ERCP, which can be delayed for 48-72 h [3]. In case of therapy failure, ERCP should be performed in these patients as soon as possible, or within 24 h (Fig. 1).

Acute biliary pancreatitis (ABP)

Obstruction of the pancreatic outlet, as a result of gallstone migration in the CBD, triggers the pathophysiological mechanisms of ABP, such as intracellular enzyme activation, self-digestion, and activation of the inflammatory pathway. The diagnosis of ABP is based on the association of typical abdominal pain, laboratory tests elevation and US findings. The latter, when direct visualization of biliary obstruction is not feasible, may detect indirect signs, such as dilation of the biliary tract and/or the presence of gallbladder stones. The combination of elevated serological liver tests and dilation of the common bile duct (CBD) on US evaluation has 95% sensitivity in diagnosing ABP [5]. Moreover, alanine aminotransferase levels >150 U/L within 48 h from the onset of symptoms have a positive predictive value >85% for the presence of CBD stones [6]. Early conservative management of ABP is based on appropriate intravenous fluid administration, to minimize the risk of hypovolemia and organ failure. After initial resuscitation and patient stabilization, timing of ERCP in ABP depends on the clinical situation. When this condition is associated with cholangitis, there is evidence that strongly supports performing ERCP as soon as possible and within 24 h [7-9]. In the absence of cholangitis, the role and timing of ERCP in ABP are still under debate, as pointed out in a Cochrane systematic review and meta-analysis [10]. Early routine ERCP may lead to many unnecessary procedures, as the offending gallstone might have spontaneously passed before the diagnosis of pancreatitis is reached. The results of an ongoing multicenter randomized controlled trial comparing early ERCP versus conservative treatment might impact on the future management of severe ABP patients [11]. While we wait for this evidence, ERCP within 48-72 h has been suggested in the setting of severe acute pancreatitis (as defined by the revised Atlanta classification) that shows persistent or worsening signs of biliary tract obstruction [9,12,13].

Table 1 Severity assessment criteria for acute cholangitis according to Tokyo Guidelines 2018

Grade I (mild) acute cholangitis Does not meet the criteria for Grade III (severe) or Grade II (moderate)
Grade II (moderate) acute cholangitis – Any 2 of the following conditions: 1. WBC count >12,000 /mm ³ or <4,000 /mm ³ 2. Fever ≥39°C 3. Age ≥75 years 4. Total bilirubin ≥5 mg/dL
Grade III (severe) acute cholangitis - Dysfunction at least in one of the following organs/systems: 1. Cardiovascular: hypotension requiring dopamine >5 µg/kg/min, or any dose of norepinephrine 2. Neurological: disturbance of consciousness 3. Respiratory: PaO ₂ /FiO ₂ ratio <300 4. Renal: oliguria, serum creatinine >2.0 mg/dL 5. Hepatic: PT-INR >1.5 6. Hematological: platelet count <100,000 /mm ³

Modified from reference 2

WBC, white blood cells; PT, prothrombin time; INR, international normalized ratio

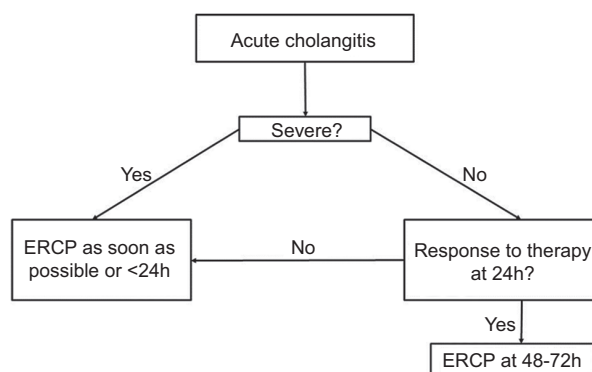


Figure 1 Flowchart for acute cholangitis
ERCP, endoscopic retrograde cholangiopancreatography

Otherwise, if signs of biliary obstruction improve or finally regress, previous EUS evaluation or MRCP should be performed within 24-48 h to avoid inappropriate ERCP [6] (Fig. 2).

Bilio-pancreatic leaks

Bile peritonitis due to biliary leak (BL) is a dangerous event that requires an immediate approach to the biliary tract. Currently, there are no specific guidelines or consensus about the optimal management of this condition, which complicates 1-4% of surgical cholecystectomies and is relatively frequent after liver transplantation, partial hepatectomy and liver trauma [14]. The diagnosis of BL, apart from the clinical findings, relies mainly on abdominal CT scan and MRCP. After BL is confirmed, ERCP allows biliary sphincterotomy, which decreases the transpapillary pressure gradient, in order to divert bile from the leakage site, thus promoting fistula healing. Moreover, in “high grade” fistulas, where the leakage is already visible before the opacification of the intrahepatic biliary system, the placement of a nasobiliary drain or a plastic stent bridging the leak site allows bile outflow and prevents stenosis formation during the healing process [15].

To our knowledge, only 2 retrospective studies have described the clinical impact of timing on ERCP outcome for treatment of post-surgical BL [14,16]. These studies are not directly comparable because of their several differences. The BL prevalence of post-cholecystectomy was 70.6% vs. 100%, the rate of percutaneous abdominal drainage placement was 45% vs. 9% and the median interval time between cholecystectomy and

ERCP was 5 vs. 3 days. All these differences might impact on patients’ outcomes. However, both studies found that patients treated between 48 and 72 h after the onset of BL had lower mortality than those treated within 24 or after 72 h. Nevertheless, these data are likely related to selection bias, if we consider that patients with higher severity at presentation underwent ERCP either emergently, or were delayed until they stabilized, whilst in more stable patients ERCP was scheduled within 2-3 days.

Pancreatic fistula is a potentially fatal postsurgical event when associated with organ failure. In this setting, surgery represented the gold standard until a few years ago, whilst recent studies suggest minimally invasive techniques, such as endoscopic or radiological approaches, as the first-line procedure. Sharing the same pathophysiological mechanisms of BL, the purpose of ERCP in the pancreatic fistula is to reduce the pressure gradient by pancreatic sphincterotomy, followed by stent or nasopancreatic tube placement [17].

To date, urgent ERCP within 72 h seems to be the best approach, although data regarding this timing are scarce and strong evidence is lacking. While awaiting further studies, we would suggest 2 different approaches regarding ERCP timing in the setting of bilio-pancreatic leak. If percutaneous abdominal drainage is present, ERCP can be performed within 72 h, otherwise the ERCP should be carried out as soon as possible, and in any case within 24 h (Fig. 3).

Acute cholecystitis

In high-volume centers, urgent ERCP is a therapeutic option in patients with acute cholecystitis unfit for surgery. Once

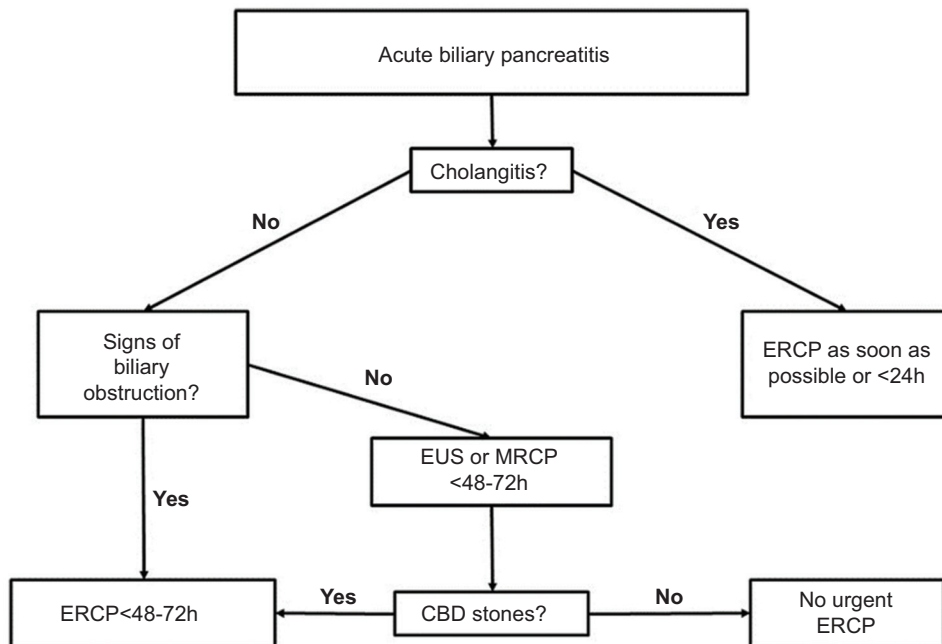


Figure 2 Flowchart for acute biliary pancreatitis
 ERCP, endoscopic retrograde cholangiopancreatography; EUS, endoscopic ultrasonography; MRCP, magnetic resonance cholangiopancreatography; CBD, common bile duct

the diagnosis is reached, acute cholecystitis should be staged according to severity, as defined by the Tokyo 2018 Guidelines, similarly to acute cholangitis (Table 1) [18]. In patients with severe acute cholecystitis unresponsive to conservative therapy and unfit for surgery, non-surgical alternative therapeutic procedures are the following:

- 1) Percutaneous transhepatic ultrasound/CT-guided biliary drainage (PT-GBD), which achieves a high technical success rate, but is often followed by severe complications, resulting in longer hospital stay and higher costs.
- 2) Transpapillary drainage by ERCP (TP-GBD), a procedure that allows access to the gallbladder lumen through the cystic duct and permits the placement of a trans-cystic stent or drainage. Technical success rates for this procedure range from 81-96% [19].
- 3) EUS-guided transmural drainage (EUS-GBD), an operator-dependent procedure that presents early and late

complications [19,20]. In recent years, a novel technique for EUS-guided positioning of a lumen-apposing metal stent has been introduced for gallbladder drainage (GBD) in acute cholecystitis patients unfit for surgery. This endoscopic approach consists in creating a fistula between the stomach or the duodenal bulb and the gallbladder, through the insertion of a specifically designed stent, fixing the gallbladder wall directly to the intestinal lumen [21]. Data from some studies showed a high success rate with acceptably few complications [22], and this approach is increasingly performed in dedicated and tertiary endoscopic centers [23].

Fig. 4 presents the flowchart for urgent endoscopy in the treatment of severe cholecystitis unresponsive to conservative therapy [24]. In patients unfit for surgery, endoscopic drainage of the gallbladder within 24 h represents the first and definitive therapeutic option. EUS-GBD has been found to be superior to PT-GBD and TP-GBD, showing higher clinical success. Nevertheless, these procedures have similar adverse events, as confirmed by recent studies [25-27]. Another study showed that TP-GBD is more cost-effective, at least in the USA [28].

To date, endoscopic GBD (TP-GBD and EUS-GBD) is performed by skilled pancreatobiliary endoscopists in a few dedicated centers throughout the world and it is not established as a standard procedure. Therefore, even though the Tokyo 2018 Guidelines recommend PT-GBD as the first alternative to surgery, upcoming literature pointed out the role of EUS-GBD. However, the choice between EUS-GBD and TP-GBD currently depends on a center's facilities and the operator's expertise. More specifically, in patients fit for surgery, TP-GBD within 24 h represents the first therapeutic choice; EUS-GBD is not indicated, as it would negatively impact the following surgical cholecystectomy. The purpose of treatment is to relieve

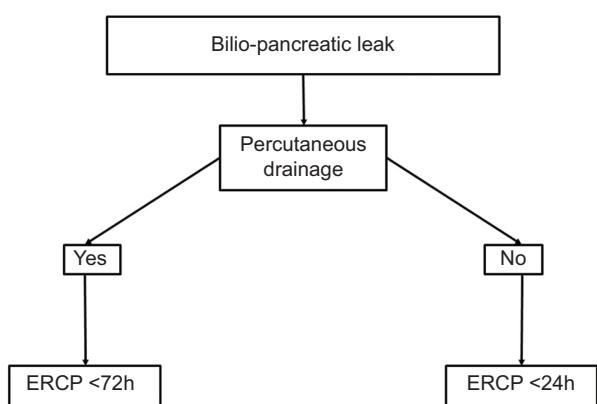


Figure 3 Flowchart for bilio-pancreatic leaks
ERCP, endoscopic retrograde cholangiopancreatography

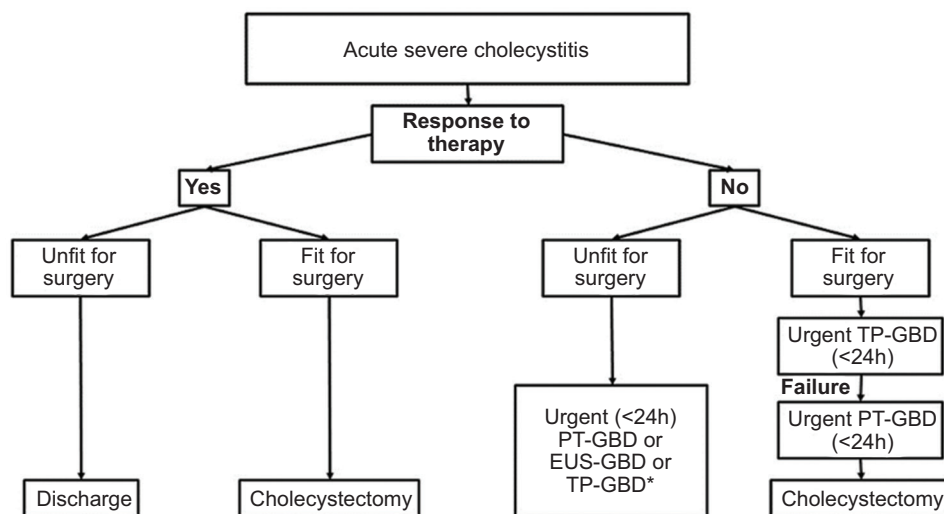


Figure 4 Flowchart for acute severe cholecystitis

*The best approach varies depending on local facilities

TP-GBD, transpapillary drainage by endoscopic retrograde cholangiopancreatography; PT-GBD, percutaneous transhepatic ultrasound/computed tomography-guided biliary drainage; EUS-GBD, endoscopy ultrasound-guided transmural drainage; EUS-LAMS, endoscopy ultrasound-guided lumen-apposing metal stent

acute inflammation and postpone urgent surgery, otherwise complicated by a high rate of adverse events. Finally, in case of TP-GBD failure, PT-GBD can be performed, leaving surgery as the last therapeutic approach.

In conclusion, ERCP plays a relevant therapeutic role in various bilio-pancreatic disorders. To achieve the best advantage, it is crucial to adopt the correct timing when performing this procedure, which depends on the clinical scenario, and on local resources and expertise, as shown in this comprehensive overview.

References

- Dumonceau JM, Kapral C, Aabakken L, et al. ERCP-related adverse events: European Society of Gastrointestinal Endoscopy (ESGE) Guideline. *Endoscopy* 2020;**52**:127-149.
- Kiriyama S, Kozaka K, Takada T, et al. Tokyo Guidelines 2018: diagnostic criteria and severity grading of acute cholangitis (with videos). *J Hepatobiliary Pancreat Sci* 2018;**25**:17-30.
- Iqbal U, Khara HS, Hu Y, et al. Emergent versus urgent ERCP in acute cholangitis: a systematic review and meta-analysis. *Gastrointest Endosc* 2020;**91**:753-760.
- Manes G, Paspatis G, Aabakken L, et al. Endoscopic management of common bile duct stones: European Society of Gastrointestinal Endoscopy (ESGE) guideline. *Endoscopy* 2019;**51**:472-491.
- Ammori BJ, Boreham B, Lewis P, Roberts SA. The biochemical detection of biliary etiology of acute pancreatitis on admission: a revisit in the modern era of biliary imaging. *Pancreas* 2003;**26**:e32-e35.
- Working Group IAP/APA Acute Pancreatitis Guidelines. IAP/APA evidence-based guidelines for the management of acute pancreatitis. *Pancreatol* 2013;**13**(4 Suppl 2):e1-e15.
- van Santvoort HC, Besselink MG, de Vries AC, et al; Dutch Acute Pancreatitis Study Group. Early endoscopic retrograde cholangiopancreatography in predicted severe acute biliary pancreatitis: a prospective multicenter study. *Ann Surg* 2009;**250**:68-75.
- Tenner S, Baillie J, DeWitt J, Vege SS; American College of Gastroenterology. American College of Gastroenterology guideline: management of acute pancreatitis. *Am J Gastroenterol* 2013;**108**:1400-1415; 1416.
- Pezzilli R, Zerbi A, Campa D, et al; Italian Association for the Study of the Pancreas (AISP). Consensus guidelines on severe acute pancreatitis. *Dig Liver Dis* 2015;**47**:532-543.
- Tse F, Yuan Y. Early routine endoscopic retrograde cholangiopancreatography (ERCP) strategy versus early conservative management strategy in acute gallstone pancreatitis: a Cochrane systematic review and meta-analysis. *Cochrane Database Syst Rev* 2012;**16**:CD009779.
- Schepers NJ, Bakker OJ, Besselink MG, et al; Dutch Pancreatitis Study Group. Early biliary decompression versus conservative treatment in acute biliary pancreatitis (APEC trial): study protocol for a randomized controlled trial. *Trials* 2016;**17**:5.
- Banks PA, Bollen TL, Dervenis C, et al; Acute Pancreatitis Classification Working Group. Classification of acute pancreatitis—2012: revision of the Atlanta classification and definitions by international consensus. *Gut* 2013;**62**:102-111.
- Vege SS, DiMaggio MJ, Forsmark CE, Martel M, Barkun AN. Initial medical treatment of acute pancreatitis: American Gastroenterological Association institute technical review. *Gastroenterology* 2018;**154**:1103-1139.
- Adler DG, Papachristou GI, Taylor LJ, et al. Clinical outcomes in patients with bile leaks treated via ERCP with regard to the timing of ERCP: a large multicenter study. *Gastrointest Endosc* 2017;**85**:766-772.
- Haidar H, Manasa E, Yassin K, Suissa A, Kluger Y, Khamaysi I. Endoscopic treatment of post-cholecystectomy bile leaks: a tertiary center experience. *Surg Endosc* 2020 Feb 27 [Online ahead of print]. doi: 10.1007/s00464-020-07472-0
- Abbas A, Sethi S, Brady P, Taunk P. Endoscopic management of postcholecystectomy biliary leak: When and how? A nationwide study. *Gastrointest Endosc* 2019;**90**:233-241.
- Bassi C, Marchegiani G, Dervenis C, et al. The 2016 update of the International Study Group (ISGPS) definition and grading of postoperative pancreatic fistula: 11 years after. *Surgery* 2017;**161**:584-591.
- Yokoe M, Hata J, Takada T, et al. Tokyo Guidelines 2018: diagnostic criteria and severity grading of acute cholecystitis (with videos). *J Hepatobiliary Pancreat Sci* 2018;**25**:41-54.
- Siddiqui A, Kunda R, Tyberg A, et al. Three-way comparative study of endoscopic ultrasound-guided transmural gallbladder drainage using lumen-apposing metal stents versus endoscopic transpapillary drainage versus percutaneous cholecystostomy for gallbladder drainage in high-risk surgical patients with acute cholecystitis: clinical outcomes and success in an International, Multicenter Study. *Surg Endosc* 2019;**33**:1260-1270.
- Mori Y, Itoi T, Baron TH, et al. Tokyo Guidelines 2018: management strategies for gallbladder drainage in patients with acute cholecystitis (with videos). *J Hepatobiliary Pancreat Sci* 2018;**25**:87-95.
- Peñas-Herrero I, de la Serna-Higuera C, Perez-Miranda M. Endoscopic ultrasound-guided gallbladder drainage for the management of acute cholecystitis (with video). *J Hepatobiliary Pancreat Sci* 2015;**22**:35-43.
- Manta R, Zulli C, Zullo A, et al. Endoscopic ultrasound-guided gallbladder drainage for acute cholecystitis with a silicone-covered nitinol short bilaterally flared stent: a case series. *Endosc Int Open* 2017;**5**:E1111-E1115.
- Manta R, Mutignani M, Galloro G, Conigliaro R, Zullo A. Endoscopic ultrasound-guided gallbladder drainage for acute cholecystitis with a lumen-apposing metal stent: a systematic review of case series. *Eur J Gastroenterol Hepatol* 2018;**30**:695-698.
- Okamoto K, Suzuki K, Takada T, et al. Tokyo Guidelines 2018: flowchart for the management of acute cholecystitis. *J Hepatobiliary Pancreat Sci* 2018;**25**:55-72.
- Teoh AYB, Kitano M, Itoi T, et al. Endosonography-guided gallbladder drainage versus percutaneous cholecystostomy in very high-risk surgical patients with acute cholecystitis: an international randomised multicentre controlled superiority trial (DRAC 1). *Gut* 2020;**69**:1085-1091.
- Mohan BP, Khan SR, Trakroo S, et al. Endoscopic ultrasound-guided gallbladder drainage, transpapillary drainage, or percutaneous drainage in high risk acute cholecystitis patients: A systematic review and comparative meta-analysis. *Endoscopy* 2020;**52**:96-106.
- Krishnamoorthi R, Jayaraj M, Thoguluva Chandrasekar V, et al. EUS-guided versus endoscopic transpapillary gallbladder drainage in high-risk surgical patients with acute cholecystitis: a systematic review and meta-analysis. *Surg Endosc* 2020;**34**:1904-1913.
- Corral JE, Das A, Kröner PT, Gomez V, Wallace MB. Cost effectiveness of endoscopic gallbladder drainage to treat acute cholecystitis in poor surgical candidates. *Surg Endosc* 2019;**33**:3567-3577.