

<i>Review</i>
---------------

# Implementation of hemostatic techniques in the treatment of upper gastrointestinal hemorrhage

G.E. Kokozides

## SUMMARY

Acute hemorrhage of the upper peptic system is the most common emergency that a clinical doctor has to deal with. According to recent epidemiological data, acute non-cirroid hemorrhage concerns most of the 300,000 annual admissions to U.S.A. hospitals with a mortality rate of nearly 7-10%. The reestablishment of hemodynamic disturbances and the replacement of the lost in vessel mass is the prime role of the clinical doctor. When hemodynamic stability is obtained, the adaptation of therapeutic endoscopy is of vital significance for the verification and the interruption of the hemorrhage. In the review that follows, analysis of the different endoscopic techniques for hemostasis available today is attempted and in particular, methods of adaptation and their results in confronting acute hemorrhage of the upper peptic system.

**Key-words:** Acute hemorrhage of upper peptic system, therapeutically intervention, Endoscopical techniques of hemostase.

U.S., reaching mortality rates of 7-10%.<sup>1</sup>

Acute hemorrhage of the *upper gastrointestinal system* is defined as the loss of blood / bleeding of the gastrointestinal tract whose original focal point is located in the area proximal to Treitz ligament. This type of hemorrhage can have symptoms such as hematemesis or melena, with or without hemodynamic shock. Haematochezia refers to the presence of fresh red blood through the rectum, and it usually occurs in patients with extremely rapid loss of blood accompanied by hemodynamic instability.<sup>2</sup>

In hemorrhage due to esophageal varices, which constitutes a major complication of liver cirrhosis, hemodynamic instability needs to be treated first; while for each incidence of hemorrhage mortality rates reach 15-30%.

Patients presenting acute hemorrhage of the upper gastrointestinal tract require immediate clinical assessment as well as treatment. The principal aim of the clinician is to restore hemodynamic stability and to replace intra-vessel volume.

After restoration of hemodynamic stability, patients with acute hemorrhage of the upper gastrointestinal tract are subjected to endoscopy of the upper gastrointestinal tract. Initial assessment should take vital signs into account, and it should focus on the presence (or not) of hypovolemia and even of shock. Special attention should be paid to patient's medical history regarding administration of medication, such as anticoagulants, thrombolytic or other drugs that could be related to hemorrhage, e.g. NSAIDS.

Initial administration of crystalloids / crystalloid solutions aims at keeping blood pressure at a normal level, and also at restoration of hypovolemia. Administration of RBC concentrates is recommended for patients with active massive loss of blood or in cases of cardiac ischemia. In serious cases of hematemesis or melena with massive

## SECTION A

### INTRODUCTION

Acute hemorrhage in the upper gastrointestinal tract is one of the most common emergency cases that a physician is called to face in clinical practice.

According to recent epidemiological evidence, acute hemorrhage of non-varix cause / etiology occurs in more than 300.000 cases annually admitted to hospitals in the

Consultant - Gastroenterology Ward, "G. Papanikolaou" Hospital, Thessalonica

Author for correspondence:

G. Kokozides, 52 Perikleous str., 551 33 Thessaloniki, Greece,  
Tel.: +2310 350 332, e-mail: gkokozidis@mailbox.gr

blood loss and hemodynamic instability, admission of the patient to an intensive care unit is obligatory / required. Peptic ulcers constitute the most frequent cause of acute upper gastrointestinal tract hemorrhage (table 1).<sup>3</sup>

The highest rates of hemorrhage cases (more than 80% of hemorrhage cases with hemodynamic stability) do not re-appear; thus, no emergency endoscopy is required. However, in cases with an actively bleeding peptic ulcer and also in cases with visible, non-bleeding dilated vessels, the risk of hemorrhage recurrence is 80% and 50%<sup>4</sup>, respectively

The role of anti-secretory medication (PPI) in acute upper gastrointestinal tract hemorrhage, has been well studied. It has been reported in a recent review that use of PPIs in patients with acute upper gastrointestinal tract hemorrhage is justified.<sup>5</sup> Furthermore, it has been shown that, through the combination of PPI administration and endoscopic intervention, hemorrhage recurrence is rarer and the need for blood units is reduced<sup>5</sup>. The ideal dosage of PPIs in acute upper gastrointestinal tract hemorrhage cases is not yet clarified.

Somatostatin, and its equivalent octreotide, decreases blood flow via portal vein on the one hand and ar-

terial blood flow in the stomach and duodenum on the other; however, renal arterial blood flow is sustained<sup>6</sup>. The evidence according to fourteen studies including 1,829 patients with acute upper gastrointestinal tract hemorrhage, not due to esophageal varices, leads to the conclusion that natural somatostatin and octreotide decrease the risk of continuing hemorrhage as well as the need for surgical treatment. Another conclusion of these studies is that the above medications are more effective in cases with actively bleeding peptic ulcers than in cases without any peptic ulcers (e.g. hemorrhagic gastritis). This medication is considered as an additional therapeutic means implemented before endoscopy or in case endoscopy fails, or is not recommended or is not available.<sup>7</sup>

### ***The role and effectiveness of endoscopy in treatment of upper gastrointestinal tract hemorrhage***

The use of endoscopy in patients with upper gastrointestinal tract hemorrhage is effective for diagnosis and treatment of the majority of causes that lead to upper gastrointestinal tract hemorrhage. Its side advantages are: decrease of the need for blood units, shortening of patient stay in ICUs and of hospital stay in general.<sup>8</sup>

Early endoscopy (within the first 24 hrs of hospital admission) is more effective than endoscopy conducted at a later stage, reducing the need for blood units (transfusions) and patient hospital stay.<sup>9</sup>

The endoscopic features of a hemorrhagic peptic ulcer are referred as spots of recent bleeding and these are classified according to the Forrest classification scale (Table 2).<sup>10</sup> Sometimes these spots are also identified in other cases of upper gastrointestinal tract hemorrhage (such as serious oesophagitis with ulcerations).<sup>11,12</sup> It seems that the spots contribute to predicting probable upper gastrointestinal tract hemorrhage recurrence, the duration of hospitalization, and determine the decision for endoscopic intervention or even emergency surgery (Table 3)

Treatment via endoscopy is recommended in cases of patients presenting an active hemorrhage, originating from a capillary arterial vessel (oozing) as well as patients with an ulcer and a visible dilated bleeding vessel (spurting).<sup>13</sup>

Hemostasis via endoscopy is immediately required in cases of active upper gastrointestinal tract hemorrhage or in cases of patients with a visible bleeding vessel at the bottom of an ulcer. Evidence regarding the need for endoscopy in cases of adherent clots is still controversial. On the contrary, presence of a colour stain or a clear ul-

**Table 1.** Causes of upper gastrointestinal tract hemorrhage

Diagnosis	Rate (Percentage %)
Peptic ulcer	35-50
Erosions of stomach / duodenum walls	8-15
Esophagitis	5-15
Esophageal varices	5-15
Mallory-Weiss	1,5
Neoplasia	1
Angiodysplasiae	1
Other causes	5

**Table 2.** Forrest - Bleeding Ulcer Classification Scale

Hemorrhage status	Endoscopic features
<b>Forrest Ia</b>	
Active hemorrhage	Arterial hemorrhage (spurting)
<b>Forrest Ib</b>	
Active hemorrhage	Flowing hemorrhage (oozing)
<b>Forrest II</b>	
Non-bleeding, but with presence of damage	Clot adherent to ulcer bottom, visible vessel
<b>Forrest III</b>	
Without active hemorrhage, without further damage	Ulcer with no spots of recent bleeding (clear bottom)

**Table 3.** Hemorrhage spots of upper gastrointestinal tract and hemorrhage recurrence risk, without endoscopic treatment.

Hemorrhage Spots	Hemorrhage recurrence Risk without treatment
Active arterial hemorrhage (spurting)	100%
Visible vessel (non-bleeding)	80%
Non-bleeding adherent clot	30-50%
Flowing (oozing) hemorrhage	10-27%
Flat clot	<8%
Ulcer with a clear bottom	<2%

cer bottom indicate that there is no need for endoscopic intervention.<sup>14</sup>

Apart from recent bleeding spots, location and size of an ulcer are also predictive indicators of hemorrhage outcome. Deep, large ulcers located within the minor stomach arch or in the posterior wall of the duodenum are related to higher risk of serious hemorrhage due to their proximity to large vessels.<sup>15</sup>

## SECTION B

### *Endoscopic Techniques / Methods of Hemostasis*

Hemostasis via endoscopy has been shown to improve upper gastrointestinal tract hemorrhage outcome.<sup>16</sup> Such methods have been implemented in lower gastrointestinal hemorrhage;<sup>17</sup> these include: thermal heater devices (Heater Probe, Multi-polar electrocautery probes), remote thermal devices (Laser and Argon Plasma Coagulation), sclerotherapy needles, and mechanical equipment (Bands, clips and loops).

### **Endoscopic Techniques – Review**

#### *A) Thermal Hemostasis Methods*

Heat is produced by all thermal hemostasis methods, either directly (Heater Probe), or indirectly, through absorbing photon energy (Laser) of the tissues or by transmission of electrical energy through the tissues (Multipolar Probes, APC). Heating causes edema, tissue protein fusion and vessel contraction, which in turn lead to hemostatic fusion.<sup>18</sup> Tissue fusion requires temperatures of approximately 70°C. Repeated implementation of this method via contact thermal devices may lead to accumulation of fused tissues on the probe surface, decreasing – in this way – the probe capacity. For this purpose, during each session, the probe should often be pulled up and cleaned.

1) *Multipolar Electrocautery (MPEC) / Bipolar Electrocautery* MPEC probes transmit thermal energy to the

tissues by integrating an electrical circuit, through the tissues, between two electrodes placed on the edge of each probe. Because there is only a local circuit, there is no need for an electrode ground patch. While tissues are fused, tissue electrical resistance increases; keeping the maximal temperature at approximately 100°C, and limiting the thermal damage depth.<sup>19</sup> Catheter design includes a water spurting tube. These catheters can be used both straight and sidelong.

2) *Heater Probe* A heater probe (HP) consists of a Teflon head that contains an internal thermal resistance by which temperature is kept at one level. Tissues are fused via direct heat transmission. Contact pressure is implemented while using HP, which also includes a water spurting tube. Turning on the device is accomplished through a foot pedal. Pressing of this pedal causes water spurt or transmission of a pre-selected energy amount to the thermal resistance.<sup>20</sup>

*Argon Plasma Coagulator.* This device operates using high-frequency mono-polar alternating current, transmitted to target tissues via ionized Argon gas (Argon Plasma). Electrons flow through ionized gas towards the target tissues producing heat emission at the contact point. Depth of tissue thermal fusion depends on: generator intensity, the duration of APC implementation, and the target tissue – probe distance<sup>21</sup> (varying from 2 to 8 mm). The application of APC is either frontal or tangent

#### *B) Substance Infusion Techniques*

Needles are devices, which pass through the endoscope's channel, allowing infusion of substances into target tissues, achieving – in this way – hemostasis by mechanical tamponade and through cytochemical mechanisms.<sup>22</sup> Substances used for this purpose are adrenaline solutions 1:10,000 or solutions of sclerotic substances, such as polydocanole, and ethanolamine.

#### *C) Mechanical Methods*

1) *Band Ligators.* A ligation device consists of an adaptor that is adjusted to endoscope's edge and bears loaded elastic rings as well as a mechanism necessary to release these rings. The target tissue is initially aspirated into the adaptor; then by pressing the trigger, one elastic ring is released and loops the target tissue. Hemostasis is accomplished by looping of the tissue, followed by necrosis of the spot and incrustation.<sup>23,24</sup> There are several types of ligature loops (single or multiple).

2) *Hemoclips.* Metal clips have been designed for use through endoscopes. These clips are adjusted to spe-

cial clip applying devices of 165 – 235 cm. length and of 2.8-3.2 mm. working channel diameter.<sup>25</sup> Some catheters bear a clip rotation mechanism, so that clip insertion is accurately oriented. These clips are loaded on the special device, and are drawn up within a cover. When reaching the damage area, the clip is pushed outside the cover, it is rotated to the desired position and then it is set. Hemostasis is accomplished through mechanical compression. Effective and quick use of the above clips requires a high degree of familiarization by all personnel involved. For this purpose, a pre-loaded one-use version of such devices is available, which allows multiple clip unfolding; thus, its use is comparably easier and more user-friendly (Resolution Clip, Boston Scientific).

- 3) Detachable Loops. A detachable loop made of nylon can be adjusted in order to loop around the target tissue. The device consists of several nylon loops and a catheter necessary for insertion of the loops. The catheter has a Teflon cover, 195 cm in length, and 2.5mm diameter. An elliptic or a circular loop is drawn and seized / captured in the catheter by a wire lead which is forwarded outside the cover. The catheter is inserted through the working channel / tube of the endoscope. The loop is then forwarded outside the catheter; it is placed around the target tissue, and it is tightened together by an elastic silicone ring. After the loop is well tightened (as shown by attaining hemostasis or by cyanosis of the looped part of the tissue), it is finally released.<sup>26</sup>

### ***Indications and Effectiveness***

According to 2 meta-analyses including over 30 randomized studies and 2,400 patients, endoscopic treatment has significantly reduced:

- hemorrhage recurrence,
- need for emergency surgical treatment, and:
- mortality rates.<sup>27,28</sup>

## **THERMAL HEMOSTASIS METHODS**

### ***Bleeding Gastro-duodenal Ulcers***

MPEC has been compared to placebo treatment in patients with active hemorrhage or presence of a visible vessel and it has been shown that this method reduces hemorrhage recurrence, emergency surgical procedures, and mean hospital stay as well as hospitalization costs. 10F probes seem to be more effective than those of 7F. Suggested settings of the device are: 15-

25 Watts with repeated implementations of 6-10 sec duration each. Two prospective analyses comparing Heater Probe (HP) without endoscopic intervention in patients with an ulcer and active bleeding or with a visible vessel, have shown significant benefits of the HP in immediate hemostasis and in hemorrhage recurrence.<sup>29,30</sup> Two randomized studies comparing Nd-Yag Laser to pharmaceutical treatment / medication, have shown comparative benefits of the first in reducing hemorrhage recurrence and also in avoiding surgery. However, a third study has shown no benefit. APC has been reported as beneficial in treating bleeding peptic ulcers.

### ***Angiectasiae of the Gastric Antrum***

HP, MPEC, Nd:YAG and APC have been successfully used in the treatment of angiectasiae of the gastric antrum.<sup>31</sup>

### ***Dieulafoy Damages***

Initial hemostasis has been achieved in >90% using Heater Probe.<sup>32</sup>

### ***Angiectasiae due to Radiation***

MPEC, HP, APC and LASER have been successfully implemented. Multiple sessions are usually required.<sup>33,34</sup>

### ***Hemorrhage subsequent to diverticulae***

MPEC, HP and Laser have been successfully implemented in rare cases where hemorrhage focal spot is identified or when hemorrhage spots are present when diverticulosis exists.<sup>35</sup>

### ***Angiodysplasiae***

MPEC, HP and Laser have been successfully implemented in the treatment of bleeding angiodysplasiae that are identified via endoscopy. As opposed to peptic ulcers, in the treatment of the above cases of angiodysplasiae, settings of lower device power should be used as well as lower pressure by MPEC and HP.<sup>36,37</sup>

### ***Infusion Techniques (Sclerotherapy needles)***

#### ***Bleeding gastro-duodenal ulcers***

Needles are effective when used in combination with a wide variety of injected solutions. In studies including placebo treatment, infusion treatment has reduced hemorrhage recurrence, the need for blood transfusions, emergency surgical operations and hospital stay.<sup>38,39</sup>

### ***Esophageal varices rupture***

Sclerotherapy needles have been proven effective for sclerotic substance infusion, such as Sodium tetradecyl sulfate, polidocanol, ethanolamine oleate, sodium morhuate and pure alcohol infusion used for the treatment of bleeding esophageal varices.<sup>40</sup> None of the above mentioned substances supersedes the rest. During this procedure, a needle enclosed in a catheter is forwarded through the endoscope and a sclerotic solution is injected either into the varix or around it, causing varix thrombosis and fibration of surrounding tissues.

Sclerotherapy of esophageal varices has been shown to achieve immediate hemostasis in 71-95% of the cases and it is beneficial to prevention of hemorrhage recurrence and to mortality rates. Effectiveness of sclerotherapy in primary prevention of esophageal varices rupture remains controversial.<sup>41</sup> Sclerotherapy has also been used in non-esophageal varices (such as gastric, intestinal, of the large intestine); however, effectiveness is comparatively lower and relevant evidence is limited.

### ***Hemorrhage due to diverticulae***

Adrenaline solution infusion can be implemented at colonoscopy in order to treat bleeding diverticulum.<sup>35</sup>

## **MECHANICAL METHODS – BAND LIGATION**

### ***Esophageal Varices Rupture***

Varices ligation is effective in active hemorrhage control at a rate of 86-91%.<sup>42</sup> Subsequent sessions lead to destruction of esophageal varices and decrease of hemorrhage recurrence. As far as gastric or intestinal varices or varices of the large intestine are concerned, there is limited evidence.

### ***Non-varix Etiology Hemorrhage***

Small scale studies and Case Reports describe the use of elastic rings in treatment of bleeding angiectasiae, Mallory – Weiss syndrome, hemorrhage after polypectomy, Dieulafoy damages, and duodenal ulcers.<sup>43,44</sup> A special set is available for use together with a colonoscope.

### ***Mechanical Methods – Endoscopic Hemoclips***

Hemoclips have succeeded in achieving hemostasis at a rate of 84-100% of patients with upper peptic system hemorrhage caused by various conditions, including peptic ulcers, angiectasiae, neoplasms, Mallory – Weiss, Dieulafoy damages, polypectomy, sphincterotomy, and biopsy. Hemoclips have also been used in hemorrhage treatment due to diverticulae, hemorrhoids, single rectum ulcers and after polypectomy and biopsy.<sup>45,46</sup>

### ***Mechanical Methods – Endoloop***

These methods have been developed to prevent and treat hemorrhage after polypectomy. The larger study (up to now), including 25 cases, has shown technical difficulties, such as: unintentional intersection of the pedicle / pedicle of the polyp; inadequate loop tightening; jam of the polypectomy loop; loop placement failure after polypectomy, due to pedicle retraction. Their use has been reported in cases of gastric varices.<sup>26</sup>

## **COMPARATIVE STUDIES**

### ***Gastro duodenal ulcers***

A prospective randomized trial has compared MPEC, HP and Nd:YAG laser in treatment of active hemorrhage and has shown that there is no significant difference in respect to hemorrhage recurrence rates (10%, 19.4% and 10% respectively), patient stay in hospital (5 days, 4 days, 4 days) and emergency surgery (7%, 13%, 7%), respectively. Cost per patient was greater with Nd:YAG laser.

Another study comparing MPEC to HP has shown no significant difference in respect to hemostasis, hospital stay, emergency surgery and mortality rates.<sup>47</sup> One study compared MPEC alone, adrenaline infusion alone, and also their combination; and has pointed out that the above combination has significantly reduced hemorrhage recurrence as well as the need for blood transfusions, compared to each method alone.<sup>48</sup> A randomized study has shown superiority of HP use in comparison to ethanol infusion regarding achievement rate of permanent hemostasis (95% to 71% respectively).<sup>49</sup> A randomized study which has compared HP method to adrenaline infusion in patients with active hemorrhage has indicated higher rate of initial hemostasis via infusion (96% to 83%), but the final outcomes have no difference. Two subsequent studies comparing the HP method to adrenaline infusion or adrenaline -polydicanole, have shown equal effectiveness of both methods. A randomized comparative study between APC and HP methods has shown no statistically significant difference, but it was of low statistical power.

Two randomized studies comparing Nd:YAG laser method to sclerotherapy have shown no differences in the outcomes.<sup>50</sup>

The hemoclip method compared to infusion of hypertonic solution of NaCl and adrenaline, as well as the combination of the two methods has been studied in a randomized prospective study including 124 patients. No significant difference has been identified in the initial hemostasis, the hemorrhage recurrence or need for emergency surgery.

The patient group, in which hemoclips were used, alone or combined, showed a trend for better outcomes.

A retrospective study of 99 patients comparing the aforementioned methods has had similar results; although especially in patients with oozing clips, significantly lower rate of hemorrhage recurrence was achieved. A randomized comparative study of the HP method to Hemoclips has shown similar rates of initial hemostasis, emergency surgery, and mortality rates within 30 days; although clips relate to significantly lower hemorrhage recurrence rate, RBC transfusions, and shorter patient stay in hospital.<sup>51</sup>

### ***Dieulafoy damages***

In the only prospective randomized study which has compared mechanical methods (clips, bands) to sclerotherapy, hemorrhage recurrence rates have been significantly lower using the first (8% to 33% respectively).<sup>52</sup>

### ***Esophageal Varices***

A meta-analysis of 7 studies comparing ligation of esophageal varices using elastic rings (EVL) to esophageal varices sclerotherapy in 547 patients has shown reduction of hemorrhage recurrence, of local complications, of subsequent required sessions, of mortality rates due to reappearance of hemorrhage, and of mortality rates in patients who had been subject to esophageal varices ligation.<sup>53</sup> Three following randomized studies have shown similar effectiveness in active hemorrhage control.<sup>54-56</sup>

The EVL method has been related to fewer sessions, less local complications, but to higher varices recurrence.

In an attempt to lower varices recurrence rates, a combination of EVL with EVS at a low dosage has been tried; however, comparative studies have not shown any advantages in comparison to EVL alone.<sup>56,57</sup>

## **SAFETY**

### ***MPEC***

Rare cases of peptic ulcer trespis have been reported when implementing the MPEC method; hemorrhage aggravation has also been reported at a rate up to 18%. Trespis of the large intestine during treatment of angiodysplasias, particularly of the ascending colon can occur in 2,5% of the cases.<sup>34</sup> Hard pressure on the area should be avoided.

### ***Heater Probe***

Trespis rate varies from 1.8% to 3%, and hemorrhage deterioration has been reported at a rate of up to 5%.<sup>58,59</sup>

### ***APC***

Rare complications, caused by the implementation of APC method for hemostasis, have rarely been reported in the literature and include the following:

Argon meteorism / tympanism, subcutaneous emphysema, pneumomediastinum, pneumoperitoneum, and trespis.<sup>60</sup>

Complications may be related either to intensity of settings, duration of implementing the method or to the distance from the target tissue.

### ***Laser***

Trespis rates after hemorrhage treatment using Nd:YAG method have been reported to be up to 2.4%. Hemorrhage deterioration can occur at a rate of up to 29%; tympanism due to the frequency of gas in the intestinal cavity.<sup>59</sup>

### ***Sclerotherapy***

Complications of sclerotherapy - when used for hemorrhage with non-varix etiology/ cause - are rare. Adrenaline use has been reported to have cardiac arrhythmias as a complication. Complications of sclerotherapy are more frequent when used for esophageal varices treatment and they occur in up to 50% of the patients.<sup>61</sup> These complications are divided into local, such as post-sternum ache, dysphagia, odynophagia painful deglutition / aching swallowing, ulcerations, stenosis, hemorrhage and trespis, and systemic, such as fever, bacteremia, sepsis, fluid in pleural cavity, pneumonia, and ARDS.

### ***Ring Ligation/ Ligature***

Complications that have been reported after EVL include local complications, such as post-sternum ache, esophageal ulcers, ulcer hemorrhage and stenosis; however, the above are not common.

Systemic complications, such as bacteremia, bacterial origin peritonitis, and lung infections, have been reported at lower rates compared to complications of sclerotherapy.<sup>62,63</sup>

### ***Hemoclips***

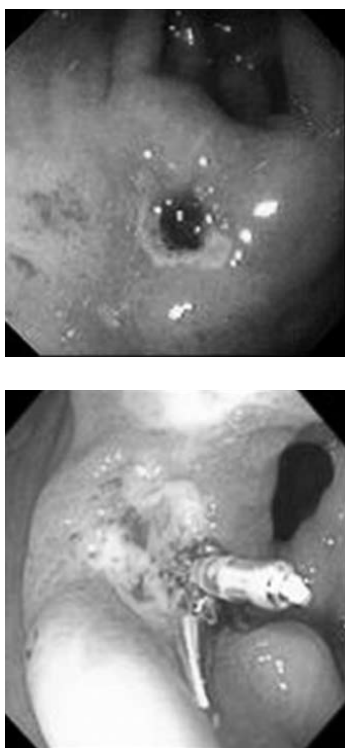
No complications have been reported in the limited existing relevant literature.

### ***Loops***

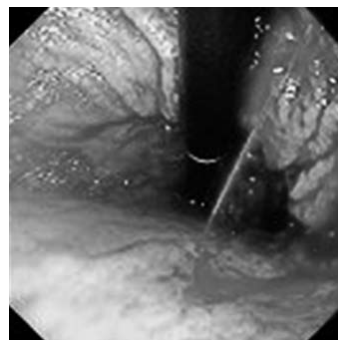
Unintentional intersection of the pedicle / pedicle of a polyp by the removing loop and also hemorrhage following that have been reported,<sup>26</sup> but relevant evidence is limited.

### Our Findings

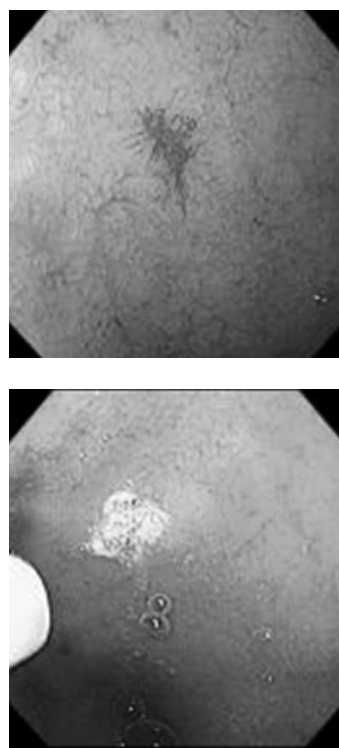
In the Endoscopy Department of the Gastroenterology Ward of “G. Papanikolaou” Hospital, 1.087 patients have undergone upper gastrointestinal tract endoscopy, after being diagnosed with upper gastrointestinal system hemorrhage, during the years 2000-2005. Endoscopic hemostasis was conducted in 200 of those patients with hemorrhage without esophageal varices. 82 patients (42%) had duodenal ulcer, 69 (35%) patients had stomach ulcer (fig. 1), 22 (11%) patients had anastomotic ulcer, 10 (5%) patients had Dieulafoy damage (fig. 2), 10 (5%) patients had angiectasis of the gastric antrum (GAVE), 4 patients had esophageal ulcer, 2 patients had stomach lymphoma, 1 patient had Mallory – Weiss syndrome and 1 patient had aorto-enteric fistula. In 185 patients adrenaline was infused 1:10000 and/or ethanolamine via a sclerotherapy needle. In 8 patients adrenaline infusion was combined with placement of a hemostatic clip (Resolution Clip, Boston Scientific) and in 7 patients Argon Plasma Coagulation was implemented (fig. 3). In 14 patients hemorrhage recurrence was observed and a second endoscopic hemostasis was conducted, while 3 patients had to be operated. Varices rupture was discovered in 75 patients and all underwent ligation of varices, using elastic rings



**Fig. 1.** Bleeding pre pyloric ulcer with a visible vessel and placement of hemostatic clips.



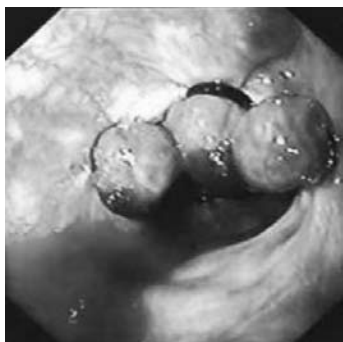**Fig. 2.** Arterial hemorrhage (spurting) due to Dieulafoy damages.



**Fig. 3.** Applying Argon Plasma Coagulation in stomach angiodysplasia.

(Speedband™ Supeview Super7, Boston Scientific), while in 4 of them sclerotherapy took place (fig. 4). Hemostasis was successful in all esophageal varices rupture cases, followed by 68 more sessions (Mean: 1,9 sessions / patient) in order to achieve full treatment of varices.

Our findings, which are about to be announced / reported at the 26<sup>th</sup> Pan-hellenic Congress of Gastroenterology in Athens, November 2006, are in accordance with international literature and support evidence regarding the significant contribution of endoscopic techniques of



**Fig. 4.** Esophageal varices looped by elastic rings.

hemostasis in controlling upper gastrointestinal tract hemorrhage resulting in the almost total avoidance of operative intervention.

## REFERENCES

1. Yavorski RT, Wong RK, Maydonovitch C, Battin LS, Furnia A, Amundson DE. Analysis of 3,294 cases of upper gastrointestinal bleeding in military medical facilities. *Am J Gastroenterol* 1995; 90:568-573.
2. Wilcox CM, Alexander LN, Cotsonis G. A prospective characterization of upper gastrointestinal hemorrhage presenting with hematochezia. *Am J Gastroenterol* 1997; 92:231-235.
3. Arasaradnam RP, Donnelly MT. Acute endoscopic intervention in non-variceal upper gastrointestinal bleeding. *Postgrad Med J* 2005;81:92-8
4. Rockall TA, Logan RFA, Devlin HB, et al. Incidence of and mortality from acute upper gastrointestinal haemorrhage in the United Kingdom. *BMJ* 1995; 311:222-226.
5. Erstad BL. Proton-pump inhibitors for acute peptic ulcer bleeding. *Ann Pharmacother* 2001; 35:730-740.
6. Sung JJ, Chan FK, Lau JY, Yung MY, Leung WK, Wu JC, et al. The effect of endoscopic therapy in patients receiving omeprazole for bleeding ulcers with nonbleeding visible vessels or adherent clots: a randomized comparison. *Ann Intern Med* 2003; 139:237-243.
7. Lin HJ, Perng CL, Wang K, Lee CH, Lee SD. Octreotide for arrest of peptic ulcer hemorrhage: a prospective, randomized controlled trial. *Hepatogastroenterology* 1995; 42:856-860.
8. Chak A, Cooper GS, Lloyd LE, Kolz CS, Barnhart BA, Wong RC. Effectiveness of endoscopy in patients admitted to the intensive care unit with upper GI hemorrhage. *Gastrointest Endosc* 2001; 53:6-13.
9. Lin HJ, Wang K, Perng CL, Chua RT, Lee FY, Lee CH, et al. Early or delayed endoscopy for patients with peptic ulcer bleeding. A prospective randomized study. *J Clin Gastroenterol* 1996; 22:267-271.
10. Forrest JAH, Finlayson NDC, Shearman DJV. Endoscopy in gastrointestinal bleeding. *Lancet* 1974; 394:392
11. Savides TJ, Jensen DM. Therapeutic endoscopy for non-variceal gastrointestinal bleeding. *Gastroenterol Clin North Am* 2000;29:465-87.
12. Johnson JH. Endoscopic risk factors for bleeding peptic ulcer. *Gastrointest Endosc* 1990;36(Suppl 5):S16-20.
13. Bleau BL, Gostout CJ, Sherman KE, Shaw MJ, Harford WV, Keate RF, et al. Recurrent bleeding from peptic ulcer associated with adherent clot: a randomized study comparing endoscopic treatment with medical therapy. *Gastrointest Endosc* 2002; 56:1-6.
14. Kovacs ToC, Jensen TM. Therapeutic endoscopy in upper gastrointestinal bleeding. In Tayler MB, Gollan JL, Steer ML, Wolfe MM, editors. *Gastrointestinal emergencies*. 2nd ed, Baltimore: Williams and Wilkins 1997, 181-198.
15. Gilbert DA, Silvestein FG, Tedesco FJ. National ASGE Survey on upper gastrointestinal bleeding. Complications of endoscopy. *Gastrointestinal disease and Science* 1981; 26 (suppl) 7:555-595.
16. Laine L. Multipolar electrocoagulation in the treatment of peptic ulcers with nonbleeding visible vessels: a prospective, controlled trial. *Ann Int Med.* 1989; 110:510-514
17. Jensen DM, Machicado GA, Jutaha R, Kovacs TOG. Urgent colonoscopy for the diagnosis and treatment of severe diverticular hemorrhage. *N Engl J Med.* 2000; 342:78-82
18. Harrison JD, Morris DL. Does bipolar electrocoagulation time affect vessel weld strength. *Gut.* 1991; 32:188-190
19. Laine L. Bipolar/multipolar electrocoagulation. *Gastrointest Endosc.* 1990;36(Suppl):S38-S41
20. Fullarton GM, Birnie GG, Macdonald A, Murray WR. Controlled trial of heater probe treatment in bleeding peptic ulcers. *Br J Surg.* 1989; 76:541-544
21. Watson JP, Bennett MK, Griffin SM, Matthewson K. The tissue effect of argon plasma coagulation on esophageal and gastric mucosa. *Gastrointest Endosc.* 2000; 52:342-345
22. Nelson DB, Bosco JJ, Curtis WD, Faigel DO, Kelsey PB, Leung JW, et al. Injection needles. *Gastrointest Endosc.* 1999; 50:928-931
23. El-Newihi HM, Achord JL. Emerging role of endoscopic variceal band ligation in the treatment of esophageal varices. *Dig Dis.* 1996; 14:201-208
24. Slosberg EA, Keeffe EB. Sclerotherapy versus banding in the treatment of variceal bleeding. *Clin Liver Dis.* 1997; 1:77-84
25. Hachisu T. Evaluation of endoscopic hemostasis using an improved clipping apparatus. *Surg Endosc.* 1998; 2:13-17
26. Matsushita M, Hajiro K, Takawuwa H, Kusumi F, Maruo T, Ohana M, et al. Ineffective use of a detachable snare for colonoscopic polypectomy of large polyps. *Gastrointest Endosc;* 47:496-499.
27. Cook DJ, Guyatt GH, Salena BJ, Laine LA. Endoscopic therapy for acute nonvariceal upper gastrointestinal hemorrhage: a meta-analysis. *Ann Intern Med.* 1992; 123:280-287
28. Sacks HS, Chalmers TC, Blum AL, Berrier J, Pagano D. Endoscopic hemostasis: An effective therapy for bleeding peptic ulcers. *JAMA.* 1990; 254:494-499
29. Fullarton GM, Birnie GG, Macdonald A, Murray WR. Con-



- trolled trial of heater probe treatment in bleeding peptic ulcers. *Br J Surg*. 1989; 76:541-544
30. Lin HJ, Perng CL, Wang K, Lee SD, Lee CH. Long-term results of heater probe thermocoagulation for patients with massive peptic ulcer bleeding: a prospective observation. *Am J Gastroenterol*. 1995; 90:44-47
31. Petrini Jr JL, Johnston JH. Heat probe treatment for antral vascular ectasia. *Gastrointest Endosc*. 1989; 35:324-328
32. Norton ID, Petersen BT, Sorbi D, Balm RK, Alexander GL, Gostout CJ. Management and long-term prognosis of Dieulafoy lesion. *Gastrointest Endosc*. 1999; 50:762-767
33. Fantin AC, Binek J, Suter WR, Meyenberger C. Argon beam coagulation for treatment of symptomatic radiation-induced proctitis. *Gastrointest Endosc*. 1999; 49:515-518
34. Kaassis M, Oberti F, Burtin P, Boyer J. Argon plasma coagulation for the treatment of hemorrhagic radiation proctitis. *Endoscopy*. 2000; 32:673-676
35. Prakash C, Chokshi H, Walden DT, Aliperti G. Endoscopic hemostasis in acute diverticular bleeding. *Endosc*. 1999; 31:460-463
36. Foutch PG. Angiodysplasia of the gastrointestinal tract. *Am J Gastroenterol*. 1993; 88:807-818
37. Morris AJ, Mokhashi M, Straiton M, Murray L, Mackenzie JF. Push enteroscopy and heater probe therapy for small bowel bleeding. *Gastrointest Endosc*. 1996; 44:394-397
38. Chung SC, Leung JW, Steele RJ, Crofts JJ, Li AK. Endoscopic injection of adrenaline for actively bleeding ulcers: a randomized trial. *Br Med J*. 1988; 296:1631-1633
39. Panes J, Viver J, Forine M, Garcia-Olivaris E, Marco C, Garan J. Controlled trial of endoscopic sclerosis in bleeding peptic ulcers. *Lancet*. 1987; 2:1292-1294
40. ASGE Standards of Practice Committee. The role of endoscopic therapy in the management of variceal hemorrhage. *Gastrointest Endosc*. 1998; 48:697-698
41. Binmoeller KF, Borsatto R. Variceal bleeding and portal hypertension. *Endoscopy*. 2000;32:189-199
42. Stiegmann GV, Goff JS, Sun JH, Hruza D, Reveille RM. Endoscopic ligation of esophageal varices. *Am J Surg*. 1990; 159:21-25
43. Campo R, Brullet E. Endoscopic treatment of gastric angiodysplasia with elastic band ligation. *Gastrointest Endosc*. 1996; 43:502-504
44. Brown GR, Harford WV, Jones WF. Endoscopic band ligation of an actively bleeding Dieulafoy lesion. *Gastrointest Endosc*. 1994; 40:501-503
45. Ohta S, Yukioka T, Ohta S, Miyagatani Y, Matsuda H, Shimazaki S. Hemostasis with endoscopic hemoclipping for severe gastrointestinal bleeding in critically ill patients. *Am J Gastroenterol*. 1996; 91:701-704
46. Yamaguchi Y, Yamato T, Katsumi N, Morozumi K, Abe T, Ishida H, et al. Endoscopic hemoclipping for upper GI bleeding due to Mallory-Weiss syndrome. *Gastrointest Endosc*. 2001; 53:427-430
47. Lin HJ, Wang K, Perng CL, Lee CH, Lee SD. Heater probe thermocoagulation and multipolar electrocoagulation for arrest of peptic ulcer bleeding: a prospective, randomized comparative trial. *J Clin Gastroenterol*. 1995; 21:99-102
48. Lin HJ, Tseng GY, Perng CL, Lee FY, Chang FY, Lee SD. Comparison of adrenaline injection and bipolar electrocoagulation for the arrest of peptic ulcer bleeding. *Gut*. 1999; 44:715-719
49. Lin HJ, Tsai YT, Lee SD, Lai KH, Lee FY, Lin Cy, et al. A prospectively randomized trial of heat probe thermocoagulation versus pure alcohol injection in nonvariceal peptic ulcer hemorrhage. *Am J Gastroenterol*. 1988; 83:283-286
50. Carter R, Anderson JR. Randomized trial of epinephrine injection and laser photocoagulation in the control of hemorrhage from peptic ulcer. *Br J Surg*. 1994; 81:869-871
51. Cipolletta L, Bianco MA, Marmo R, Rotondano G, Piscopo R, Vingiani AM, et al. Endoclips versus heater probe in preventing early recurrent bleeding from peptic ulcer: a prospective randomized trial. *Gastrointest Endosc*. 2000; 53:147-151
52. Chung IK, Kim EJ, Lee MS, Kim HS, Park SH, Lee MH, et al. Bleeding Dieulafoy's lesions and the choice of endoscopic method: comparing the hemostatic efficacy of mechanical and injection methods. *Gastrointest Endosc*. 2000; 52:721-724
53. Laine L, Cook D. Endoscopic ligation compared with sclerotherapy for treatment of esophageal variceal bleeding: a meta-analysis. *Ann Intern Med*. 1995; 123:280-287
54. Hou MC, Lin HC, Kuo BIT, Chen CH, Lee FY, Lee SD. Comparison of endoscopic variceal injection sclerotherapy and ligation for the treatment of esophageal variceal hemorrhage: a prospective randomized trial. *Hepatology*. 1995; 21:1517-1522
55. Sarin SK, Govil A, Jain AK, Jain AK, Guptan RC, Issar SK, et al. Prospective randomized trial of endoscopic sclerotherapy versus variceal band ligation for esophageal varices: influence on gastropathy, gastric varices and variceal recurrence. *J Hepatol*. 1997; 26:826-832
56. Baroncini D, Milandri GL, Borioni D, Piemontese A, Cennamo V, Billi P, et al. A prospective randomized trial of sclerotherapy versus ligation in the elective treatment of bleeding esophageal varices. *Endoscopy*. 1997; 29:235-240
57. Laine L, Stein C, Sharma V. Randomized comparison of ligation versus ligation plus sclerotherapy in patients with bleeding esophageal varices. *Gastroenterology*. 1996; 110:529-533
58. Chung SC, Leung JW, Sung JY, Lo KK, Li AK. Injection or heat probe for bleeding ulcer. *Gastroenterology*. 1991; 100:33-37
59. Matthewson K, Swain CP, Bland M, Kirkham JS, Brown SG, Northfield TC. Randomized comparison of ND YAG laser, heater probe, and no endoscopic therapy for bleeding peptic ulcers. *Gastroenterology*. 1990; 98:1239-1244
60. Wahab PJ, Mulder CJJ, den Hartog G, Thies JE. Argon plasma coagulation in flexible gastrointestinal endoscopy: pilot experiences. *Endoscopy*. 1997; 29:176-181
61. Stevens PD, Lebowohl O. Hypertensive emergency and ventricular tachycardia after endoscopic epinephrine injection of a Mallory-Weiss tear. *Gastrointest Endosc*. 1994; 40:77-78
62. Saeed ZA. Endoscopic therapy of bleeding esophageal varices: ligation is still the best. *Gastroenterology*. 1996;

- 110:635-638
63. Djurdjevic D, Janosevic S, Dapcevic B, Vukcevic V, Djordjevic D, Svorcan P, et al. Combined ligation and sclerotherapy versus ligation alone for eradication of bleeding esophageal varices: a randomized and prospective trial. *Endoscopy*. 1999; 31:286-290