

Delayed perforation after gastric endoscopic submucosal dissection can be treated by using over-the-scope clips

Mitsuhiro Kono, Takashi Kanesaka, Akira Maekawa, Noriya Uedo

Osaka International Cancer Institute, Osaka, Japan

A 70-year-old man underwent endoscopic submucosal dissection (ESD) for a small mucosal adenocarcinoma on the posterior wall of the angular incisure of the stomach. The lesion was removed completely without any complications. The next morning, the patient experienced severe abdominal pain of sudden onset and was found to have tenderness in the upper abdomen. Computed tomography showed free air without fluid collection in the abdominal cavity. Emergency endoscopy was performed 3 h after the onset of the pain. A 10-mm perforation was found on the post-ESD wound (Fig. 1) and was completely closed with 2 over-the-scope-clips (OTSC; Ovesco Endoscopy, Tübingen, Germany) (Fig. 2). No extraluminal leak of diatrizoate meglumine was detected during upper gastrointestinal examinations on post-procedural day 5. The patient started food intake on post-procedural day 6 and was discharged on post-procedural day 15. The OTSCs were visible at the scar on surveillance endoscopy 2 months later. Most patients with delayed perforation require emergency surgery [1,2]. Patients with localized peritonitis may respond to conservative therapy [1,3], but how to close a large and vulnerable perforation remains an issue. In this patient, the perforation site was completely closed with the OTSCs before severe pan-peritonitis had developed, thus avoiding emergency surgery.

Department of Gastrointestinal Oncology, Osaka International Cancer Institute, Osaka, Japan

Conflict of Interest: None

Correspondence to: Takashi Kanesaka, MD, Department of Gastrointestinal Oncology, Osaka International Cancer Institute, 3-1-69, Otemae, Chuo-ku, Osaka, 541-8567, Japan, e-mail: takashikanesaka@gmail.com

Received 13 May 2019; accepted 5 June 2019; published online 6 July 2019

DOI: <https://doi.org/10.20524/aog.2019.0398>

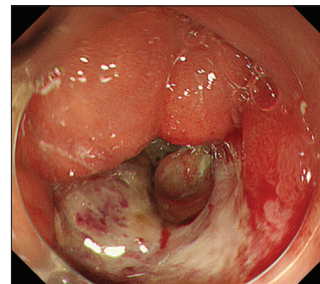


Figure 1 Endoscopic image of delayed perforation. A 10-mm perforation was found on the wound after endoscopic submucosal dissection

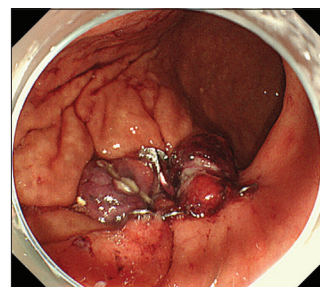


Figure 2 Endoscopic image obtained after closure with 2 over-the-scope-clips

References

1. Hanaoka N, Uedo N, Ishihara R, et al. Clinical features and outcomes of delayed perforation after endoscopic submucosal dissection for early gastric cancer. *Endoscopy* 2010;**42**:1112-1115.
2. Yano T, Tanabe S, Ishido K, et al. Delayed perforation after endoscopic submucosal dissection for early gastric cancer: Clinical features and treatment. *World J Gastrointest Endosc* 2016;**8**:368-373.
3. Ikezawa K, Michida T, Iwahashi K, et al. Delayed perforation occurring after endoscopic submucosal dissection for early gastric cancer. *Gastric Cancer* 2012;**15**:111-114.