

## Case report

**Sclerosing encapsulating peritonitis – mesenteritis. A case report**

M.L. Lorentziadis, I.K. Poulantzas

**SUMMARY**

Sclerosing encapsulating peritonitis is a rare condition of unknown cause with reported high mortality and morbidity. It is treated surgically and it is difficult to diagnose preoperatively since it has no specific imaging findings. We present a case report of idiopathic sclerosing encapsulating peritonitis-mesenteritis with a literature review on this pathologic entity.

Sclerosing encapsulating peritonitis-mesenteritis is an intestinal wall lesion which causes obstructive bowel symptoms. The idiopathic expression of the disease is a rare entity which is treated surgically as there are several operative options. The management of the sclerosing encapsulating peritonitis-mesenteritis is followed by a complication rate of 38%-90% and a mortality rate of 60%-71%.<sup>1</sup>

**Key words:** Sclerosing peritonitis, mesenteritis, encapsulating peritonitis

**CASE REPORT**

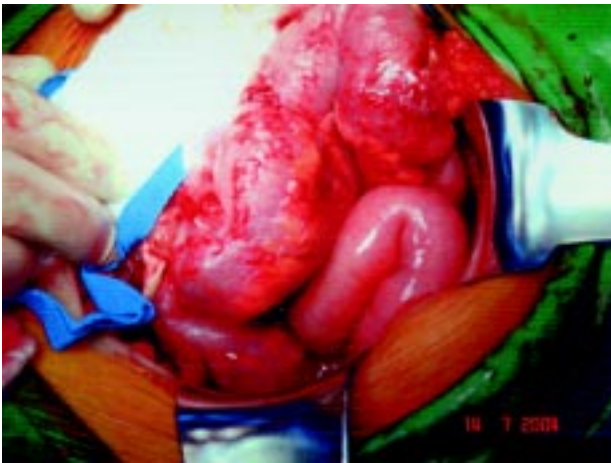This 62 years old woman was operated due to a post operative hernia at the site of a right infra umbilical paramedian incision. The patient reported recurrent episodes of partial subacute enteric obstruction with diffuse pain, nausea and seccation of caudal transport of air and feces. These episodes were spontaneously resolved and occurred several times annually, although the patient was usually constipated. The patient also reported loss of three to four kilograms of body weight in the last six years. In her past history, she was operated on four years ago for acute appendicitis and she was under no medication. On admis-

sion physical examination showed a postoperative hernia on a right infra umbilical incision with no palpable mass. Digital rectal examination was normal. Blood analysis and biochemistry were normal. Colonoscopy showed orifices of diverticulae at the sigmoid colon but the instrument could not proceed deeper due to inability to dilate the wall of the descending colon. Therefore a virtual CT SCAN colonoscopy with terminal ileoscopy was performed in order to examine the whole large bowel. The examination showed no entire pathologic findings.

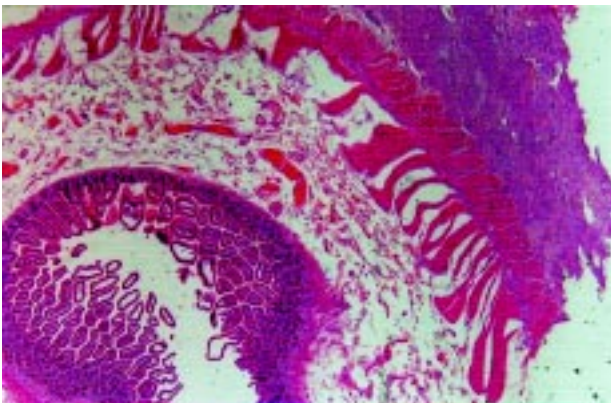
The abdominal cavity was entered through the right infra umbilical paramedian incision in order to restore the postoperative hernia. Entering the abdomen the enteric loops of the terminal ileus were densely plicated with intense adhesions forming a widely adhered membrane and abnormal thickening of the wall extending for 50cm proximal to the ileocecal valve (fig. 1). The mesentery of the abnormal enteric segment was also involved. This diseased part of the terminal ileus was considered to be the cause of the obstructive symptomatology of the patient and it was removed en block. The continuity of the gastrointestinal track was restored with an end to side ileotransverse anastomosis in two layers. The incision was closed and the hernia was repaired without a mesh placement. Histopathology of the excised specimen (fig. 2,3) showed small bowel characterized by extended focally distributed fibrosis and thickening of the serosa and of the mesenteric fat tissue due to development of newly formed fibroblastic tissue consisting of spindle like cells with collagen fibers in between and small arteries characterized by thickening and hyaline degeneration of their wall. The CD 117 (c-kit) antibody was positive in almost all neoplastic cells. The diagnosis was sclerosing encapsulating peritonitis.

The postoperative course was uneventful and the patient was discharged from the hospital after a week. During the 20 months follow up the patient is free of symptoms.

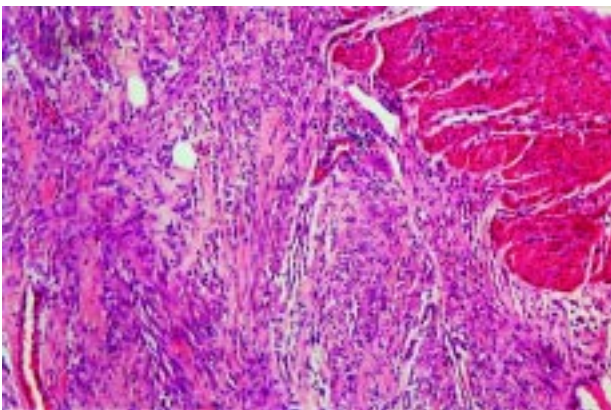
Author for correspondence:  
M. Lorentziadis, 141 Patision Ave., Athens GR 112 51,  
Tel.: +2108661465, Fax: 2108620202, mobile: 6932478646,  
e-mail: mloren@panafonet.gr



**Fig. 1.** Operative findings: Note the angulation of the loops of the small bowel with obvious the pathology of the enteric wall.



**Fig. 2.** Small intestine with presence of newly formed fibroblastic tissue at the perienteric space of the mesentery (magnification 10x0,25)



**Fig. 3.** Figure 2 under higher magnification (magnification 4x0,1)

## DISCUSSION

Idiopathic sclerosing encapsulating peritonitis-mesenteritis is a rare disease, which can be defined as the presence of a secondary thick fibrotic, newly formed membrane which envelops the small intestinal loops to various degrees.<sup>1,2</sup> Usually it causes obstructive symptoms at the small bowel with abdominal pain, weight loss and sometimes a palpable abdominal mass or intractable ascites.<sup>3</sup> The etiology of the disease is unknown. Diseases that can give a similar pathology include sarcoidosis, abdominal tuberculosis, familial Mediterranean fever, intraperitoneal chemotherapy, liver transplantation, gastrointestinal malignancy, luteinised ovarian thecoma, chronic peritoneal dialysis and b-blocker treatment.<sup>4</sup> However the above entities are different from the idiopathic sclerosing peritonitis-mesenteritis since the observed lesions are secondary to the primary pathology. The incidence is equal between male and female and between various age groups. Although it was originally described in tropical and subtropical regions. It can occur in several regions of the world. Usually the diagnosis is suspected only during the laparotomy from the findings since the preoperative diagnosis is difficult due to non-specific imaging findings such as delayed transit, ascites, reactive lymphadenoma and thickening of the intestinal loops.<sup>5</sup> Histopathologically the sclerosing encapsulated peritonitis is characterized by the presence of fibrotic thickening and accentuation of the lobular pattern of the peritoneal fat. The fibrous tissue may be arranged in a fascicular or storiform pattern or may be hyalinised. Focal collections of chronic inflammatory cells, surface fibrin deposition and focal hyperplasia of the overlying mesothelial cells may also be present.<sup>6</sup> Immunoreactivity for CD 117 (c-Kit) is positive in most of the cells (86%-100%). Some authors now make CD 117 positivity an absolute requirement for the definition of this disease.<sup>7</sup> It seems that the CD 117 (+) cells are mesenteric stem cells that originate from the serosa, proliferated, then differentiated into myofibroblasts or fibroblasts, producing collagen and hyaluronic acid in the matrix, leading to the gradual formation of the sclerosing encapsulated peritonitis.<sup>8</sup>

There are several operative treatment options proposed such as enterolysis, partial excision an anastomosis or stripping of the adhesive membranes from the intestinal loops.<sup>9</sup> The postoperative complication rate ranges between 38%-90%<sup>1</sup> which increases the mortality rate to 60%-71%. In the literature little is known of late results. The incidence of persistent obstruction in the literature

ranges from 0-0,15%<sup>1</sup> accomplishing a very satisfactory postoperative result in resolving the symptomatology.

## REFERENCES

1. Celicont B., Levend H., Hay J., et al. Sclerosing encapsulating peritonitis: Early and late results of surgical management in 32 cases. *Dig Surg* 1998; 15:697-702.
2. Wilmoth P., Patel J. La peritonite chronique encapsulante. *J Chir* 1931 ; 37 :341-357.
3. Sieck J.O., Cowgill R., Larkworthy N. Peritoneal encapsulation and abdominal cocoon: Case report and review of the literature. *Gastroenterology* 1983; 84:1597-1601.
4. Slim R., Tohne C., Yaghi C, et al. Sclerosing encapsulating peritonitis: A diagnostic dilemma. *J Am Coll Surg* 2005; 200:974-975.
5. Campbell S., Clarke P., Hawley C, et al. Sclerosing peritonitis: Identification of diagnostic, clinical and radiologic features. *Am J Kidney Dis* 1994; 24:819-825.
6. Nafussi A., Wong W. Intra-abdominal spindle cell lesions: a review and practical aids to diagnosis. *Histopathology* 2001; 38:387-402.
7. Rosai J. Rosai and Ackerman's *Surgical Pathology* 9<sup>th</sup> ed. Philadelphia, Mosby 2004: 678.
8. Ohmori T, Ohnishi S, Okada K, Arita N. Sclerosing encapsulated peritonitis and non-occlusive mesenteric infarction found at autopsy in a man who had undergone continuous ambulatory peritoneal dialysis: a histochemical and immunohistochemical study. *Pathol Int* 2000; 50:660-666.
9. Kittur D.S., Korpe S.W., Raych R.E., et al. Surgical aspects of sclerosing encapsulating peritonitis. *Arch Surg* 1990; 125:1626-1628.