

Review

EUS and Common bile duct stones

Christine Bergele¹, M. Giovannini²**SUMMARY**

Cholelithiasis is a common disorder, especially in patients older than 60 years, as common bile duct stones may be present in 15% to 60% of cases in this special sample of population. Until recently, endoscopic retrograde cholangiography (ERC), which is a very reliable method for visualizing and extracting gallstones in the same session, was considered the gold-standard for suspected cholelithiasis; however the not negligible complication rate of diagnostic and therapeutic ERC has led to the evolution of EUS. EUS has proved to be of great sensitivity (up to 97%) for detecting even tiny stones that can easily be masked by contrast medium during ERCP, without any complications related to the procedure, and with a NPV reaching 100%, meaning that it can accurately and safely identify patients with cholelithiasis and thereby avoid inappropriate instrumental exploration of the duct.

Key words: EUS, cholelithiasis, biliary pancreatitis

INTRODUCTION

Endoscopic ultrasonography (EUS) is a minimally invasive technique with low morbidity¹ and proven efficacy in the diagnosis of pancreatic diseases, especially of diseases involving the head of the pancreas.²⁻⁴ EUS has also proved effective in the diagnosis of extrahepatic cholestasis.⁵⁻⁷ It has a high sensitivity and specificity for detection of common bile duct stones,⁸⁻¹¹ equal to or

better than that of endoscopic retrograde cholangiopancreatography (ERCP), without the risks of ERCP-related pancreatitis. These results were discussed in detail by Laurent Palazzo⁸ during the 13th International Symposium on Endoscopic ultrasonography, which took place in New York on October 2002.

Cholelithiasis occurs in 15% to 20% of patients with symptomatic cholelithiasis. The incidence of bile duct stones increases with age; up to 25% of the elderly have calculi in the bile duct at the time of cholecystectomy.¹² Several investigators, comparing the efficacy of EUS with that of ultrasonography (US), computed tomography (CT) and ERCP in the diagnosis of CBD stones^{10,13-19} have reported high rates of sensitivity (>88%) and specificity (>95%). In the present report, we overview recently published data showing the efficacy, sensitivity and specificity of EUS, versus other imaging modalities, in the diagnosis of CBD stones.

EUS VERSUS TRANSABDOMINAL ULTRASONOGRAPHY (US)

Transabdominal ultrasonography (US) is routinely performed to identify a biliary etiology of pancreatitis. US is an accurate method for diagnosing cholelithiasis,²⁰ but with low sensitivity in the detection of CBD stones. In a prospective multicenter study from USA²¹ with 36 patients, Chak et al demonstrated the ability of EUS to identify cholelithiasis compared with US. The reported sensitivity, specificity and accuracy were 91%, 100%, 97% and 50%, 100% and 83% respectively. The body habitus and the interference from bowel gas in the duodenum were mostly responsible for the low sensitivity of US in detecting common bile duct stones. In addition, the positive and negative predictive values of EUS were 100% and 95% while those of US were 100% and 74% respectively. The superiority of EUS over US has also been demonstrated in previous studies.^{10,11}

¹Gastroenterologist Scholarship of Hellenic Society of Gastroenterology, 2003 Trainee in Endoscopic Ultrasonography in Institut Paoli-Calmette, Marseille, France, ²Gastroenterologist-Oncologist Chief of the Endoscopic Unit in Institut Paoli-Calmette, Marseille, France

Author for correspondence:

Christine Bergele, 30 School Str., GR-153 42 Athens, Greece,
Tel.: 210 6394420, e-mail: chbspi@hotmail.com

Even though US is traditionally used to detect stones in the gallbladder with accuracy and sensitivity rates ranging from 92% to 96%, it has been suggested that EUS is superior to US even for imaging the gallbladder, because of the higher ultrasound frequencies (7.5, 12 and 20 MHz), which permit the demonstration of the layered structure of the gallbladder wall and provide high-resolution images of small stones (<3mm).²² The ability to recognize biliary “sludge” or very small stones located in the gallbladder infundibulum with EUS, which cannot be visible with conventional ultrasonography is very important as it may change the diagnostic yield and therapeutic management, especially in cases of acute pancreatitis which were incorrectly classified as idiopathic pancreatitis.²³⁻²⁴

EUS VERSUS COMPUTED TOMOGRAPHY (CT)

Although CT is characterized by a higher sensitivity than US in detection of bile duct stones (approximately 70%),^{10,16,18} this rate is significantly lower than that of EUS (96%), which additionally is not affected by the size of the stones and bile duct diameter. Moreover, the development of spiral CT has not so far succeeded proving its possible superiority to EUS, with sensitivity, specificity and accuracy varying between 85-88%, 88-97% and 86-94% respectively, obviously inferior to those of EUS, as previously given.^{25,26} The need for a contrast medium is a further drawback of CT. Despite the advantages reported above in relation to CT, EUS seems to be inadequate in examining the intrahepatic biliary tree, which may result in false-negative results when looking for intrahepatic ductal stones. In this case, CT may be required for the diagnosis of hepatolithiasis.

EUS VERSUS MICROSCOPIC EXAMINATION OF DUODENAL BILE

The utility of microscopic examination of duodenal aspirates for detecting biliary sludge is well established. This diagnostic modality is most important in cases of idiopathic pancreatitis where conventional methods have failed to demonstrate stones as the cause of pancreatitis. Using the method reported above, in two studies,^{27,28} authors reported a positive detection rate of 73% of microcalculi in patients with idiopathic pancreatitis. EUS enables early detection of occult cholelithiasis with a sensitivity of 96%, leading to immediate treatment by ERCP and endoscopic sphincterotomy.^{22,24} Moreover, the sensitivity of the microscopic study of aspirated bile from the gallbladder via the duodenal route after stimulation

by cholecystokinin has been shown to be 67%, much inferior to that of EUS.^{22,29}

EUS VERSUS ERCP

Endoscopic retrograde cholangiography (ERC) is considered the standard non-surgical technique for diagnosis and removal of bile duct stones at the same endoscopic session as endoscopic sphincterotomy (ES). However, ERCP presents a complication rate ranging between 3% and 6%, a figure that doubles with sphincterotomy.³⁰⁻³¹ Furthermore, even for patients with a high suspicion of choledocholithiasis, based on clinical, laboratory and radiological data, ERCP is able to demonstrate CBD stones in a percentage 27%-66%.^{15,18,32} The necessity for a less invasive imaging modality of the biliary tree, with similar sensitivity, specificity and accuracy is obvious. Several studies, comparing ERCP and EUS, have already shown the usefulness of EUS in this area.^{21,24,33-35}

A similar and not statistically significant difference for sensitivity, specificity and accuracy of both methods was reported in diagnosis of CBD stones (97%, 98%, 98% and 97%, 95% and 96% respectively). EUS has proved to be of high positive predictive value (PPV) and negative predictive value (NPV) (100% and 97% respectively),²¹ meaning that in case of a positive result for choledocholithiasis, ERCP can be selectively performed in patients with biliary pancreatitis or avoided, if EUS is negative, thus decreasing the morbidity from ERCP and sphincterotomy. This is reinforced by the study of Napoleon et al, in which patients with suspicion of CBD stones but normal EUS findings have a low risk of need for ERC in a 1-year period.³⁶ The aforementioned studies showed that ERCP can have false-negative results because of small stones located within dilated biliary ducts, whereas fewer false-negative results were recorded with EUS, and consisted mostly of stones located in the upper common hepatic duct or lying within intrahepatic ducts. Moreover, it is usual to have false-positive results when performing ERCP, because of small air bubbles introduced during cannulation and injection of contrast liquid. Both EUS and ERCP successfully image the extrahepatic bile duct in 98% and 94% of cases, respectively, with no statistical significant difference, although ERCP can have a failure rate of 5% to 10% even in experienced hands.³⁷ In addition, no complications related to EUS were noted, reinforcing the EUS-based strategy rather than the of ERCP-based strategy for the evaluation of choledocholithiasis.

EUS VERSUS MAGNETIC RESONANCE

The currently available data about the utility of magnetic resonance cholangiography (MRC) for detecting choledocholithiasis are limited, as many examination protocols exist, making the interpretation of results difficult. Comparing EUS to MRC, EUS offers higher resolution (0.1 mm vs 1.5 mm), which explains the lower sensitivity of MRC for small stones,³⁸ although this has not been based on a well-organized study. Moreover, some blind zones exist for MRC, such as the papillary and peripapillary region, which lowers even further its sensitivity in diagnosing choledocholithiasis. In most of the published studies, this sensitivity ranges from 81% to 92%, specificity from 94% to 98% and accuracy is about 94%.³⁹⁻⁴¹ The small sample size (<14 patients) is an important drawback of these studies. According to a prospective assessment of magnetic resonance cholangiopancreatography for non-invasive imaging of the biliary tree, where 146 patients underwent ERCP/MRCP procedures, the sensitivity, specificity, positive and negative predictive value for MRCP were 97.9%, 89%, 88.6% and 98.6% respectively, even for small (1-5mm) bile duct stones.⁴² A prospective study, comparing EUS and MRC, concluded in favour of EUS, proposing the performance of MRC in case of a contraindication to EUS,⁴³ whereas another study suggests that both methods are equally reliable in the diagnosis of extrahepatic biliary obstruction.⁴¹ Based on considerations other than diagnostic efficacy (such as cost, availability, lack of invasiveness and local expertise), another author favours MRCP as the diagnostic modality which should replace diagnostic ERCP.⁴⁴

EUS VERSUS IOCG

In the case of laparoscopic cholecystectomy, it could be suggested that intraoperative cholangiography (IOCG) could be performed for detecting bile duct stones. According to some prospective studies,^{34,45-47} IOCG sensitivity and specificity in diagnosing common bile duct stones are approximately 90% and 95% respectively, results that are comparable to those of EUS (92% and 97%). As EUS, IOCG was not found to be associated with any complications but weighted averages for the rates of indeterminate IOCG were set at 9%, whereas the success rate of EUS is about 97%.⁴⁸ In addition, using this approach, the treatment of choledocholithiasis is technically difficult, lengthening the duration of the procedure.^{49,50} The only theoretical advantage of IOCG compared to EUS could be the visualization of an aberrant biliary anatomy, which helps the surgeon to avoid

bile duct injuries; and even that is controversial nowadays.⁵¹

ADVANTAGES AND LIMITATIONS OF EUS

Apart from all the previously mentioned advantages of EUS (excellent performance, high sensitivity, specificity and diagnostic accuracy, no complications, diagnosis of unrecognized gallbladder microlithiasis), the lack of radiation exposure and contrast liquids makes EUS the method of choice for pregnant patients and those with contrast allergy.

EUS is able to identify co-existing anomalies of the pancreato-biliary region, which could be responsible for biliary obstruction, instead of choledocholithiasis, such as small ampullary tumours, cholangiocarcinoma, congenital bile duct or peri-ampullary abnormalities.

Furthermore, in case of acute pancreatitis, EUS could potentially provide prognostic information.^{21,52} Based upon EUS findings, such as organ size, aspect of the outer margin of pancreas, echogenicity, location, and the extent of peripancreatic fluid, a EUS score was developed, which correlated significantly with the duration of hospital stay, duration of fever, length of intensive care and CT prognostic index. Despite these encouraging data, further studies are needed to evaluate the prognostic role of EUS in acute pancreatitis.

EUS has certain limitations in the management of patients with choledocholithiasis. One of them is the inability to visualize the gallbladder when it is in an atypical anatomic location or in patients with altered gastroduodenal anatomy. Moreover, as it is difficult to move the patient during EUS, it is not possible to use positional mobility as a criterion for defining gallstones or sludge.

Like ERCP, EUS imaging for choledocholithiasis is limited in cases where the passage of the transducer into the duodenal bulb is not possible (pyloric stenosis, Billroth II anastomoses).

Another established limitation of EUS is its inability for complete visualization of the hilum^{10,35} and to facilitate right hepatic duct,¹⁵ as a result of the limited depth of penetration of echoendoscopes. Moreover, parenchymal alterations (necrosis, fluid collections, fat infiltration, calcifications) can make imaging of the retropancreatic bile duct more difficult,¹⁵ whereas previous endoscopic sphincterotomy can give rise to air artifact in the distal bile duct and inadequate visualization.¹⁴

It could be claimed that another limitation of EUS is

that it is an operator dependent method, which is, up to a point, true, as its success rate may depend on the experience of the echoendoscopist. However, it is not necessary to be highly skilled to diagnose CBD stones; it has been suggested that EUS could be performed by operators with no more than 1 year experience⁸. Furthermore, the operator-dependency of ERCP has already been mentioned, whereas for MRCP, the reception of high-quality images depends on the unit's software.

CONCLUSIONS

The current approach to patients with suspected bile duct stones is characterized by a high number of unnecessary ERC procedures. This procedure, to date is considered the "gold standard" for bile duct stones diagnosis. However, the complication rate associated with ERC is significant, approaching 6% and reaching 10% when endoscopic sphincterotomy is performed. There is also an appreciable mortality rate of 0.2% which reaches 2.2% in case of therapeutic ERC. It thus became obvious that another diagnostic modality should replace ERC for the diagnosis of choledocholithiasis, which should have the same sensitivity, specificity and accuracy as ERC, but fewer complications.

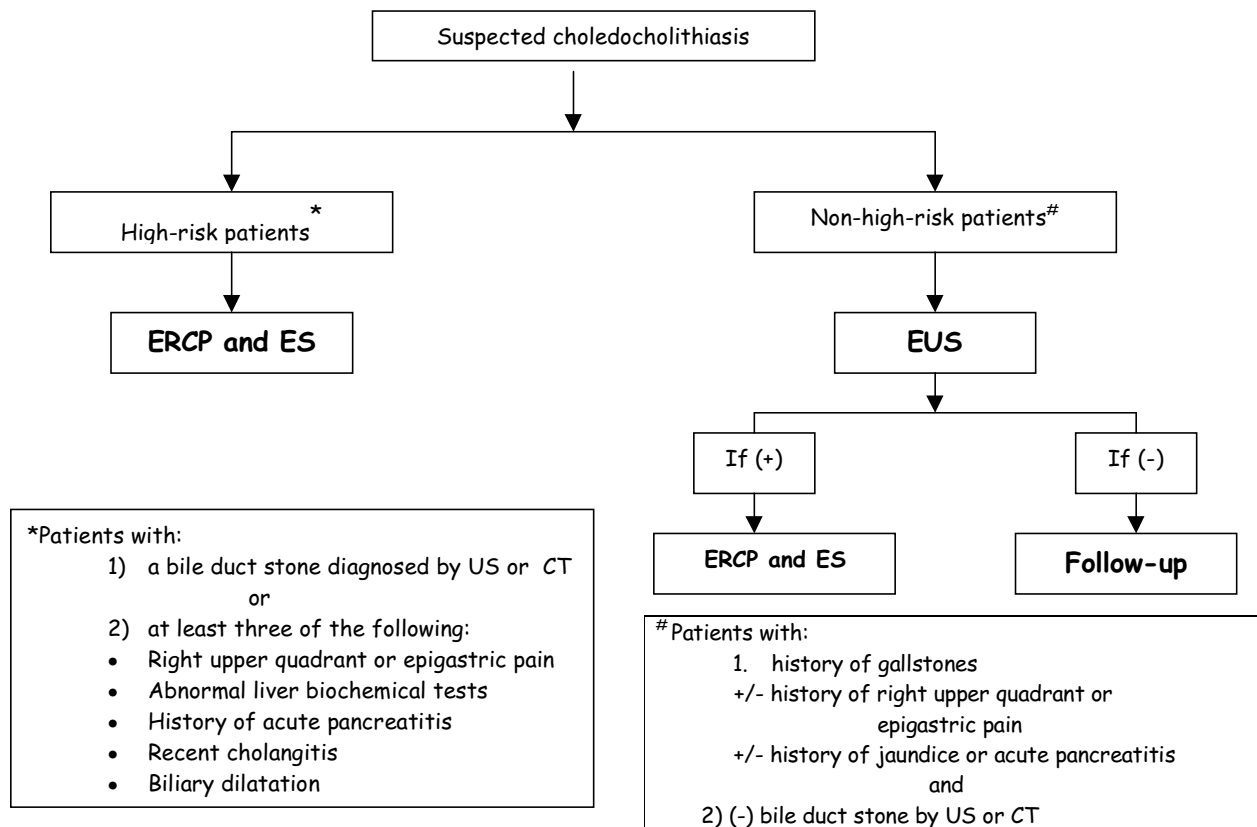
EUS has a sensitivity of 93% to 97% (much higher than US or CT), a specificity of 97% to 100%, a positive predictive value of 98% to 100% and a negative predictive value of 88% to 97% when choledocholithiasis is suspected (Table). EUS is almost as reliable as ERCP

with ES and exploration of the bile duct with baskets and extraction balloon catheters, or intraoperative exploration of the bile duct, and probably more accurate than ERCP alone. It is less invasive and significantly much safer test than ERCP. It also has important additional advantages, such as the ability to detect bile duct sludge, identification of gallstones as well as microlithiasis missed by transabdominal US, and the detection of pathologic disorders that are poorly evident at ERCP.

Thus, it would be wise to follow an EUS-based strategy for patients with suspected common bile duct stones (Figure). ERCP should be the preferred diagnostic test in high-risk patients (i.e. patients with a bile duct stone diagnosed by US or CT or with at least three of the clinical criteria, which are right upper quadrant or epigastric pain, abnormal liver biochemical tests, history of acute pancreatitis, recent cholangitis and biliary dilatation). In these patients, the benefit of ERCP outweighs the risk of ERCP-related complications. On the contrary, EUS should be the initial diagnostic test of choice in non-high-risk patients because of its high negative predictive value and safety. With a negative predictive value of 91% to 100%, EUS can accurately exclude choledocholithiasis, making ERCP unnecessary. If stones are demonstrated by EUS, ERCP with ES and stone extraction can be performed in the same session. In this way, EUS can theoretically select patients with choledocholithiasis for therapeutic endoscopic intervention and eliminate the need for diagnostic ERCP, with its potential hazards.

Table. Comparison of the available diagnostic tests for suspected choledocholithiasis

	sensitivity	specificity	PPV	NPV	accuracy
Micr. Examin. ⁸	67%				
IOCG ⁴⁸	90%	95%			
US ²¹	50%	100%	100%	74%	83%
Spiral CT ^{25,26}	85%-88%	88%-97%			86%-94%
MRCP ^{41,43}	81%-92%	94%-98%	62%	96%	94%
ERCP ^{21,24}	97%	95%	80%	94%	96%
EUS ^{21,24}	97%	98%	100%	91%-100%	97%



Comment: Patients with suspected choledocholithiasis¹⁸:

31% were classified as being high-risk patients and 69% as non-high risk patients

Non-high risk patients can further be stratified into risk groups, based on the presence of bile duct dilatation (>7 mm), fever and total bilirubin, serum alkaline phosphatase and serum alanine aminotransferase values.

Figure. The EUS-based strategy for patients with suspected common bile duct stones.

REFERENCES

1. Rosch T, Dittler HJ, Fockens P, Yasuda K, Lightdale C. Major complications of endoscopic ultrasonography: results of a survey of 42,105 cases (abstract). *Gastrointest Endosc* 1993; 39:341.
2. Rosch T, Lightdale CJ, Botet JF, et al. Preoperative localization of small pancreatic endocrine tumors by endoscopic ultrasonography. *N Engl J Med* 1992; 326:1721-1726.
3. Rosch T, Braig C, Gain T, et al. Staging of pancreatic and ampullary carcinoma by endoscopic ultrasonography. Comparison with conventional sonography, computed tomography and angiography. *Gastroenterology* 1992; 102:188-199.
4. Palazzo L, Roseau G, Gayet B, et al. Endoscopic ultrasonography in the diagnosis and staging of pancreatic adenocarcinoma. Results of a prospective study with comparison to ultrasonography and CT scan. *Endoscopy* 1993; 25:143-150.
5. Amouyal P, Palazzo L, Amouyal G, et al. Endosonography: promising method for diagnosis of extrahepatic cholestasis. *Lancet* 1989; 2:1195-1198.
6. Snady H, Coppermann A, Siegel J. Endoscopic ultrasonography compared with computed tomography with ERCP in patients with obstructive jaundice or small pancreatic mass. *Gastrointest Endosc* 1992; 38:27-34.
7. Dancygier H, Nattermann C. The role of endoscopic ultrasonography in biliary tract disease: obstructive jaundice. *Endoscopy* 1994; 26:800-802.
8. Palazzo L, O'Toole D. EUS in common bile duct stones. *Gastrointest Endosc* 2002; 56:S49-S58.
9. Clinical applications of endoscopic ultrasonography in gastroenterology state of art 1993. Results of consensus conference. *Endoscopy* 1993; 25:358-366.
10. Amouyal P, Amouyal G, Levy P. Diagnosis of choledocholithiasis by endoscopic ultrasonography. *Gastroenterology* 1994; 106:1062-1067.
11. Canto M. Endoscopic ultrasonography and gallstone disease. *Gastrointest Endosc* 1996; 43:S37-S43.
12. Hermann RE. The spectrum of biliary stone disease. *Am J Surg* 1989; 158:171-173.
13. Shim CS, Joo JH, Park CW, et al. Effectiveness of endoscopic ultrasonography in the diagnosis of choledocholithiasis. *Gastrointest Endosc* 1994; 40:1062-1067.

- thiasis prior to laparoscopic cholecystectomy. *Endoscopy* 1995; 27:428-432.
14. Palazzo L, Girollet PP, Salmeron M, et al. Value of endoscopic ultrasonography in the diagnosis of common bile duct stones: comparison with surgical exploration and ERCP. *Gastrointest Endosc* 1995; 42:225-231.
 15. Prat F, Amouyal G, Amouyal P, et al. Prospective controlled study of endoscopic ultrasonography and endoscopic retrograde cholangiography in patients with suspected common bile duct lithiasis. *Lancet* 1996; 347:75-79.
 16. Sugiyama M, Atomi Y. Endoscopic ultrasonography for diagnosing choledocholithiasis: a prospective comparative study with ultrasonography and computed tomography. *Gastrointest Endosc* 1997; 45:143-146.
 17. Norton SA, Alderson D. Prospective comparison of endoscopic ultrasonography and endoscopic retrograde cholangiopancreatography in the detection of bile duct stones. *Br J Surg* 1997; 84:1366-1369.
 18. Canto MI, Chak A, Stellato T, Sivak MV Jr. Endoscopic ultrasonography versus cholangiography for the diagnosis of choledocholithiasis. *Gastrointest Endosc* 1998; 47:439-448.
 19. Buscarini E, Tansini P, Rossi S, et al. Endoscopic ultrasonography for suspected choledocholithiasis: outcome analysis in 150 patients. *Digestion* 1998; 59:199.
 20. Cooperberg PL, Burhenne HJ. Real time ultrasonography: diagnostic technique of choice in calculus gallbladder disease. *N Engl J Med* 1980; 302:1277-1279.
 21. Chak A, Hawes R, Cooper G, et al. Prospective assessment of the utility of EUS in the evaluation of gallstone pancreatitis. *Gastrointest Endosc* 1999; 49:599-604.
 22. Dahan P, Andant C, Levy P, et al. Prospective evaluation of endoscopic ultrasonography and microscopic examination of duodenal bile in the diagnosis of cholecystolithiasis in 45 patients with normal conventional ultrasonography. *Gut* 1996; 38:277-281.
 23. Liu CL, Lo CM, Chan JKF, Poon RTP, Fan ST. EUS for detection of occult cholelithiasis in patients with idiopathic pancreatitis. *Gastrointest Endosc* 2000; 51:28-32.
 24. Liu CL, Lo CM, Chan JK, et al. Detection of choledocholithiasis by EUS in acute pancreatitis: a prospective evaluation in 100 consecutive patients. *Gastrointest Endosc* 2001; 54:325-330.
 25. Neitlich JD, Topazian M, Smith RC, Gupta A, Burrell MI, Rosenfield AT. Detection of choledocholithiasis: comparison of unenhanced helical CT and endoscopic retrograde cholangiopancreatography. *Radiology* 1997; 203:753-757.
 26. Polkowski M, Palucki J, Regula J, Tilszer A, Butruk E. Helical computed tomographic cholangiography versus endosonography for suspected bile duct stones: a prospective blinded study in non-jaundiced patients. *Gut* 1999; 45:744-749.
 27. Lee SP, Nicholls JF, Park HZ. Biliary sludge as a cause of acute pancreatitis. *N Engl J Med* 1992; 326:589-593.
 28. Ros E, Navarro S, Bru C, Garcia-Puges A, Valderrama R. Occult microlithiasis in "idiopathic" acute pancreatitis: prevention of relapses by cholecystectomy or ursodeoxycholic acid therapy. *Gastroenterology* 1991; 101:1701-1709.
 29. Dill JE, Hill S, Callis J, et al. Combined endoscopic ultrasound and stimulated biliary drainage in cholecystitis and microlithiasis diagnoses and outcome. *Endoscopy* 1995; 27:424-427.
 30. Freeman ML, Nelson DB, Sherman S, et al. Complications of endoscopic biliary sphincterotomy. *N Engl J Med* 1996; 335:909-918.
 31. Huibregtse K. Complications of endoscopic sphincterotomy and their prevention. *N Engl J Med* 1996; 335:961-963.
 32. Tham TCK, Lichtenstein DR, Vandevoort J, et al. Role of endoscopic retrograde cholangiopancreatography for suspected choledocholithiasis in patients undergoing laparoscopic cholecystectomy. *Gastrointest Endosc* 1998; 47:50-56.
 33. Buscarini E, Buscarini L. The role of endosonography in the diagnosis of choledocholithiasis. *Eur J Ultrasound* 1999; 10:117-126.
 34. Aubertin JM, Levoir D, Bouillot JL, et al. Endoscopic ultrasonography immediately prior to laparoscopic cholecystectomy: a prospective evaluation. *Endoscopy* 1996; 28:667-673.
 35. Burtin P, Palazzo L, Canard JM, Person B, Auberti F, Boyer J. Diagnostic strategies for extra-hepatic cholestases of indefinite origin: endoscopic ultrasonography or endoscopic retrograde cholangiography? Results of a prospective study. *Endoscopy* 1997; 29:349-355.
 36. Napoleon B, Dumortier J, Keriven-Souquet O, Pujol B, Ponchon T, Souquet JC. Do normal findings at biliary endoscopic ultrasonography obviate the need for endoscopic retrograde cholangiography in patients with suspicion of common bile duct stone? A prospective follow-up study of 238 patients. *Endoscopy* 2003; 35:411-415.
 37. Cotton PB. Endoscopic retrograde cholangiopancreatography and laparoscopic cholecystectomy. *Am J Surg* 1993; 165:474-478.
 38. Lambert R. Clinical outcome of EUS in biliary diseases. *Endoscopy* 2000; 32:558-561.
 39. Guibaud L, Bret PM, Reinhold C, Atri M, Barkun AN. Bile duct obstruction and choledocholithiasis: diagnosis with MR cholangiopancreatography. *Radiology* 1995; 197:109-115.
 40. Holzkecht N, Gauger J, Sackmann M, et al. Breath-hold MR cholangiography with snapshot techniques: prospective comparison with endoscopic retrograde cholangiography. *Radiology* 1998; 206:657-664.
 41. Materne R, van Beers BE, Gigot JF, et al. Extrahepatic biliary obstruction: magnetic resonance imaging compared with endoscopic ultrasonography. *Endoscopy* 2000; 32:3-9.
 42. Taylor A, Little A, Hennessy O, Banting S, Smith P, Desmond P. Prospective assessment of magnetic resonance cholangiopancreatography for noninvasive imaging of the biliary tree. *Gastrointest Endosc* 2002; 55:17-22.
 43. deLedinghen V, Lecesne R, Raymond JM, et al. Diagno-

- sis of choledocholithiasis: EUS or magnetic resonance cholangiography? A prospective controlled study. *Gastrointest Endosc* 1999; 49:26-31.
44. Kay CL. Which test to replace diagnostic ERCP- MRCP or EUS? *Endoscopy* 2003; 35:426-428
 45. Ohtani T, Kawai C, Shirai Y, Kawakami K, Yoshida K, Hatakeyama K. Intraoperative ultrasonography versus cholangiography during laparoscopic cholecystectomy: a prospective comparative study. *J Am Coll Surg* 1997; 185:274-282.
 46. Nies C, Bauknecht F, Groth C, et al. Intraoperative cholangiography as a routine procedure? A prospective, controlled, randomized study. *Chirurg* 1997; 68:892-897.
 47. Birth M, Ehlers KU, Delinikolas K, Weiser HF. Prospective randomized comparison of laparoscopic ultrasonography using a flexible ultrasound probe and intraoperative dynamic cholangiography during laparoscopic cholecystectomy. *Surg Endosc* 1998; 12:30-36.
 48. Sahai A, Mauldin P, Marsi V, Hawes R, Hoffman B. Bile duct stones and laparoscopic cholecystectomy: a decision analysis to assess the roles of intraoperative cholangiography, EUS, and ERCP. *Gastrointest Endosc* 1999; 49:334-343.
 49. Millat B, Deleuse A, Atger J, et al. Traitement de la lithiase de la voie biliaire principale sous laparoscopie. Evaluation prospective multicentrique chez 189 malades [French]. *Gastroenterol Clin Biol* 1996; 20:339-345.
 50. Berci G, Morgenstern L. Laparoscopic management of common bile duct stones: a multi-institutional SAGES study. *Surg Endosc* 1994; 8:1168-1174.
 51. Lorimer JW, Fairfull-Smith RJ. Intraoperative cholangiography is not essential to avoid bile duct injuries during laparoscopic cholecystectomy. *Am J Surg* 1995; 169:344-347.
 52. Schoefer M, Rathgeber A, Lang J, Nagell W, Dancygier H. Prognostic value of endoscopic ultrasound in acute pancreatitis [abstract]. *Gastroenterology* 1998; 114:A495.