

*Letter to the Editor***Severe salmonella enterocolitis complicated by colonic stenosis**

G.N. Katsoras, A.G. Grammatopoulos, A.P. Afroudakis

TO THE EDITOR:

Salmonella enterocolitis is an acute infectious disease of the intestine, characterized, clinically, by a diarrheal syndrome with or without fever, of ten to fifteen days duration. Bloody diarrhea has been recorded for about fifty percent of the patients.

Endoscopic abnormalities of the colonic and/or the small intestinal mucosa, ranging from superficial oedema and mucosal friability, to superficial or deep discrete ulcerations are, usually, present.¹

However, severe and extensive mucosal ulcerations with secondary stenotic lesions of the colonic lumen, due to salmonellosis, spreading to all parts of the colon and

to certain areas of the small intestine are, actually, rare.

We report a case of salmonella enterocolitis, characterized by extensive and severe irregular ulcerations (fig. 1), covering parts of the whole large intestine up to the terminal ileum (fig. 2).

A colonic stenosis was identified, during colonoscopy, at the sigmoid area (fig. 3).

Endoscopy of the small intestine revealed mucosal oedema and erythema at the lower parts of the jejunum.

A 55 year-old woman was admitted to our service with a clinical history of fever up to 38° C and severe non-bloody diarrhea (over ten bowel movements a day) preceded by crampy periumbilical pain. Her past medical history was unremarkable and the present clinical symptoms appeared eight days before her hospitalization.

Blood and stool cultures and a gastrointestinal pan-endoscopy were the key diagnostic procedures.

Blood cultures were negative for bacteria, but in stool cultures salmonella species were identified.² Serodiag-

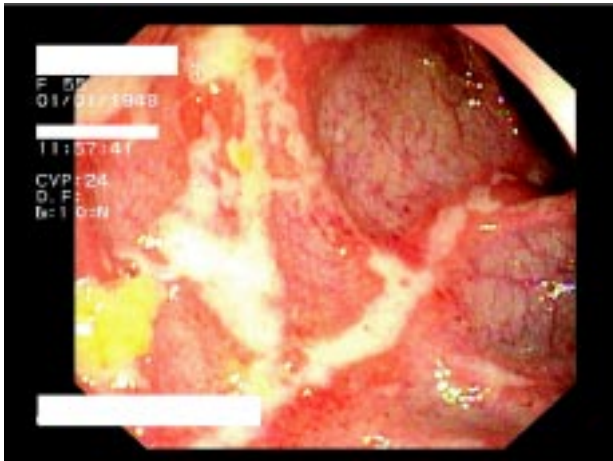


Fig. 1. Ulcerating lesions at sigmoid area of the colon

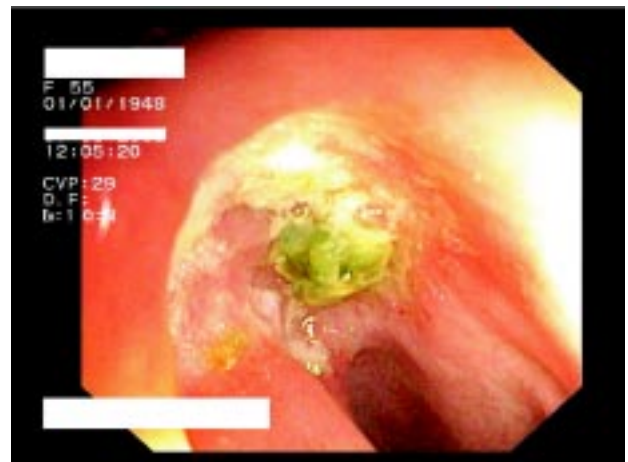


Fig. 2. Terminal ileum with discrete ulcerating changes.

*Dept. of Internal Medicine, Division of Gastroenterology
Metropolitan Hospital,*

Author for correspondence:

Ethn. Makariou 9 & El. Venizelou 1, 18547 Athens, Greece
Tel.: 210 48 09 122, Fax: 210 48 09391
e-mail: perseas@internet.gr

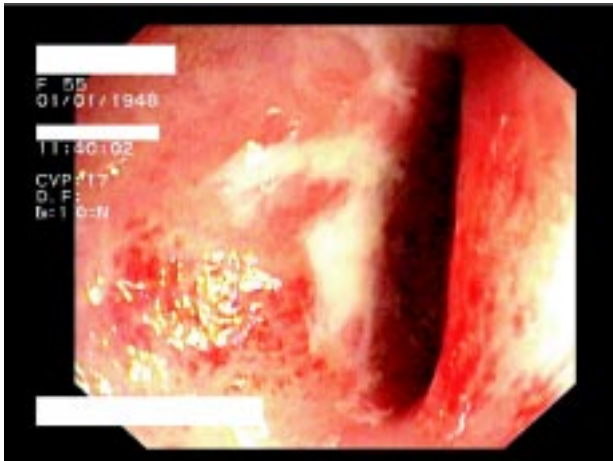


Fig. 3. Colonic stenosis at sigmoid colon

nostic procedures revealed salmonella paratyphus.

At colonoscopy and enteroscopy using the M2A endoscopic capsule (Given Imaging) extensive mucosal lesions were found, as described above, leaving normal mucosa between ulcerations.

Histologic examination revealed non-specific inflammatory changes of various severity. Tissue cultures were negative for salmonella.

A repeated endoscopy four weeks later and after a

fourteen-day course of ciprofloxacin confirmed a significant healing process of most of the ulcerating lesions. Although antibiotic administration is not a common practice for salmonella colitis,³ yet in cases with severe mucosal lesions, treatment with antibiotics and follow-up of the patients with repeated endoscopy, seem to be justified.⁴

It must be, also, emphasized that the absence of bloody stools, during the clinical course of the infectious colitis, does not exclude a severe colonic and/or small intestine involvement.⁵

REFERENCES

1. Goldsweig CD, Pacheco PA. Infectious colitis excluding *E. coli* 0157: H7 and *C. difficile*. *Gastroenterol Clin of North Am.* 2001; 30: 709-733.
2. Matsumoto T, Lida M, Kimura Y, et al: Culture of colonoscopically obtained biopsy specimens in acute infectious colitis. *Gastrointest Endosc* 1994; 40: 184.
3. Neill MA, Opal SM, Heelan J et al: Failure of ciprofloxacin to eradicate convalescent fecal excretion after acute salmonellosis. Experience during an outbreak in health care workers. *Ann Intern Med.* 1991; 114: 195.
4. Wolf DC, Giannella, R.A. Antibiotic therapy for bacterial enterocolitis: A comprehensive review. *Am J Gastroenterol* 1993; 88: 1667.
5. Kang JY. Endoscopic diagnosis of ileal ulceration in typhoid fever. *Gastrointest Endosc* 1988; 34: 442.