

*Case report*

## Crohn's disease and alopecia areata universalis; case report and review of the literature

K.H. Katsanos, D.K. Christodoulou, Christina Stergiopoulou<sup>1</sup>, Margarita Kitsanou, Anna Batistatou<sup>2</sup>, Th. Vergos, G. Economou, E.V. Tsianos<sup>3</sup>

### SUMMARY

**Alopecia areata (AA) is a non-scarring alopecia in which the characteristic initial lesion is a circumscribed totally bald, smooth patch. The term alopecia universalis is applied to total or almost total loss of all body hair. A 48-year old man presented with a two-month history of diarrhea and a two-week history of low-grade fever. Patient was diagnosed twelve years ago with AA universalis treated with pulse use of systemic steroids. Physical examination revealed circumscribed totally bald, smooth patches in eyebrows, eyelashes, upper and lower extremities. Diffuse hair loss was apparent over the whole of the scalp without the development of bald areas. Total colonoscopy with ileoscopy showed Crohn's disease, which was confirmed by multiple bowel biopsies. The patient was administered prednisolone systemically at a dose of 50 mg with satisfactory results. Although rare cases of AA correlation with other dermatoses and ulcerative colitis have already been reported, alopecia areata has not been reported so far in co-existence with Crohn's disease.**

**Key words:** alopecia areata, alopecia, Crohn, ulcerative colitis, inflammatory bowel disease

### INTRODUCTION

Dermatological lesions in patients with inflammatory

*Division of Internal Medicine & Hepato-Gastroenterology Unit, <sup>1</sup>Division of Dermatology, and <sup>2</sup>Department of Pathology, Medical School, University of Ioannina, Greece, <sup>3</sup>Professor of Internal Medicine*

*Author for correspondence:*

Dr Epameinondas V. Tsianos, Professor of Internal Medicine, Division of Internal Medicine, Medical School of Ioannina, 451 10 Ioannina, Greece, Fax: +30-26510-97016, Tel: +30-26510-97501, e-mail: etsianos@cc.uoi.gr

bowel disease (IBD) can be categorized as specific lesions (perianal fissures, metastatic Crohn's disease), as reactive lesions (erythema nodosum, pyoderma gangrenosum, hidradenitis suppurativa) and finally, as cutaneous manifestations (dermatoses) which are connected, with high probability, to IBD such epidermolysis bullosa acquisita and acne fulminans.<sup>1-4</sup> Alopecia areata (AA) is a non-scarring alopecia that accounts for about 2% of new dermatological outpatient attendances in the United States and Britain. Alopecia areata (AA) has not so far been reported in co-existence with Crohn's disease, although rare cases of AA correlation with other dermatoses and ulcerative colitis have already been reported.

It is not possible to attribute all or indeed any case of AA to a single cause to date. Among the many factors, which appear to be implicated in at least some cases, are the patient's genetic constitution, the atopic state, non-specific immune and organ-specific autoimmune reactions and possibly emotional stress<sup>5-10</sup>. There is widespread agreement with the hypothesis that AA is an autoimmune disease despite the fact that the evidence is at best circumstantial.

We report a patient with a twelve-year history of AA universalis who was diagnosed with Crohn's disease.

### CASE REPORT

A 48-year old man presented with a two-month history of diarrhea and a two-week history of low-grade fever. Patient was diagnosed twelve years ago with alopecia areata (AA) universalis treated quite effectively with pulse use of systemic steroids. Furthermore, the patient was on calcium channel blockers and non-steroid anti-inflammatory drugs following a coronary artery bypass, which was performed one year ago.

A detailed medical history, including recent use of steroids, and other skin treatments was obtained. Last pulse use of steroids was six months before admission and the patient was not receiving any therapy for AA at this period of time. The patient had no history of atopic state and no family history of possibly inherited diseases.

Physical examination revealed circumscribed totally bald, smooth patches in eyebrows, eyelashes, moustache, beard, upper and lower extremities (Figure). Diffuse hair loss was apparent over the whole of the scalp without the development of bald areas. Remaining hair had lost its normal caliber and color and was very readily extracted. In addition the patient had signs of androgenic type I alopecia in the temporal area of the scalp which, according to the patient, started twenty-five years ago. No neurological, eye or nail involvement was evident.

Skin punch biopsies (2mm) showed a dense, peribulbar and intrafollicular lymphocytic infiltrate and pulse test from alopecia patches was negative meaning that alopecia areata had already turned to chronicity.

The results of laboratory investigation included routine hematological, biochemical and immunological tests, and were all within normal limits including vitamin B12, neoplastic serum markers, hepatoviruses antigens and antibodies, RPR test, HIV antibodies, thyroid function tests and dexamethasone test. Fecal examination and cultures were negative for any kind of bacteria or parasites.

Upper gastrointestinal endoscopy and abdominal ultrasound did not show anything remarkable. Total colonoscopy with ileoscopy showed a patchy pattern of inflamed mucosa with diffuse aphthous ulcers in the terminal ileum and the descending colon. The endoscopic

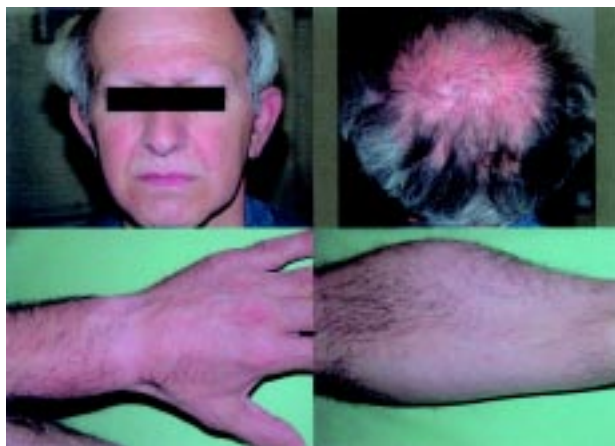


fig. Alopecia areata universalis in Crohn's disease.

appearance of Crohn's disease was confirmed by multiple bowel biopsies taken from all parts of the examined bowel. There was no evidence of dysplasia or bowel epithelial cell atypia in all biopsies.

The patient received prednisolone systemically at a dose of 50 mg with satisfactory results after two weeks of treatment. In fact hair, eyebrow and eyelashes regained growth and pigmentation while bowel disease showed remarkable remission. The patient is currently on close follow up for his alopecia areata and Crohn's disease.

## DISCUSSION

The characteristic initial lesion of AA is commonly a circumscribed totally bald, smooth patch; it is often noticed by chance by a parent, hairdresser or friend. Subsequent progress is very varied; the initial patch may regrow within a few months, or further patches may appear after an interval of 3-6 weeks and then in a circular fashion. The scalp is the first affected in over 60% of cases. In dark-haired men patches in the beard are conspicuous and in such individuals are often the first to be noticed. The eyebrows and eyelashes are lost in many cases of AA and may be the only sites affected. The term alopecia totalis is applied to total or almost total loss of scalp hair and alopecia universalis is the loss of all body hair. The extension of alopecia along the scalp margin is known as ophiasis. Finally, AA strictly confined to one-half of the body has been reported after a head injury.<sup>5,6</sup> The single consistent histological feature in AA is the presence of a dense, peribulbar and intrafollicular lymphocytic infiltrate. The upper, permanent portion of the hair follicle may also be involved in the infiltrate either in anagen or telogen.<sup>7,8</sup>

It is not at present possible to attribute all or indeed any case of AA to a single cause. Among the many factors, which appear to be implicated in at least a proportion of cases, are the patient's genetic constitution, the atopic state, non-specific immune and organ-specific autoimmune reactions and possibly emotional stress.<sup>6,9,10</sup> There is widespread agreement with the hypothesis that AA is an autoimmune disease despite the fact that the evidence is at best circumstantial. Support has come from three main areas of research: association with autoimmune diseases, humoral immunity and cell-mediated immunity<sup>11</sup>. Thyroid disease is the most frequently described disease in association with AA but the published figures are contradictory<sup>12</sup>. The following disorders, all of a possible immunological nature, have also been reported in association with AA: pernicious anemia, systemic lupus erythematosus and rheumatoid arthritis,

polymyalgia rheumatica, myasthenia gravis, ulcerative colitis, lichen planus and the candida-endocrinopathy syndrome.<sup>5,13-17</sup> In no case of AA is a completely confident prognosis justifiable; of those patients developing AA before puberty 50% may become totally bald. In contrast, only 25% of those developing AA after puberty become totally bald and 5.3% recover completely.<sup>5,18</sup>

In fact, rare cases on the association of AA with vitiligo, scleroderma, myasthenia gravis, atypical lichen planus and ulcerative colitis have been reported.<sup>13-14,19</sup> An increased frequency of thyroid antibodies and gastric parietal cell antibodies has been reported in children and adults with AA.<sup>12</sup> Available clinical and laboratory investigations on our patient, as well as patient follow-up failed to prove any co-existing cutaneous or other extraintestinal manifestations except from androgenic alopecia diagnosed twenty five years ago. Genetic testing for IL-1r antagonist gene or measurement of IL-1r levels was not performed on this patient, because this testing was not available. As known, a genetic association with IL-1r antagonist gene has been described in AA.<sup>20</sup> So, in our patient, an underlying genetic association with AA could not be excluded, despite his negative family history.

Clinical changes associated to AA may involve nail dystrophy, Horner's syndrome, ectopia of the pupil, iris atrophy and tortuosity of the fundal vessels.<sup>21-22</sup> However, no neurological, eye or nail involvement was evident in this patient.

The incidence of a family history in AA ranges from 4% to 27%<sup>18</sup>. The mode of AA inheritance has been suggested to be autosomal with variable penetrance. Racial factors may also be important, however, HLA studies have shown conflicting results<sup>5</sup>. In addition, AA has an increased incidence in patients with Down's syndrome.<sup>23</sup>

Alopecia areata has rarely been associated with ulcerative colitis as familial aggregation and HLA association have been reported in both disorders. The occurrence of both AA and ulcerative colitis in a mother and her son has been reported.<sup>19</sup> In this case, cyclosporine proved beneficial to the child leading in inflammatory bowel disease remission and nascent growth of scalp and body hair.

In a large Italian study a significant, although indirect, association of AA with ulcerative colitis was found as both correlated with lichen planus history.<sup>24,25</sup> According to another study, a common characteristic that AA and ulcerative colitis probably share is the increased prevalence of juvenile rheumatoid arthritis in first and second-degree relatives.<sup>26</sup> Furthermore, in analogy with

the clinical severity in ulcerative colitis, a significant association between severity of AA and polymorphism in the interleukin-1 receptor antagonist gene has been reported<sup>20</sup>.

The only study correlating, although indirectly, family history of Crohn's disease with AA occurrence is a case control study where risk of type 1 diabetes was significantly associated among others with a positive family history of Crohn's disease and alopecia areata<sup>27</sup>.

As far as humoral immunity is concerned, studies of organ-specific antibodies in AA have given conflicting results, perhaps due to small groups of patients and controls and differing methodology. The possible role of immunoglobulins' polymorphisms in the pathophysiology of autoimmune diseases including AA and inflammatory bowel disease has been analyzed in several studies.<sup>28-30</sup>

In addition, circulating total T-cell numbers in AA have been reported as reduced, normal or increased. The strongest direct evidence for autoimmunity in AA comes from the consistent findings of a lymphocytic infiltrate in and around hair follicles and Langerhans cells, which have also been seen in the peribulbar region<sup>5</sup>. This histologic prototype of lymphocytic infiltrate is also common in many bowel biopsies taken from Crohn's disease patients.

As compared with inflammatory bowel disease, a wealth of case reports suggest that stress may be also an important precipitating factor in some cases of AA<sup>18</sup> despite the fact that this patient did not report any stressful event occurring at the time of Crohn's disease diagnosis or AA relapses.

Furthermore, in patients with longstanding AA the possibility of an underlying inflammatory bowel disease should never be neglected even in the absence of bowel symptoms. Many new or unusual cases may represent a separately identifiable entity as the biochemical abnormalities and the pathogenetic mechanisms involved have not been described in detail in these diseases.<sup>31-32</sup>

The process of AA can be reversed to a variable extent by several very different therapeutic measures: corticosteroids, local irritants, photochemotherapy, induction of contact dermatitis, or by cyclosporin<sup>33-35</sup>. Thus, cases with Crohn's disease and AA should be treated carefully and on a close follow up as there is no experience on immunosuppressive drug use in such a group of patients<sup>34</sup>. Systemic corticosteroids will restore normal hair growth in many cases of AA<sup>36</sup>. The hair shows abrupt repigmentation and thickening without discontinuity of the shaft.

Controversy remains, however, as to the justification for prescribing these potentially hazardous in long term use drugs, because most cases relapse at some stage during or after withdrawal of treatment<sup>35</sup>. Topical and intralesional steroids<sup>33</sup> have a small but useful role and topical cyclosporin seems to do slightly better than placebo. In this patient we decided to start with prednisolone in order to achieve bowel and AA remission. After several years we will be able to report the safety and efficacy of immunosuppressants in this patient<sup>37-38</sup>.

This case raises the question of whether Crohn's disease was secondary to AA or AA was the cutaneous manifestation of a silent Crohn's disease or whether each of these diseases developed independently as co-existence by chance cannot be excluded. However, as the only treatment used for AA all these years was pulse systemic corticosteroid administration we can not exclude the possible effect of corticosteroids maintaining a Crohn's disease in complete remission all these years.

To the best of our knowledge this is the first case of documented Crohn's disease occurring in a patient with alopecia areata universalis.

## REFERENCES

- Paller AS. Cutaneous changes associated with inflammatory bowel disease. *Pediatr Dermatol* 1986; 3: 439-445.
- Katsanos KH, Christodoulou DK, Tsianos EV. Axillary hidradenitis suppurativa successfully treated with infliximab in a Crohn's disease patient. *Am J Gastroenterol* 2002; 97: 2155-2156.
- Schorr-Lesnick B, Brandt LJ. Selected rheumatologic and dermatologic manifestations of inflammatory bowel disease. *Am J Gastroenterol* 1988; 83: 216-227.
- Christodoulou D, Katsanos KH, Kitsanou M, Stergiopoulou Cr, Hatzis I, Tsianos EV. Frequency of extraintestinal manifestations in patients with inflammatory bowel disease. *Dig Liver Dis* 2002; 34: 781-786.
- Dawber RPR, Ebling FJG, Wojnarowska FT. Disorders of hair. In: Rook/Wilkinson/Ebling. *Textbook of Dermatology*. Blackwell Scientific Publications (Eds), Oxford 1992: 2586-2594.
- Eckert J, Church RE, Ebling FJ. The pathogenesis of alopecia areata. *Br J Dermatol* 1968; 80: 203-211.
- Jackson D, Church RE, Ebling FJ. Alopecia areata hairs. A scanning electron microscopic study. *Br J Dermatol* 1971; 85: 242-246.
- Peereboom-Wynia JDR, Koerten HK, van Joost TH et al. Scanning electron microscopy comparing exclamation mark hairs in alopecia areata with normal hair fibers mechanically broken by traction. *Clin Exp Dermatol* 1989; 14: 47-56.
- Arnold HL. Alopecia areata; prevalence in Japanese and prognosis after reassurance. *AMA Arch Dermatol Syphilol* 1952; 66: 191-197.
- Young E, Bruns HM, Berrens L. Alopecia areata and atopy. *Dermatologica* 1978; 156: 308-316.
- Orecchia G, Belvedere MC, Martinetti M, et al. Human leucocyte antigen region involvement in the genetic predisposition to alopecia areata. *Dermatologica* 1987; 175: 10-15.
- Muller HK, Rook AJ, Kubba R. Immunohistology and autoantibody studies in alopecia areata. *Br J Dermatol* 1980; 102: 609-615.
- Tan RS. Ulcerative colitis, myasthenia gravis, atypical lichen planus, alopecia areata, vitiligo. *Proc R Soc Med* 1974; 67: 195-196.
- Thompson DM, Robinson TW, Lennard-Jones J. Alopecia areata, vitiligo, scleroderma and ulcerative colitis. *Proc R Soc Med* 1974; 67: 1010-1012.
- Friedman PS. Alopecia areata and autoimmunity. *Br J Dermatol* 1981; 105: 153-157.
- Friedman PS. Clinical and immunological associations of alopecia areata. *Sem Dermatol* 1985; 4: 9-24.
- Robinson SS, Tasker S. Alopecia areata associated with neurodermatitis. *Urol Cutan Rev* 1948; 52: 468-473.
- De-Waard-Van der Spek FB, Oranje AP, De Raeymaecker DM et al. Juvenile versus mature onset alopecia areata—a comparative retrospective clinical study. *Clin Exp Dermatol* 1989; 14: 429-436.
- Treem WR, Veligati LN, Rotter JI, Targan SR, Hyams JS. Ulcerative colitis and total alopecia in a mother and son. *Gastroenterology* 1993; 104: 1187-1191.
- Tarlow JK, Clay FE, Cork MJ, Blekemoore AI, McDonagh AJ, Messenger AG, et al. Severity of alopecia areata is associated with a polymorphism in the interleukin-1 receptor antagonist gene. *J Invest Dermatol* 1994; 103: 387-390.
- Brenner W, Diem E, Gschnait F. Coincidence of vitiligo, alopecia, onychodystrophy, localized scleroderma and lichen planus. *Dermatologica* 1979; 159: 356-360.
- Langhof H, Lenke L. Ophthalmologische befunde bei alopecia areata. *Dermatol Wochenschr* 1962; 146: 585-588.
- Du Vivier A, Munro DD. Alopecia areata, autoimmunity and Down syndrome. *Br Med J* 1975; 1: 191-194.
- [No authors listed]. Epidemiological evidence of the association between lichen planus and two immune-related diseases. Alopecia areata and ulcerative colitis. Gruppo Italiano Studi Epidemiologici in Dermatologia. *Arch Dermatol* 1991; 127: 688-691.
- [No authors listed]. Study of lichen planus conducted by the IGESD: results, implications for clinical practice, prospects. Italian Group of Epidemiological Studies in Dermatology (IGESD). *G Ital Dermatol Venereol* 1990; 125: 563-567.
- Prahalad S, Shear ES, Thompson SD, Giannini EH, Glass DM. Increased prevalence of familial autoimmunity in simple and multiplex families with juvenile rheumatoid arthritis. *Arthritis Rheum* 2002; 46: 1851-1856.
- Sipetic S, Vlajinac H, Kocev N, Marinkovic J, Radmanovic S, Denic L. Family history and risk of type 1 diabetes

- mellitus. *Acta Diabetol* 2002; 39: 111-115.
28. Dugoujon JM, Guitard E, Senegas MT. Gm and Km allotypes in autoimmune diseases. *G Ital Cardiol* 1992; 22: 85-95.
  29. Dugoujon JM, Cambon-Thomsen A. Immunoglobulin allotypes (GM and KM) and their interactions with HLA antigens in autoimmune disease; a review. *Autoimmunity* 1995; 22: 245-260.
  30. Sundberg JP, Cordy WR, King LE Jr. Alopecia areata in aging C3H/HeJ mice. *J Invest Dermatol* 1994; 102: 847-856.
  31. Tsianos EV, Massalas CN, Merkouropoulos M, Dalekos GN, Logan RFA. Incidence of inflammatory bowel disease in NW Greece: rarity of Crohn's disease in an area where ulcerative colitis is common. *Gut* 1994; 35: 369-372.
  32. Tsianos EV, Katsanos KH, Christodoulou D, Dimoliatis I, Logan RF. Continuing low incidence of Crohn's disease in Northwest Greece. *Dig Liv Dis* 2003; 35: 99-1030.
  33. Abell E, Munro DD. Intralesional treatment of alopecia areata with triamcinolone acetonide by jet injection. *Br J Dermatol* 1973; 88: 55-81.
  34. Gupta AK, Ellis CN, Cooper KD, et al. Oral cyclosporin for the treatment of alopecia areata. *J Am Acad Dermatol* 1990; 22: 242-248.
  35. Unger WP, Schemmer RJ. Corticosteroids in the treatment of alopecia totalis. *Arch Dermatol* 1978; 114: 1486-1492.
  36. Berger RA, Orentreich N. Abrupt changes in hair morphology following corticosteroid therapy in alopecia areata. *Arch Dermatol* 1960; 82: 408-412.
  37. Katsanos KH, Christodoulou DK, Zioga A, Tsianos EV. Cutaneous nevi pigmentosus during infliximab therapy in a patient with Crohn's disease: Fallacy or coincidence? *Inflamm Bowel Dis* 2003; 9: 279.
  38. Christodoulou D, Katsanos K, Baltayannis G, Tzambouras N, Tsianos EV. A report on efficacy and safety of azathioprine in a group of inflammatory bowel disease patients in Northwest Greece. *Hepatogastroenterology* 2003; 50: 1021-1024.