

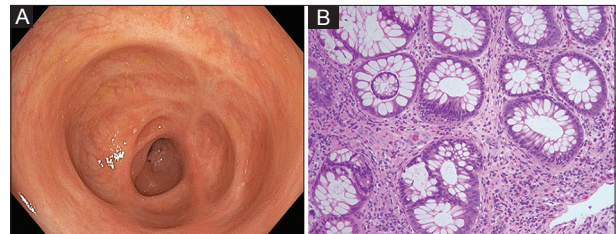
## Through-the-scope endoscopic balloon dilatation of a nonsteroidal anti-inflammatory drug-induced diaphragm-like colonic stricture

Mel A. Ona<sup>a</sup>, Rashmee Patil<sup>b</sup>, Denzil Etienne<sup>a</sup>, Sindhura Kolli<sup>a</sup>, Madhavi Reddy<sup>a</sup>

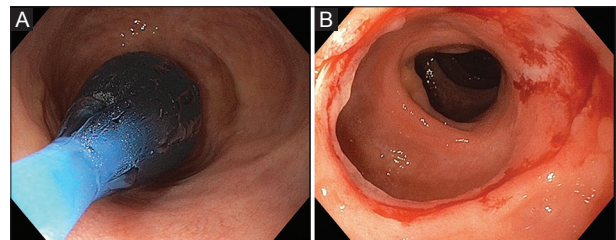
The Brooklyn Hospital Center, Academic Affiliate of The Icahn School of Medicine at Mount Sinai, Clinical Affiliate of The Mount Sinai Hospital; Mount Sinai West, New York, USA

A 56-year-old woman with a history of sciatica, who had been taking nonsteroidal anti-inflammatory drugs (NSAIDs) for one year complained of abdominal fullness, rectal bleeding, and decreased stool caliber for the past six months. An endoscope could not be extended beyond a stenosed region within the descending colon. This narrowed area appeared suggestive of a diaphragm-like stricture and was surrounded by areas of healed colitis and fibrosis (Fig. 1). Biopsies revealed lamina propria fibrosis with eosinophilic infiltration (Fig. 1). A through-the-scope sequential balloon dilator (Fig. 2) was used to dilate the stricture (Fig. 2) and an endoscope was subsequently advanced into the cecum, which revealed no further colopathy. The patient tolerated the procedure well; she was advised to avoid NSAIDs, and upon follow up she reported resolution of her symptoms.

Colonic diaphragm-like stricture disease was first reported in 1989. An estimated 50 cases have been described in the last 10 years. Most cases were linked to long-term use of NSAIDs [1,2]. The pathophysiology of NSAID-induced colonic strictures is still not clear, but some studies attribute fibrosis to local toxic effects of NSAID preparations on mucosal integrity due to inhibition of protective prostaglandins [3]. Colonic diaphragm-like strictures should be considered in the



**Figure 1** (A) Colonoscopy revealing nonsteroidal anti-inflammatory drug-induced diaphragm-like colonic stricture; and (B) biopsy showing lamina propria fibrosis with eosinophilic infiltration



**Figure 2** (A) Through-the-scope (TTS) balloon dilatation of diaphragm-like stricture; and (B) post-TTS balloon dilatation of diaphragm-like stricture

Departments of <sup>a</sup>Gastroenterology and Hepatology, The Brooklyn Hospital Center, Academic Affiliate of The Icahn School of Medicine at Mount Sinai, Clinical Affiliate of The Mount Sinai Hospital, Brooklyn, NY (Mel A. Ona, Denzil Etienne, Sindhura Kolli, Madhavi Reddy); <sup>b</sup>Internal Medicine, Mount Sinai West, New York (Rashmee Patil), USA

Dr. Ona and Dr. Patil contributed equally to this manuscript as co-first authors.

Conflict of interest: None

Correspondence to: Mel A. Ona, MD, MS, MPH, MA, 121 Dekalb Avenue, Brooklyn, NY 11201, USA, Tel.: +1 718 250 6976, Fax: +1 718 250 6825, e-mail: melaona@yahoo.com

Received 21 January 2016; accepted 26 January 2016

DOI: <http://dx.doi.org/10.20524/aog.2016.0020>

differential diagnosis of patients presenting with malignancy-associated symptoms, who have a history of long-term NSAID use.

### References

1. Zagnoon A. Letter to the editor: Re: Eis et al. NSAID-induced benign stricture of the colon. *Am J Gastroenterol* 1998;**93**:1388.
2. Muniapalle P, Garud T, Light D. Diaphragmatic disease of the colon: systematic review. *Colorectal Dis* 2013;**15**:1063-1069.
3. Gopal D, Katon R. Endoscopic balloon dilation of multiple NSAID-induced colonic strictures: case report and a review of literature on NSAID-related colopathy. *Gastrointest Endosc* 1999;**50**:120-123.