

Case report

## Rare benign tumours of the small intestine presented as acute abdomen in childhood

B. Kasselas, M. Papoutsakis, Ch.Chaidos, Ch. Kasselas, G. Tsikopoulos, M. Agelidou, G.Papouis, Th. Karagiozoglou

### SUMMARY

Benign tumours of the small intestine in children although rare, may represent an additional cause of acute abdomen symptoms that the gastroenterologist, the paediatrician and the surgeon must keep in mind in order to proceed to accurate diagnosis and appropriate treatment. Three cases of benign tumours of the small intestine, histologically diagnosed as leiomyoma, fibroma and hamartoma., are presented, and the literature is revised emphasizing issues of pathophysiology, specific characteristics and the treatment of these tumours.

**Key words:** Benign tumours, small intestine, acute abdomen, children.

### INTRODUCTION

Neoplasms of the small intestine represent a percentage of 3% to 6% of the tumours of the gastrointestinal tract and less than 2% of all tumours.<sup>1,2</sup> Benign tumours of the small intestine are estimated to be 10% of all non-malignant tumours of the gastrointestinal tract and 30% of all the neoplasms of the small intestine.<sup>3,4,5</sup> Among benign neoplasms of the small intestine leiomyoma, adenoma, lipoma, haemangioma, fibroma and hamartoma are included with regard of their incidence.<sup>2,6,7,8</sup> These neoplasms are usually seen after the fifth decade of life with a peak incidence between 70 to 80 years of age.<sup>7</sup>

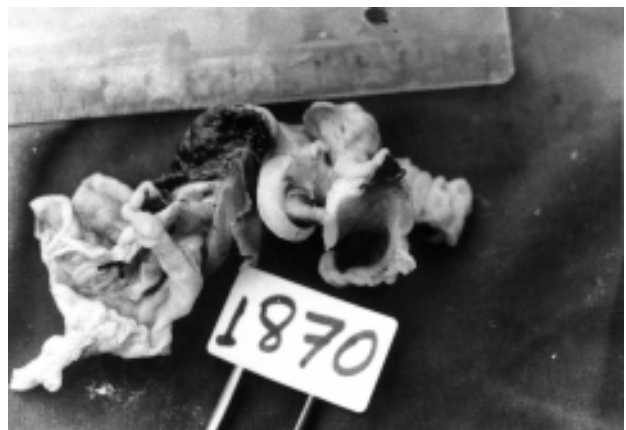*Pediatric Surgery Dept, Hippokraton " Hospital, Thessaloniki, Greece*

*Author for correspondence:*

Th. Karagiozoglou, Ethnikis Amynis 14, 546 21 Thessaloniki, Tel.: +2310.265.724, e-mail: thomaiskl@hotmail.com

### CASE NR1

A 4 year old boy presented complaining of abdominal pain, bilious vomiting, and fever up to 38,5 degrees. The symptoms of the disease started two days before presentation and no previous history was reported. The diagnosis of acute abdomen was established by clinical findings, physical examination, diagnostic tests, radiography and laboratory investigations (leucocytosis with neutophilia, radiological signs of ileus of the small bowel). During laparotomy a tumour of the small bowel was revealed at the mesenteric margin of the small intestine (approximately in the middle of the bowel). It was of a hard consistency with a diameter of 1.2cm, limited by the surrounding tissues; its colour was dark red and it provoked a large subserosal haematoma measuring 5 cm on both sides (Fig.1). Because of all these characteristics, the tumour was considered benign. The exploration of the rest of the abdomen indicated no other

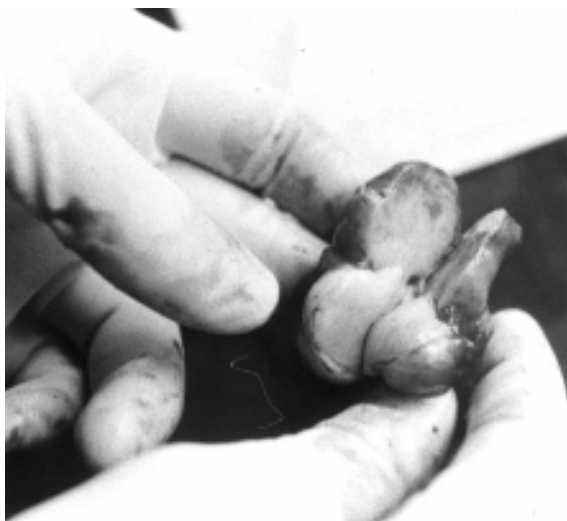

**Figure 1.** Macroscopic appearance of the leiomyoma

pathological signs and an intestinal resection of 5cm on both sides of the tumour (with excision of the mesentery) with an end to end anastomosis was performed. The postoperative course of the young patient was without complications. A leiomyoma of the small bowel with no histological evidence of malignant characteristics was diagnosed (Fig 3) which was completely excised and had no regional lymph node metastasis. To date, 7 years after the operation, the patient has had no other problems.

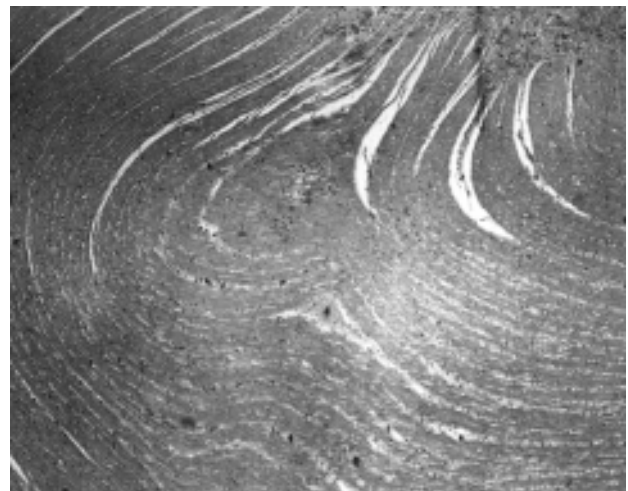
## CASE NR2

An 11 year old girl was hospitalized in the pidiatric dept. for anemia investigation. The disease manifested with diffuse, recurrent, non-typical abdominal pain, anorexia, vomiting, constipation and weight loss (7kg.) over the previous six months. Profound anemia was evidenced through physical examination and diagnostic tests (Hb 6 gr. Ht 19%). Further laboratory investigations were normal except for a positive Mayer stool test. Screening tests and radiological investigation provide no information, as did the scintigram (Tc-99) which was normal. On the other hand, the ultrasound examination revealed a small fluid collection in Douglas space. The anemia was treated with blood transfusion and a CT study of the abdomen was scheduled. During the investigation, the patient showed signs of high obstructive ileus so she was subjected to an emergency operation. Exploratory laparotomy revealed the existence of a jejuno-jejunal intussusception. After manual reduction, a tumour was palpated (as the lead-point causing intussusception)

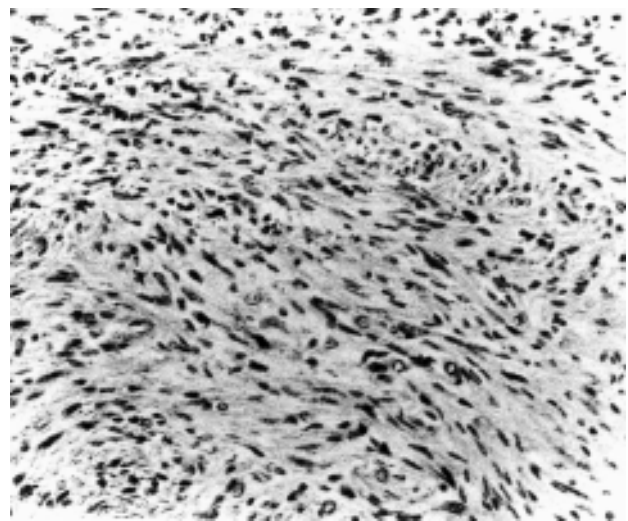


**Figure 3.** Microscopic appearance of the leiomyoma

whitish in color, of hard consistency, with a diameter of 1,5cm and which was localized at the antimesenteric margin of the bowel and occupying almost the whole intestinal lumen (Fig 2). Segmental resection of the small intestine with tumour free margins was performed as well as an end-to-end anastomosis. Surgical exploration of the abdominal cavity failed to reveal any additional findings. The postoperative course of the patient was uncomplicated. Histology diagnosed an intestinal fibroma with no malignant evidence (Fig 4), whereas the margins of resection and the regional lymph nodes were not infiltrated. To date, three years later, the patient, who is examined periodically, has had no other health problems.



**Figure 2.** Macroscopic appearance of the fibroma



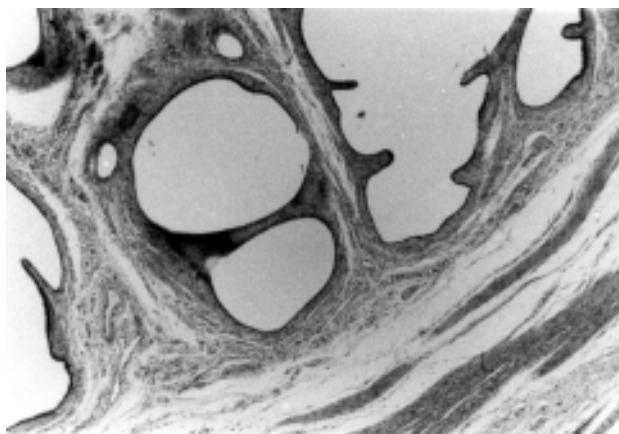
**Figure 4.** Microscopic appearance of the fibroma

### CASE NR3

This case refers to a 6 month-old boy, who presented with abdominal pain, vomiting plus blood-stained mucus in the stools for the previous 12 hours. From the history and physical examination, plain X-rays of the abdomen (that showed signs of obstruction) and ultrasound examination, possible ileocolic intussusception was considered, which was confirmed during laparotomy. Manual reduction followed and an intraluminal mass the size of a “nut” (5 cm from the ileocecal valve) was palpated (it was the lead-point of intussusception). Its consistency was rough and was limited by the surrounding tissues. A wedge resection of the lesion was performed, followed by an end-to-end ileo-ileal anastomosis. There were no additional findings during surgical examination of the abdomen. Gross pathological examination of the lesion revealed a dark red polypoid projection of the mucosa. Microscopic histological examination showed that it was a myoepti-thelial hamartoma of the small intestine with no malignant features, whereas the overlying mucosa showed signs of ischaemic necrosis (Fig 5). The patient’s postoperative course was satisfactory. Today, the patient remains completely healthy.

### DISCUSSION

Among all benign neoplasms of the small intestine, leiomyoma represents a percentage of 30-35%, hamartomas 10-12% and fibromas 6%.<sup>6</sup> Their incidence increases from the duodenum to ileum. Approximately half of them are usually asymptomatic and are verified at autopsy.<sup>6,7</sup> The main presenting symptoms are abdominal pain, intestinal obstruction with or without intussusception, gastrointe-



**Figure 5.** Microscopic appearance of the hamartoma

stinal bleeding and palpable abdominal mass.<sup>7,9,10-12</sup> Perforation and peritonitis are extremely rare complications in children, even though they have been referred in adults.<sup>7,9,10,12</sup> The most common complication, which occurs in children, is secondary intussusception.<sup>7,8,12-14</sup> Preoperative diagnosis includes specific difficulties and is accurate in only 5% of cases, even if complete diagnostic investigation is performed in those cases where the patient’s condition permits it.<sup>7,15-17</sup> A better management of the preoperative diagnosis should be facilitated by the use of new types of endoscopic instruments allowing us to investigate the whole small intestine.<sup>16,18</sup> Nevertheless, such endoscopic instruments are not widely used at the present moment. The majority of these patients are admitted to hospital with the clinical presentation of acute abdomen or acute abdomen is manifested later, during imaging studies for other symptoms, before diagnosis is considered.<sup>5,7,13,19-21</sup> The pediatric surgeon, confronted with such an unusual case, is asked to give an accurate and immediate answer to the following problems: Is it really a leiomyoma, a fibroma, hamartoma or another type of intestinal neoplasm? Knowledge of macroscopic features and other specific details are helpful to the pediatric surgeon, but a precise diagnosis is almost impossible since the tumours are presented with so many similarities and few differences. Actually, fibromas, hamartomas and leiomyomas reveal as rough lesions, with a round shape or a multilobular configuration, measuring from some mm to some cm in diameter, clearly limited by the surrounding tissues with no capsule.<sup>7,9,22</sup> Fibroma presents with a whitish colour while leiomyoma and hamartoma with a dark reddish one.<sup>8,9,21,23,24</sup> Calcifications are identified at 3% of leiomyomas.<sup>22</sup>

Is the tumour a benign one or not? The evaluation of malignancy or non-malignancy is almost impossible.<sup>6,10,11,21-23</sup> This is due to, on the one hand, the common clinical presentation and specific characteristics and on the other hand leiomyomas, fibromas and hamartomas are considered as potentially malignant tumours and are associated with a significant risk of malignant differentiation.<sup>7,10,23,25</sup>

However there are some macroscopic characteristics of these tumours that are estimated as indicative of malignancy. These characteristics are: large dimensions of the tumour, adhesions with the abdominal wall or other intestinal loops, expansion via surrounding tissues, paradoxical vascularisation and metastases.<sup>7,10,21,23</sup> General and multiple fibromatosis is evidence of malignancy for fibromas and this demands systematic and long-term care.<sup>23,26</sup> Histological examination should lead to the

precise diagnosis, even though the distinction between a benign leiomyoma and a differentiated one or a leiomyoblastoma, a benign fibroma, a benign myoepithelial hamartoma and a differentiated one may not be always be obvious.<sup>23,25,27</sup> Histological indicators for the determination of tumour malignancy are increased mitotic activity (mitoses more than 10 X 10 HPF), cellular pleomorphism, the degree of cellular differentiation and hypercellularity.<sup>23,27</sup>

The third question concerns the patient's management for complete cure. From the previously mentioned evidence, in accordance with the relevant references, it is clear that the tumour must be excised radically by a segmental intestinal resection and excision of the corresponding mesentery, even if there is no macroscopic evidence of malignancy.<sup>5,7,10</sup> In these cases, prognosis is excellent. Moreover, if the microscopic examination confirms the complete excision of the tumour, in addition to the absence of any malignant features, no further treatment is required.

A serious problem is presented when the tumour displays macroscopic features of malignancy, or when there is histological documentation that the margins of resection are not free of tumour cells, as well as the identification of hypercellularity or nontypical mitotic activity.<sup>5,7,23</sup>

These cases demand more radical operations or other management, and a thorough follow-up of the patient since they carry a high percentage of regional recurrence and a poor prognosis.<sup>7,9,23,26,28</sup>

## REFERENCES

- Norberg K, Emas S. Primary tumours of small intestine. *Am J Surg* 1981; 142:569-573.
- Iurica VJ, Ross El. Recurrent gastrointestinal bleeding of obscure origin. *Ill Med* 1987; 172 (5):367-369.
- Zhang WL. Primary tumour of the small intestine. Analysis 102 patients. *Chung Hua Chung Liu. Twsa Chih* 1988; 10:370-372.
- Giuliani A, Caporale A, Teneriellof, et al. Primary tumours of the small intestine. *Int Surg* 1985; 70: 331-334.
- Croeninger J, Georgi M. Tumours of the small intestine-clinical signs and symptoms, diagnosis and therapy. *Leber Magen Darm* 1977; 7: 75-83.
- Ashley SW, Wells Jr SA. Tumours of the small intestine. *Semin Oncol* 1988; 15: 116-128.
- Burgos AA, Martinez ME, Jaffe BE. Tumours of the small Intestine. In: Zinner MJ, Schwartz SI, Ellis H: *Maingot's abdominal operations*, Vol. I, Tenth ed. Appleton & Lange, Connecticut 1997; pp:1173-1184.
- Gonzalez J, Marco A, Andujar M, et al. Myoepithelial hamartoma of ileum: A rare cause of intussusception in children. *Eur J Surgery* 1995;5:303-304.
- Laursen E, Lyng MK. Leiomyomas of the small intestine: a rare case of abdominal emergency: case report. *Acta chir. Scand* 1987; 153:391-393.
- Freeman J. Leiomyoma of small bowel. A case report. *J. Ped. Surg.* 1979; 14: 477-478.
- Wilson JM, Melvin DB, Gray G, et al. Benign small bowel tumour. *Ann Surg* 1975; 181:247-250.
- Fiston HC. Other causes of intestinal obstruction. In: O'Neil JA, Rowe MI, Crosfeld JL, et al (eds): *Pédiatrie surgery*. Vol. II fifth ed. Mosby MO, St Louis, 1998; pp 1215-1222. IS. Yamagami T, Tokiwa K, Iwai N. Myoepithelial hamartoma of the ileum causing intussusception in an infant. *Ped. Surg. Int.* 1997;12:206-207.
- Kleiner O, Mordehai J, Maor E, et al. Myoepithelial hamartoma of jejunum: A rare cause of intussusception in children. *Surg Child Intern* 1997;2:122-123.
- Freud H, Lavi A, Pfeffermann R, et al. Primary neoplasm of the small bowel. *Am. J. Surg* 1978; 135: 757-759.
- Foutch PG, Sanowski RA, Kelly S. Enteroscopy: A method for detection of small bowel tumours. *Am. J. Gastroenterol.* 1985; 80: 887-890.
- Goutsoyanis NS, Bays P, Papaioanou N, et al. Benign tumours of the small intestine: preoperative evaluation with barium infusion technique. *Eur. J. Radiol.* 1995;16: 115-125.
- Nakamura S, Lida M, Nakao Y, et al. Diagnostic value of push-type jejunal endoscopy in primary jejunal carcinoma. *Surg. Endosc* 1993; 7: 188-190.
- Walters AN, Thomson RK. Leiomyoma causing massive gastrointestinal blood loss. A case report. *Australas. Radiol* 1988;32:138-140.
- Gonzales-Gussi F, Norouha R. Solitary intestinal fibromatosis in the newborn. Rare cause of neonatal intestinal obstruction. *Arch. Pathol LabMed* 1985; 109:97-99.
- Dawson J. Hamartomas in the alimentary tract. *Gut* 1969; 10: 691-694.
- Kaupp HA, Carol WW, Steids TW. Leiomyomas of the gastrointestinal tract. *Arch. Surg* 1964; 88: 892-896.
- Humar A, Chous Carpenter B. Fibromatosis in infancy and childhood. The spectrum *J. Ped. Surg.* 1993; 28:1446-1450.
- Stigley JR, Mauer K. Solitary intestinal fibromatosis with perinatal bowel obstruction. *Pediatr. Pathol.* 1984; 2:249-258.
- Pang LC. Intussusception revisited: Clinicopathologic analysis of 261 cases, with emphasis on pathogenesis. *South. Med. J* 1989; 82:215.
- Kill Rd, Suit III. Radiation therapy in the treatment of aggressive fibromatosis. *Cancer* 1981; 54:2051-2055.
- Li T, Li S, Liu K et al. Smooth muscle tumours of gastrointestinal tract: a study on correlation between pathology and prognosis and histogenesis. *Hua His I Ko Ta Hsueh Pao* 1990; 21:326-329.
- Batley B, Evans A. Nonsurgical management of children with recurrent or unresectable fibromas. *Pediatrics* 1987; 79:394-398.