

Severe hemorrhagic gastritis after percutaneous endoscopic gastrostomy tube placement

Abhijeet Waghray^a, Amy Michel-Calderon^b, Annette Kyprianou^b, Nisheet Waghray^b

MetroHealth Medical Center/Case Western Reserve University, Cleveland, OH, USA

A 53-year-old male with a past medical history significant for stage IV metastatic esophageal adenocarcinoma underwent palliative esophageal stenting for malignancy-related dysphagia. Laboratory values were significant for a hemoglobin of 10.0-11.2 g/dL (reference range: 12.0-15.0 g/dL). The medication list included therapeutic enoxaparin sodium injection for a history of prior pulmonary embolism. The patient subsequently presented with severe gastroesophageal reflux. Enoxaparin was stopped prior to esophagogastroduodenoscopy (EGD) for removal of the esophageal stent and placement of a percutaneous endoscopic gastrostomy (PEG) tube (Fig. 1). The patient tolerated the procedure and tube feeding was accordingly advanced. One week later, the patient presented with hematochezia and a hemoglobin of 6.8 g/dL. On physical examination the abdomen was soft and non-tender, with aspiration of the PEG tube revealing blood tinged tube feeds. A repeat EGD demonstrated severe gastritis as the likely source of gastrointestinal bleeding (Fig. 2). Patient had no documented allergies. Twice daily proton pump inhibitor and sucralfate four times per day were initiated.

Bleeding is a rare complication of PEG tube placement with most bleeding controlled by local pressure. Common causes are reflux esophagitis and gastric ulcer, while less common etiologies include vascular trauma involving the gastric wall or bleeding from the stomal tract [1-3]. To date, no cases of severe gastritis after PEG tube placement have been reported. Although bleeding occurs in 1% of cases, the role of long-term enteral nutrition and the risk/benefit of PEG tube placement must be individualized.

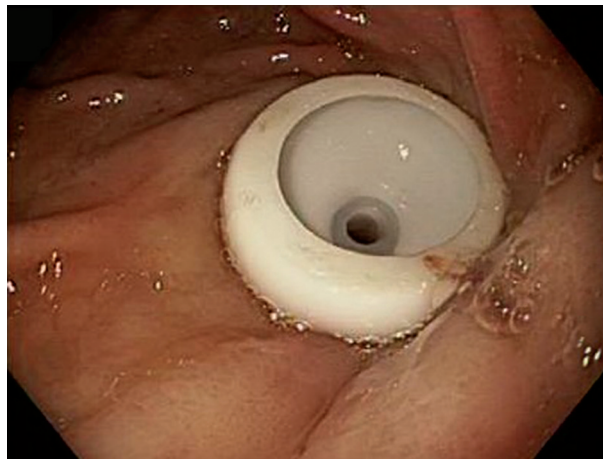


Figure 1 Gastric mucosa after percutaneous endoscopic gastrostomy tube placement

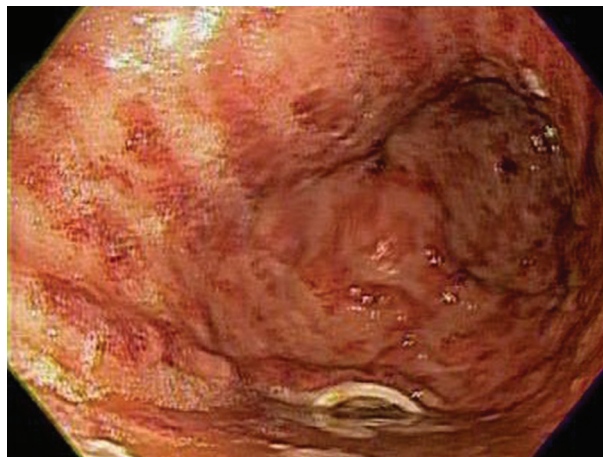

Figure 2 Severe gastritis 1 week after percutaneous endoscopic gastrostomy tube placement

Departments of ^aMedicine (Abhijeet Waghray); ^bGastroenterology (Amy Michel-Calderon, Annette Kyprianou, Nisheet Waghray), MetroHealth Medical Center/Case Western Reserve University, Cleveland, OH, USA

Conflict of Interest: None

Correspondence to: Dr. Abhijeet Waghray, MetroHealth Medical Center, 2500 Metrohealth Drive, Cleveland, Ohio 44109, USA, Tel.: +1 216 207 1228, e-mail: awaghray@metrohealth.org

Received 14 September 2015; accepted 16 September 2015

DOI: <http://dx.doi.org/10.20524/aog.2016.0017>

References

1. Mansoor H, Masood MA, Yusuf MA. Complications of percutaneous endoscopic gastrostomy tube insertion in cancer patients: a retrospective study. *J Gastrointest Cancer* 2014;45:452-459.
2. Schurink CA, Tuynman H, Scholten P, et al. Percutaneous endoscopic gastrostomy: complications and suggestions to avoid them. *Eur J Gastroenterol Hepatol* 2001;13:819-823.
3. Nishiwaki S, Araki H, Takada J, et al. Clinical investigation of upper gastrointestinal hemorrhage after percutaneous endoscopic gastrostomy. *Dig Endosc* 2010;22:180-185.