

## Case report

**Nimesulide-induced acute hepatitis**E. Cholongitas<sup>1</sup>, D. Koulenti<sup>1</sup>, K. Petraki<sup>2</sup>, G.V. Papatheodoridis<sup>1</sup>**SUMMARY**

**Nimesulide is a non-steroidal anti-inflammatory drug with a semiselective preferential inhibition of cyclooxygenase-2. We present a 57 year-old patient with jaundice and increased serum aminotransferases levels, who had been treated with nimesulide for the previous 10 days. Laboratory examinations excluded other causes of acute liver injury. Liver biopsy revealed lesions compatible with drug-induced hepatotoxicity. Bilirubin and liver enzymes returned to normal within three months of nimesulide discontinuation. In conclusion, use of nimesulide should be included among the causes of acute hepatitis. An established drug-associated hepatotoxicity will result in the immediate withdrawal of the drug in case of liver injury and the avoidance of its future use in certain individuals.**

**Key words:** nimesulide, drug-induced hepatotoxicity, hepatitis.

**INTRODUCTION**

Drug-induced liver injury is one of the main problems of the increasing use of drugs worldwide. It is estimated that more than 10% of adults hospitalized for acute hepatitis is drug related.<sup>1</sup> Non-steroidal anti-inflammatory drugs (NSAIDs) have infrequently been associated with liver injury.<sup>2</sup> However, the increasing proportion of old age persons in the population, which represent a group

with high-risk of drug-induced liver damage, and the frequent use of NSAIDs, mainly for musculoskeletal problems in the elderly, are expected to result in an increase in the incidence of NSAIDs associated liver lesions in the future.

We present the case of a 57 year-old patient with acute hepatitis associated with nimesulide. The history, clinical course and laboratory and histologic findings led to the conclusion that nimesulide caused the acute liver injury.

**CASE REPORT**

A 57 year-old female, pensioner, resident of Athens, was admitted to our Department with jaundice and fatigue of 3 days duration. Her past medical history included autoimmune hemolytic anemia diagnosed 20 years earlier, for which she had undergone splenectomy and was taking prednisolone and folic acid, and depression diagnosed 18 months earlier, for which she was taking citalopram. She also reported that she had been taking nimesulide 100 mg twice daily due to back pain for the ten days prior to admission. She had smoked 30 cigarettes a day for the previous 30 years, but denied any alcohol consumption. She had no history of recent contact with jaundiced subjects or exposure to any possible source of infection with hepatitis viruses. Her family history was unremarkable.

Physical examination revealed a woman in general good health. Her temperature was 36,8°C, blood pressure 110/70 mmHg and pulse rate 80/min. She was jaundiced and the liver was palpable 2cm below the right costal margin and moderately tender. The remaining physical examination was unremarkable. Her body mass index was 27.9 Kg/m<sup>2</sup>.

Laboratory values revealed: Hct 34%, Hb 11,7 g/dl, MCV 90,9 fl, MCH 35,4 pg, MCHC 39 g/dl, reticulocytes 10%, white blood count 19600/mm<sup>3</sup> (neutrophils 67%,

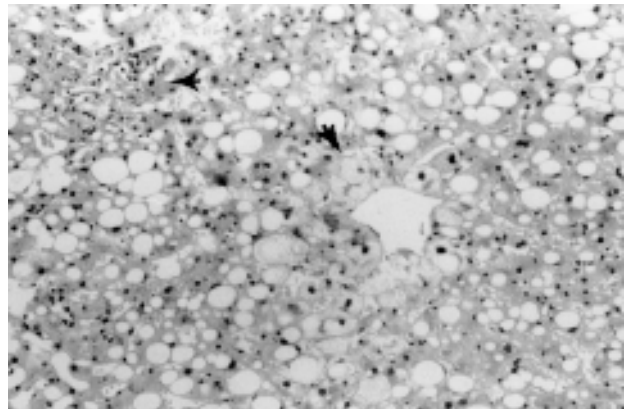
<sup>1</sup>Academic Department of Medicine, Hippokration General Hospital, Athens, Greece, <sup>2</sup>Department of Pathology, Hippokration General Hospital, Athens, Greece

*Author for correspondence:*

George V. Papatheodoridis, M.D., Lecturer in Medicine & Gastroenterology, Academic Department of Medicine, Hippokration Hospital of Athens, 114 Vas. Sofias ave., 11527 Athens, Greece, Tel: +30 210.7774742, Fax: +30 210.7706871, e-mail: gpapath@cc.uoa.gr

lymphocytes 27%, monocytes 6%), and normal platelet count (208.000/mm<sup>3</sup>). ESR was 15 mm/h, C-reactive protein was elevated (17,4 mg/dl, normal < 1). Prothrombin time was 13,6 sec (INR 1,19), total bilirubin 11,6 mg/dl (direct: 7 mg/dl), AST 1050 (normal < 40) IU/L, ALT 1030 (normal < 40) IU/L, ALP 126 (normal < 130) IU/L,  $\gamma$ GT 606 (normal < 40) IU/L. Other blood chemistry results, including glucose, cholesterol, triglycerides, serum amylase, uric acid, total serum protein, albumin, creatinine, BUN, Na, K, Ca as well as urinalysis were normal. Furthermore, serum levels of IgG, IgA, IgM, ceruloplasmin, ferritin, thyroid test were within the normal levels. HBsAg, IgM anti-HBc, anti-HBc, anti-HBs, IgM anti-HAV, anti-HCV, ANA, AMA, SMA, pANCA, cANCA, anti-LKM, anti-dsDNA, anti-EBV, anti-CMV, anti-HSV, tumour markers were negative. Serum HBV-DNA and HCV-RNA were undetectable by qualitative polymerase chain reaction assays. Electrocardiogram, chest x-ray, abdominal ultrasonography and computed tomography were normal.

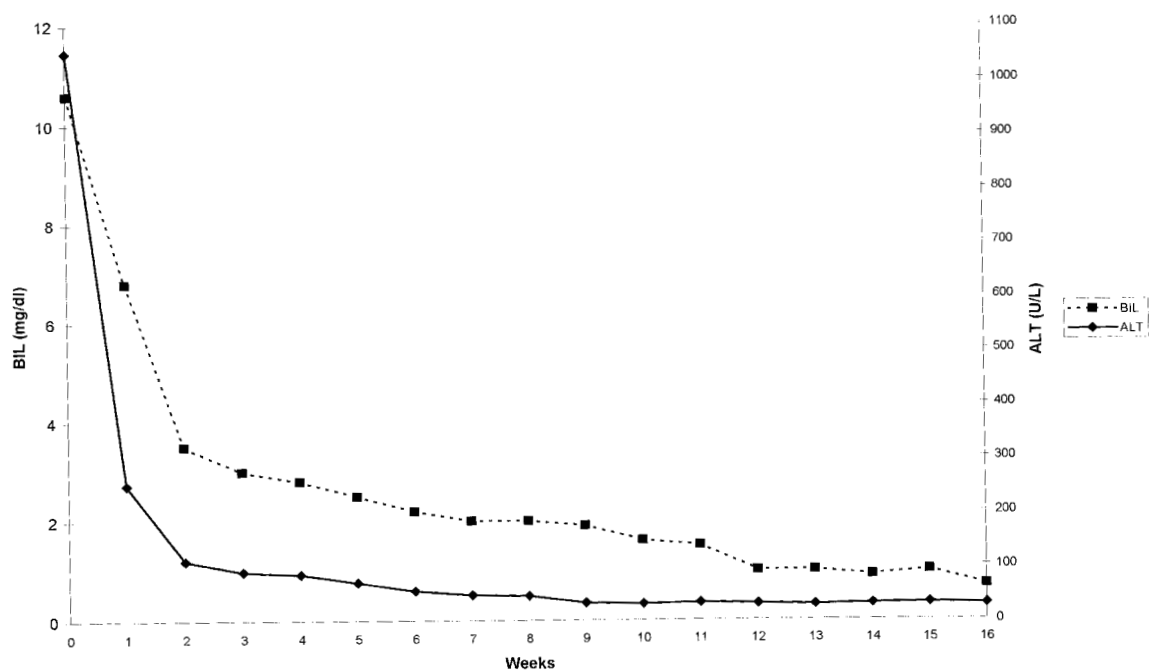
The liver biopsy showed preservation of the lobular architecture with mild portal and lobular inflammatory cell infiltrate composed of lymphocytes and neutrophils, fatty infiltration, ballooning degeneration of predominantly perivenular hepatocytes and focal hepatocellular necrosis (Fig. 1). These histological features were compatible with



**Figure 1:** Fatty infiltration, ballooning degeneration of zone 3 hepatocytes and lobular inflammation with hepatocellular lysis (arrows). H&E stain x 200

acute drug-induced hepatocellular damage.

During hospitalization, the patient remained on prednisolone, folic acid and citalopram, while nimesulide was immediately discontinued. Her liver function tests gradually improved and the jaundice disappeared. The patient was discharged seven days later. Her liver function tests returned to normal within 3 months and remained normal during the one year follow up period after discontinuation of nimesulide (Fig. 2).



**Figure 2:** Evolution of alanine aminotransferase (ALT) and total bilirubin levels in a patient with nimesulide-induced hepatitis after discontinuation of the drug

## DISCUSSION

Drugs have been estimated to cause 15-20% of all cases of fulminant and subfulminant hepatitis in western countries.<sup>1</sup> Early suspicion of a drug-related hepatic reaction is essential for prompt diagnosis, since the severity is greatly augmented if the drug is continued after the development of symptoms or the increase of serum transaminases.<sup>1</sup> Hepatotoxic drugs can cause a wide variety of liver lesions ranging from an asymptomatic mild increase in liver enzymes to acute liver failure.<sup>1</sup> Elderly women and individuals under treatment with more than one potentially hepatotoxic drugs are two groups with high risk for drug - induced liver injury.<sup>1</sup> The hepatotoxic drugs can be classified into intrinsic, or predictable, and idiosyncratic, or unpredictable, hepatotoxins.<sup>3</sup>

The causality assessment of drug-induced liver damage relies on chronological and clinical criteria attempting to eliminate of other causes and demonstrate the role of the offending drug.<sup>4</sup> Clinical criteria are based on the exclusion of other causes which might explain the liver injury and on the presence of features tending towards drug causality (age > 50 year, intake of a known hepatotoxic agent, specific serum autoantibodies, the presence of hypersensitivity manifestations).<sup>1</sup> Liver biopsy is not necessary in most cases, but it may be useful in order to eliminate other causes of liver injury, show lesions suggestive of drug-induced liver injury, or define lesions associated with drugs with so far unknown hepatotoxicity.<sup>1</sup> Chronological criteria consist of 1) the time interval between the beginning of the suspected treatment and the onset of liver injury, likely to be between 1 week and 3 (or even 12) months, 2) disappearance of liver abnormalities after withdrawal of the treatment, 3) relapse of liver abnormalities after an accidental readministration of the offending drug (re-exposure should not be on purpose, since it can be too dangerous).<sup>1</sup>

The above mentioned patient was admitted to our department because of jaundice and liver function abnormalities. Detailed laboratory tests were negative for all common causes of acute hepatitis. The liver biopsy showed lesions compatible with acute drug-induced hepatocellular damage. Fatty infiltration of the liver was probably associated with the chronic use of prednisolone and perhaps the patient's relatively increased body mass index. The clinical course was uneventful and the liver function tests returned to normal within 3 months of discontinuation of nimesulide. The patient remained on all other medication that she was taking at time of diagnosis of liver injury.

Nimesulide is a non-steroidal anti-inflammatory drug (NSAID) with preferential inhibitory action of cyclooxygenase type-2 (COX-2).<sup>5</sup> Because of its reduced propensity to cause adverse gastrointestinal effects,<sup>5</sup> it is often used in the treatment of inflammatory conditions (especially of the musculoskeletal system).<sup>6</sup> In addition, potential new indications include the prevention and/or retardation of some diseases, such as colon cancer or Alzheimer disease, which are characterized by increased COX-2 expression.<sup>6</sup>

NSAIDs are generally considered to be relatively safe drugs for the liver. It has been estimated that the incidence of acute liver injury is about 3,7 per 100.000 NSAIDs users per year.<sup>2</sup> In another study, acute liver injury developed in 3 of 726 patients treated with nimesulide.<sup>7</sup> However, reports of acute liver injury associated with nimesulide are increasing.<sup>5,8</sup> Furthermore, there were three cases of fatal hepatitis (two of them in Israel), which led to the temporary suspension of the drug in Israel,<sup>9,10</sup> and finally, to the re-introduction of the drug with the recommendation to perform liver function tests every 3 weeks and avoidance of concomitant medications with potential hepatotoxicity.<sup>11</sup> In Greece, there is only one published case report of acute liver disease from nimesulide to date.<sup>12</sup> Nimesulide seems to cause liver lesion more often in older women. Liver injury is more often of the hepatitic type, as it was in our patient, and more rarely of the cholestatic type.<sup>5</sup>

Hepatotoxicity mechanisms for many drugs remain unknown, but the study of the metabolism of known hepatotoxic drugs, such as halothane<sup>13</sup> and tienilic acid,<sup>14</sup> has facilitated the better understanding of these mechanisms. In the case of immunoallergic reactions, the metabolism of the hepatotoxic drug leads to the production of antibodies against auto-antigens of liver cells.<sup>15</sup> Nimesulide, like other NSAIDs, seems to belong to the immuneallergic drug, although, as in our case, hypersensitivity reactions such as skin rash and hypereosinophilia, may not develop.

In conclusion, nimesulide should be included among the causes of acute liver injury. Prompt diagnosis and discontinuation of the implicated hepatotoxic drug is crucial in the management of a drug-induced liver injury. However, prevention is more important and can be accomplished by careful drugs prescription, avoidance of simultaneous administration of more than one hepatotoxic drug (particularly in high-risk individuals) and certainly avoidance of readministration of the offending drug in an individual with a previous history of associated liver lesion.

**REFERENCES**

1. Larrey D. Drug-induced liver disease. *J Hepatol* 2000; 32 (Suppl 1): 77-88
2. Garcia-Rondriguez LA, Williams R, Derby LE, Dean AD, Jick H. Acute liver injury associated with non steroidal anti-inflammatory drugs and role risk factors. *Arch Intern Med* 1994; 154: 311-316
3. Sherlock S, Dooley J. Drugs and the Liver. In: Sherlock S, Dooley J (eds). *Diseases of the Liver and Biliary System*. 9<sup>th</sup> Edition. Blackwell Scientific Publications, London, 1993: 322-351
4. Benichou C. Criteria of drug-induced liver disorders. Report of an international consensus meeting. *J Hepatol* 1990; 11: 272-276
5. Van Steenberg W, Peeters P, De Bondt J, et al. Nimesulide-induced acute hepatitis: evidence from six cases. *J Hepatol* 1998; 29: 135-141
6. Hawkey CJ. COX-2 inhibitors. *Lancet* 1999; 353: 307-314
7. McCormick PA, Kennedy F, Curry M, Traynor O. COX-2 inhibitor and fulminant hepatic failure. *Lancet* 1999; 353: 40-41
8. Sbeit W, Krivoy N, Shiller M, et al. Nimesulide-induced acute hepatitis. *Ann Pharmacother* 2001; 35: 1049-1052
9. Weiss P, Moullem M, Bruck R, et al. Nimesulide-induced hepatitis and acute liver failure. *Isr Med Assoc J* 1999; 1: 89-91
10. Schattner A, Sokolovskaya N, Cohen J. Fatal hepatitis and renal failure during treatment with nimesulide. *J Intern Med* 2000; 247: 153-155
11. Elmalem E. Nimesulide, clavulanic acid and hepatitis. *J Intern Med* 2000; 248: 168-169
12. Dourakis PS, Sevastianos AV, Petraki K, Hadziyannis JS. Nimesulide-induced acute icteric hepatitis. *Iatriki* 2001; 79:275-278.
13. Kenna JG. Immunoallergic drug-induced hepatitis: lessons from halothane. *J Hepatol* 1997; 26 (Suppl. 1): 5-12
14. Robin M, Le Roy M, Descatoire V, Pessayre D. Plasma membrane cytochromes P450 as neoantigens and autoimmune targets in drugs-induced hepatitis. *J Hepatol* 1997; 26 (Suppl. 1): 23-30
15. Manns M, Obermayer-Straub P. Cytochromes P450 and uridine triphosphate glucuronosyltransferase: model autoantigens to study drug-induced, virus-induced, and autoimmune liver disease. *Hepatology* 1997; 26: 1054-1067