

Visible vessel in diverticular bleeding: a rare sighting

Kevin Cowley^a, Whitney H. Jennings^b, Chad Burski^b, Michael Passarella^b

University of Alabama at Birmingham, USA

A 64-year-old male with a remote history of upper gastrointestinal (GI) bleeding secondary to peptic ulcer disease presented to the emergency department after having hematochezia. He denied having abdominal pain, hematemesis, rectal tenderness, or prior hemorrhoids. Upon arrival to the emergency department, the patient had a syncopal event while having another episode of hematochezia. The patient was stabilized with intravenous fluids and 1 unit of packed red blood cells. His hematocrit remained stable, and he was prepped for colonoscopy overnight. Colonoscopy revealed moderately severe diverticulosis. Using an Olympus 190 colonoscope, a diverticulum was noted to have old blood covering it. After irrigation there was a non-bleeding visible vessel within the base of the diverticulum. Using the near-focus resolution and water immersion, the visible vessel was closely evaluated (Fig. 1). A Cook Instinct clip was then placed across the base of the visible vessel (Fig. 2). The patient tolerated the procedure well and had no further bleeding during his hospitalization.

Early colonoscopy is indicated as a safe and efficacious diagnostic and therapeutic modality for acute lower GI bleeding [1]. While diverticular bleeding is one of the most common causes of lower GI hemorrhage, greater than 70% of episodes resolve without intervention [2]. Stigmata of bleeding, such as adherent clot and non-bleeding visible vessel, have prognostic implications as these findings indicate a greater risk of re-bleeding, and thus warrant therapeutic intervention [2]. Mechanical hemostasis, which prevents early re-bleeding, can be safely achieved by endoscopic clipping technique [1], as demonstrated in our case.

^aTinsley Harrison Internal Medicine Residency Program (Kevin Cowley); ^bDepartment of Gastroenterology and Hepatology (H. Whitney Jennings, Chad Burski, Michael Passarella), University of Alabama at Birmingham, Alabama, USA

Conflict of interest: None

Correspondence to: Kevin Cowley, MD, Tinsley Harrison Internal Medicine Residency Program, 1720 2nd Ave. South, BDB 327, Birmingham, AL 35294, USA, Tel.: +1 205 934 2490, e-mail: kcowley@uabmc.edu

Received 11 June 2015; accepted 16 June 2015

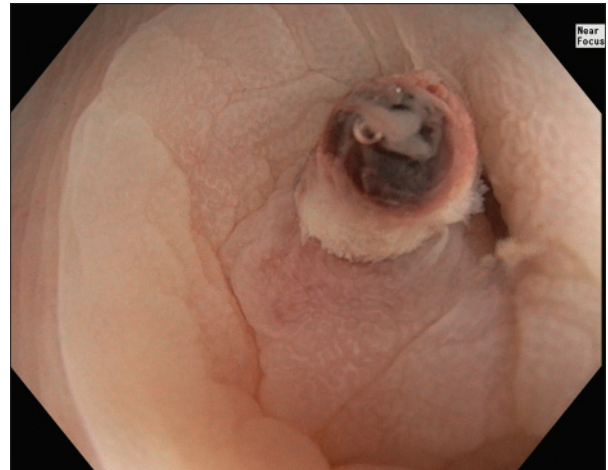


Figure 1 Diverticulum with non-bleeding visible vessel in the base of a diverticulum

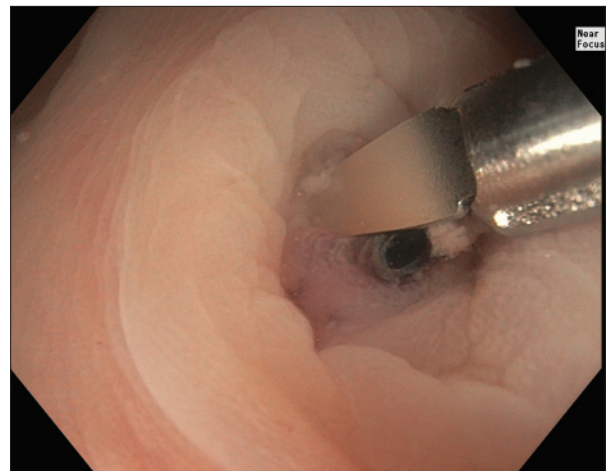


Figure 2 Cook Instinct clip placed across the base of visible vessel

References

1. Bloomfeld RS, Rockey DC, Shetzline MA. Endoscopic therapy of acute diverticular hemorrhage. *Am J Gastroenterol* 2001;**96**:2367-2372.
2. Kaltenbach T, Watson R, Shah J, et al. Colonoscopy with clipping is useful in the diagnosis and treatment of diverticular bleeding. *Clin Gastroenterol Hepatol* 2012;**10**:131-137.