

## Colonoscopic diagnosis of cecal worms (*Trichuris trichiura*)

Mel A. Ona, Haris Papafragkakis, Madhavi Reddy

The Brooklyn Hospital Center, NY, USA

Two unrelated Bangladeshi women, a 61-year-old with chronic diarrhea, lower abdominal pain, poor appetite, and weight loss for two years with normal physical exam and unremarkable laboratory tests; and a 58-year-old with epigastric pain, bloating, poor appetite, weight loss for three months, and iron-deficiency anemia, presented for colonoscopy. Colonoscopy revealed two white-colored worms in the cecum (Figs. 1, 2). The worms had a narrow anterior part embedded in the mucosa and a wide posterior part shaped like a whip protruding in the lumen. The worms were removed with biopsy forceps. Pathology/microbiology revealed *Trichuris trichiura*. Edematous colonic mucosa with focally increased eosinophils was reported in the latter case. Stool studies revealed few *Trichuris trichiura* ova. Both patients were treated with albendazole with subsequent symptom resolution.

*Trichuris trichiura* infection is endemic in tropical and subtropical countries [1]. When the infestation is limited, the carriers are usually asymptomatic. However, when the whipworm burden is high, anemia, abdominal pain, weight loss, appendicitis, obstruction, rectal prolapse, perforation, or bloody diarrhea may ensue [2]. Diagnosis is usually made by identification of barrel-shaped ova in stool. The parasite anchors to the mucosa at its anterior end, which makes it difficult to treat with anthelmintic agents.

Colonoscopy is an excellent diagnostic and therapeutic modality in infected persons living in non-endemic areas. The worm can be retrieved with the use of biopsy forceps. After endoscopic removal of the attached whipworms, anthelmintic therapy should be initiated. *Anisakis*, another parasitic worm with similar morphologic features, may confound the diagnosis [3].

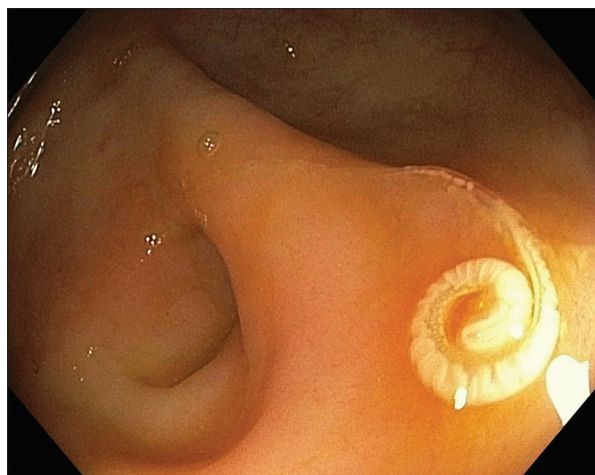


Figure 1 Endoscopic view of *Trichuris trichiura* in the cecum (next to appendiceal orifice)

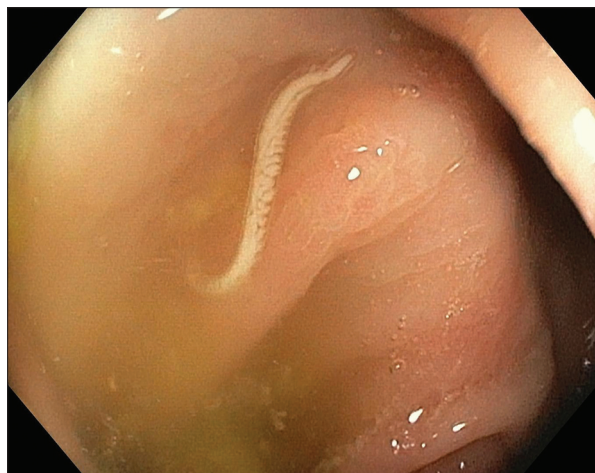

Figure 2 *Trichuris trichiura* in the cecum

### References

1. Wang DD, Wang XL, Wang XL, Wang S, An CL. Trichuriasis diagnosed by colonoscopy: case report and review of the literature spanning 22 years in mainland China. *Int J Infect Dis* 2013;**17**:e1073-e1075.
2. Ok KS, Kim YS, Song JH, et al. *Trichuris trichiura* infection diagnosed by colonoscopy: Case reports and review of literature. *Korean J Parasitol* 2009;**47**:275-280.
3. Do KR, Cho YS, Kim HK, et al. Intestinal helminthic infections diagnosed by colonoscopy in a regional hospital during 2001-2008. *Korean J Parasitol* 2010;**48**:75-78.

Department of Gastroenterology and Hepatology, The Brooklyn Hospital Center, USA

Conflict of Interest: None

Correspondence to: Mel A. Ona, Gastroenterology Department, The Brooklyn Hospital Center, 121 DeKalb Avenue Brooklyn, NY 11201, USA, e-mail: melaona@yahoo.com

Received 26 March 2015; accepted 31 March 2015