

Collagenous colitis with mucosal ulcerations in a patient without nonsteroidal anti-inflammatory drug or lansoprazole use

Andrew C. Berry^a, Rahman Nakshabendi^b, Hussein Abidali^c, Cassandra Johnson^d, Kevin Dholaria^e, Danny J. Avalos^f, Aaron C. Baltz^g

Kansas City University of Medicine and Biosciences; University of Florida College of Medicine-Jacksonville; Banner Good Samaritan Medical Center, Phoenix; University of South Florida, Tampa; University of Miami Miller School of Medicine, GI Associates, Wauwatosa, WI, USA

Abstract

Chronic watery diarrhea combined with normal-appearing colonic mucosa at endoscopy with abnormal histopathology is classified as microscopic colitis. Microscopic colitis encompasses both collagenous and lymphocytic colitis. A 42-year-old Caucasian woman presented with severe diarrhea for six weeks with loose watery stools every 1-2 h, approximately 15 episodes per day. She denied any melena or significant abdominal pain. She denied nonsteroidal anti-inflammatory drug or lansoprazole use, and was only taking diphenoxylate/atropine for her symptoms. Colonoscopy revealed superficial ulcerations in the distal ascending and transverse colon and scattered ulcerations in the descending and sigmoid colon, with biopsy confirming collagenous colitis. We report a rare case of collagenous colitis accompanied by mucosal ulcerations in the absence of known culprits of mucosal ulcerations, such as nonsteroidal anti-inflammatory drugs or lansoprazole.

Keywords Diarrhea, colonoscopy, colitis

Ann Gastroenterol 2015; 28 (3): 410-411

Introduction

Chronic diarrhea is defined as at least three loose stools a day of at least four weeks duration. Roughly 4-5% of the Western population reports chronic watery diarrhea, with microscopic colitis (MC) accounting for 10-20% [1]. Chronic watery diarrhea combined with normal-appearing colonic mucosa at endoscopy with abnormal histopathology is classified as MC. MC encompasses both collagenous (CC) and lymphocytic colitis (LC). CC typically presents in the 5th-8th decade with a female predominance and is characterized by

a thick sub-epithelial collagen band (>10 µm) in the basal membrane. Patients with CC do not typically present with colonic mucosal ulcerations, but, instead, historically present with few or no endoscopic findings [1-6]. We report a rare case of CC accompanied by mucosal ulcerations in the absence of known culprits of mucosal ulcerations, such as nonsteroidal anti-inflammatory drug (NSAID) or lansoprazole (LPZ) use.

Case report

A 42-year-old Caucasian woman presented with severe diarrhea for six weeks with loose watery stools every 1-2 h, approximately 15 episodes per day. The patient denied any fever, chills, weight loss, melena or rectal bleeding. She was not recently on any antibiotics, NSAIDs, proton pump inhibitors, or any medications other than diphenoxylate/atropine, started due to her symptoms. She had a 10-pack year smoking history. Complete blood count, complete metabolic panel, TSH, tissue transglutaminase IgA, and serum IgA were all normal. C-reactive protein and erythrocyte sedimentation rate were mildly elevated, 1.17 mg/L (normal <1.0 mg/L) and 22 mm/h (normal 0-20 mm/h in women <50 years old), respectively. Stool studies were negative for *Clostridium difficile* toxin, *Giardia* antigen (Ag), *Cryptococcus* Ag, stool culture, rotavirus Ag, and ova and parasite microscopic analysis. Physical examination was unremarkable with no complaint

^aKansas City University of Medicine and Biosciences (KCUMB), Kansas City (Andrew C. Berry); ^bDepartment of Medicine, University of Florida College of Medicine-Jacksonville, Jacksonville, FL (Rahman Nakshabendi); ^cDepartment of Medicine, Banner Good Samaritan Medical Center, Phoenix, AZ (Hussein Abidali); ^dUniversity of South Florida, Tampa, FL (Cassandra Johnson); ^eDepartment of Medicine, University of Miami Miller School of Medicine, Miami, FL (Kevin Dholaria); ^fDepartment of Medicine, University of Miami Miller School of Medicine: Palm Beach Regional Campus, Atlantis, FL (Danny J. Avalos); ^gGI Associates, Wauwatosa, WI (Aaron C. Baltz), USA

Conflict of Interest: None

Correspondence to: Andrew C. Berry, B.S., Kansas City University of Medicine and Biosciences (KCUMB), 1750 Independence Ave, Kansas City, MO 64106 USA, Tel.: +1 414 617 8877, e-mail: Aberry5555@gmail.com

Received 21 January 2015; accepted 23 February 2014

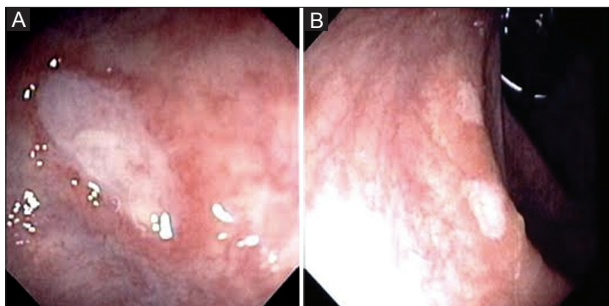


Figure 1 (A, B) Colonoscopy showing diffuse and superficial colonic mucosal ulcerations

of acute abdominal pain. Metronidazole was empirically started, without benefit. Colonoscopy revealed 4-5 superficial ulcerations in the distal ascending and transverse colon and a few scattered 3-5 mm ulcerations in the descending and sigmoid colon (Fig. 1A, B). Random biopsies from the cecum, ascending, transverse, descending, sigmoid colon, and rectum were taken with subsequent histological follow up confirming CC with superficial mucosal ulcerations. Regarding treatment, the patient was started on budesonide, tapered down over next two months and had normalization of bowel habits. She had recurrence of diarrhea when budesonide weaned off, so she was tried on both mesalamine and bismuth subsalicylate, without relief. Budesonide was restarted and symptoms remained well controlled over the past three years.

Discussion

MC is defined as chronic watery diarrhea combined with normal-appearing colonic mucosa at endoscopy with abnormal histopathology. Endoscopically, the colorectal mucosa appears normal in most patients with CC [1-6]. However, in up to 30% of CC cases, non-specific findings such as an abnormal vascular pattern, edema, and erythema have been reported. Though uncommon, linear ulcers, mucosal tears, and diffuse mucosal cloudiness have been recently reported in cases of CC [2-6].

A wide spectrum of medications have been associated with MC, such as: salicylates, ticlopidine, acarbose, flutamide, bentazepam, tardyferon, vinburnine, ranitidine, and LPZ [7]. CC patients with rare mucosal ulcerations have been specifically linked to NSAID and LPZ use [1,8]. The frequency of colonic ulcers in CC has been reported to be 1.9-3.0%, with almost all cases traced to current or prior NSAID or LPZ use [1,8]. Not only is it uncommon in general to have mucosal ulcerations in patients with CC, but it is extremely atypical without

NSAID or LPZ use, such as in our case. However, in cases with an identified known trigger medication, it is important to immediately discontinue the medication, as drug-induced mucosal ulcerations in patients with CC can lead to serious complications such as perforation and peritonitis [9]. The majority of patients who discontinue the trigger medication have resolution of diarrhea, ranging from prompt response to response three months after discontinuation [8].

In addition, studies have shown increased collagen band thickness and advanced age to be associated with colonic ulcerations in patients with CC [1,2]. Our patient presented with CC at the age of 42, much earlier in life than most cases presenting in the 5th-8th decade of life [1,2]. Previous reports have shown that chronic smokers, as in our patient, can present with CC greater than 10 years earlier than non-smokers [10]. Although chronic watery diarrhea has a wide differential, CC accompanied by mucosal ulcerations must be considered even in the absence of NSAID or LPZ use.

References

1. Saito S, Tsumura T, Nishikawa H, et al. Clinical characteristics of collagenous colitis with linear ulcerations. *Dig Endosc* 2014;**26**:69-76.
2. Koulaouzidis A, Saeed AA. Distinct colonoscopy findings of microscopic colitis: not so microscopic after all? *World J Gastroenterol* 2011;**17**:4157-4165.
3. Madalinski M, Koulaouzidis A. Collagenous colitis with mucosal tears in two proton pump inhibitors and non-steroidal naive patients who developed metachronous cancer. *J Dig Dis* 2013;**14**:51-53.
4. Langner C, Aust D, Ensari A, et al; the Working Group of Digestive Diseases of the European Society of Pathology (ESP) and the European Microscopic Colitis Group (EMCG). Histology of microscopic colitis-review with a practical approach for pathologists. *Histopathology* 2015;**66**:613-626.
5. Münch A, Aust D, Bohr J, et al. European Microscopic Colitis Group (EMCG). Microscopic colitis: Current status, present and future challenges: statements of the European Microscopic Colitis Group. *J Crohns Colitis* 2012;**6**:932-945.
6. Bohr J, Tysk C, Eriksson S, Albrahimsson H, Järnerot G. Collagenous colitis: A retrospective study of clinical presentation and treatment in 163 patients. *Gut* 1996;**39**:846-851.
7. Cappel MS. Colonic toxicity of administered drugs and chemicals. *Am J Gastroenterol* 2004;**99**:1175-1190.
8. Kakar S, Pardi DS, Burgart LJ. Colonic ulcers accompanying collagenous colitis: implication of nonsteroidal anti-inflammatory drugs. *Am J Gastroenterol* 2003;**98**:1834-1837.
9. Freeman HJ, James D, Mahoney CJ. Spontaneous peritonitis from perforation of the colon in collagenous colitis. *Can J Gastroenterol* 2001;**15**:265-267.
10. Vignren L, Sjöberg K, Benoni C, et al. Is smoking a risk factor for collagenous colitis? *Scand J Gastroenterol* 2011;**46**:1334-1339.