

Endoscopic ultrasound-guided transmural drainage of calcified pseudocyst in a patient with chronic calcific pancreatitis

Surinder Singh Rana^a, Vishal Sharma^a, Ravi Sharma^a, Rajesh Gupta^b, Deepak Kumar Bhasin^a

Post Graduate Institute of Medical Education and Research (PGIMER), Chandigarh, India

A 42-year-old male presented with increasing abdominal pain and a palpable lump since 2 weeks. He had history of significant alcohol intake. Contrast-enhanced computed tomography (CT) of the abdomen revealed calcification in the head of pancreas and a large pseudocyst adjacent to the body and tail of pancreas (Fig. 1A). The wall of the pseudocyst adjacent to the stomach had multiple calcific specks (Fig. 1A). There was no bulge on gastroscopy and therefore the patient was taken up for endoscopic ultrasound (EUS)-guided transluminal drainage of the pseudocyst. EUS revealed a large pseudocyst with multiple calcific specks in its wall (Fig. 1B). The cyst was punctured avoiding these calcific specks and after dilatation of the tract to 12 mm a 7 Fr double pigtail biliary stent was placed (Fig. 1C, D). The patient had marked improvement in his symptoms and the lump disappeared. The patient was discharged on the fourth day of drainage and a repeat CT 2 weeks later revealed complete resolution of the cyst.

EUS-guided drainage has been shown to manage efficiently pancreatic fluid collections even in the absence of fluoroscopic control [1]. EUS provides an opportunity to drain collections distant from the gastrointestinal lumen, without a visible bulge in the stomach or the duodenum, and with vascular collaterals in the wall. Calcification of the wall of the pseudocyst is uncommon and represents a long drawn chronic process. The calcified pseudocysts are usually treated surgically but the advent of EUS has also made endoscopic drainage possible [2,3]. The present case

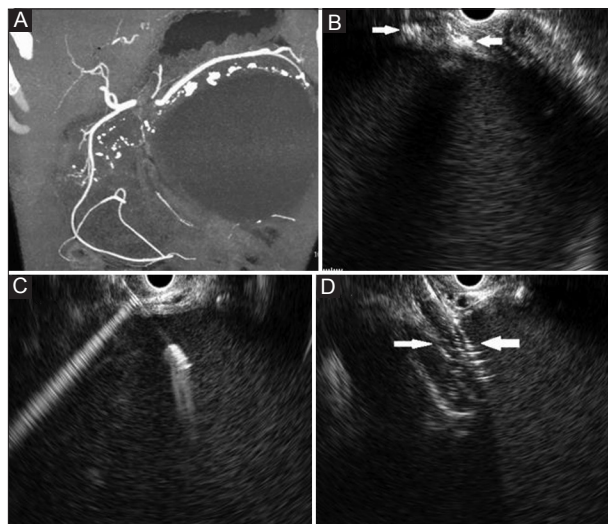


Figure 1 (A) Large pseudocyst with calcific specks in its wall. Parenchymal calcification in the head is also noted. (B) Endoscopic ultrasound (EUS): Large pseudocyst with calcification in the wall (arrow). Posterior acoustic shadowing is also seen. (C) EUS-guided needle puncture of the pseudocyst. (D) Dilatation of the tract by balloon under EUS guidance (arrows)

suggests that EUS-guided drainage of a calcified pseudocyst is safe and effective.

Departments of ^aGastroenterology (Surinder Singh Rana, Vishal Sharma, Ravi Sharma, Deepak Kumar Bhasin); ^bSurgery (Rajesh Gupta), Post Graduate Institute of Medical Education and Research (PGIMER), Chandigarh, India

Conflict of Interest: None

Correspondence to: Dr Surinder Singh Rana, Department of Gastroenterology, PGIMER, Chandigarh, 160 012, India, Tel.: +91 172 2749123, Fax: +91 172 2744401, e-mail: drsurinderrana@yahoo.co.in

Received 15 September 2014; accepted 29 September 2014

References

1. Rana SS, Bhasin DK, Rao C, Gupta R, Singh K. Non-fluoroscopic endoscopic ultrasound-guided transmural drainage of symptomatic non-bulging walled-off pancreatic necrosis. *Dig Endosc* 2013;**25**:47-52.
2. Lee KF, Yau CK, Lai PB. Image of the month: calcified pancreatic pseudocyst. *Arch Surg* 2006;**141**:419-420.
3. Ghahremani GG, Hemmati M, Savage JL. Calcified pseudocyst of the pancreas. *Dig Dis Sci* 1981;**26**:1138-1143.