

Unusual endoscopic presentation of eosinophilic gastroenteropathy

Girish Hiremath^a, Carla M. Davis^b, John Hicks^c, Anthony Olivé^a

Texas Children's Hospital, Baylor College of Medicine, USA

An 11-year-old boy with extensive food and environmental allergies, and poorly controlled eosinophilic gastroenteropathy (EG) over an 8-year period was evaluated as a referral patient. At presentation, he was hypogammaglobulinemic and was being managed with allergy test-directed food avoidance, oral proton pump inhibitors therapy, iron supplementation, second generation antihistaminic and subcutaneous immunotherapy. His history was significant for severe anemia requiring transfusion on two occasions, hematemesis, and hypoalbuminemia. Capsule endoscopy revealed scattered focal erythematous flat, erosive lesions in the duodenum and jejunum.

Esophagogastroduodenoscopy revealed multiple pseudopolyps in the antrum (Fig. 1A), and numerous prominent linear furrows were observed in the body and the lesser curvature (Fig. 1B). The pseudopolyps in antrum were arranged symmetrically and appeared to track towards the antroduodenal opening. Histopathological examination of biopsies obtained from the body, antrum and pseudopolyp revealed markedly increased eosinophils (63, 121 and 57 eosinophils/high power field, respectively) without mucosal erosion or ulceration, increased chronic inflammatory cells, lymphoid aggregates, or features of inflammatory bowel disease (Fig. 2). No *Helicobacter*-like organisms or viral inclusions were seen. The endoscopic appearance and histopathological evaluation of the esophagus, duodenum and colon were unremarkable. This patient was initiated on 6-mercaptopurine with follow-up endoscopy planned.

EG is a chronic inflammatory condition characterized by diffuse eosinophilic infiltration in the mucosa of the stomach and/or small intestine, as seen with the present case [1]. While EG presenting as erythema, friable mucosa with or without ulceration and gastric/duodenal pseudopolyps have been previously reported [2], the unusual presentation of multiple gastric pseudopolyps with furrowing is being reported for the first time, and this could be a feature of long-standing EG.

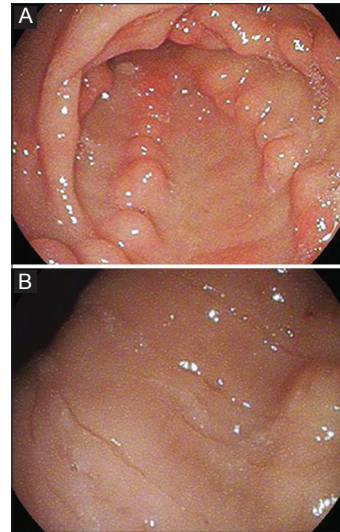


Figure 1 (A) Symmetrically distributed pseudopolyps over antrum. (B) Furrowing noted over lesser curvature of the stomach

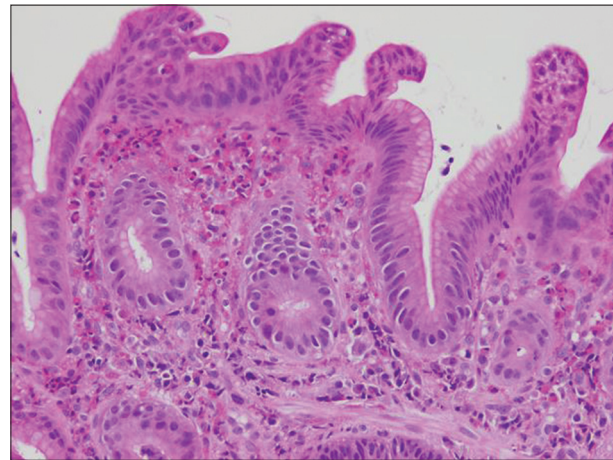


Figure 2 Antral polyp with markedly increased eosinophils without increased chronic inflammatory cells, consistent with eosinophilic gastritis. The mucosa is intact and without erosion or ulceration (H&E, original magnification 200x)

^aPediatric Gastroenterology, Hepatology and Nutrition (Girish Hiremath, Anthony Olivé); ^bPediatric Allergy and Immunology (Carla M. Davis); ^cPathology and Pediatrics (John Hicks), Texas Children's Hospital, Baylor College of Medicine, USA

Conflict of Interest: None

Correspondence to: Girish Hiremath, MD MPH, 6671 Fannin Street, 1010 CCC, Houston, Texas, 77054 USA, e-mail: hiremath@bcm.edu

Received 25 June 2014; accepted 3 July 2014

© 2015 Hellenic Society of Gastroenterology

References

1. Kelly KJ. Eosinophilic gastroenteritis. *J Pediatr Gastroenterol Nutr* 2000;**30**(Suppl):S28-S35.
2. Chehade M, Sicherer SH, Magid MS, Rosenberg HK, Morotti RA. Multiple exudative ulcers and pseudopolyps in allergic eosinophilic gastroenteritis that responded to dietary therapy. *J Pediatr Gastroenterol Nutr* 2007;**45**:354-357.

www.annalsgastro.gr