

Unusual presentation of a gastrointestinal stromal tumor of the duodenum mimicking an inflammatory enlargement of a peripancreatic lymph node

Gianfranco Donatelli^a, Bertrand M. Vergeau^a, Gilles Roseau^b, Bruno Meduri^a

Hôpital Privé des Peupliers, Générale de Santé; Clinique du Trocadero, Paris, France

Gastrointestinal stromal tumors (GISTs) are low-grade malignant mesenchymal tumors of GI tract and are believed to originate from malignant transformation of the interstitial cells of Cajal from their precursors [1]. Duodenal GISTs are usually exophytic and appear as submucosal swellings [2]; however, in the absence of specific mucosal changes or anatomical variations of the duodenal lumen, it may be difficult to differentiate a duodenal GIST from a malignant lymphoma, duplication cyst, retroperitoneal tumor, or pancreatic head tumor [1].

We present a case of a 40-year-old woman referred for endoscopic ultrasound (EUS), after she was submitted to a contrast-enhanced spiral computed tomography scan for diffuse abdominal pain, which showed a mass of 2 cm at the level of the internal part of pancreas suggesting a neuroendocrine tumor. Biochemistry and tumor markers were within normal limits.

At the level of the second part of the duodenum, a hypoechoic pericholedochal mass was visualized, between the pancreatic head and the duodenal wall, well-delineated, multilobular, seemingly not deriving either from the duodenal wall or from the pancreatic parenchyma, suggesting an inflammatory enlargement of a lymph node given its appearance, i.e. triangular, homogeneous, and grayish (Fig. 1A). However, because of its abnormal size, we decided to proceed to EUS fine needle aspiration (FNA) biopsy (Fig. 1B). Surprisingly, histology confirmed a GIST characterized by spindled cells (Fig. 2), strongly reactive to the antibody DOG1, with a proliferation index counted by Ki67 antibody to less than 5%.

In conclusion, EUS presentation of the GIST might mimic various pathologies, and, in order to avoid misdiagnosis of an apparently unusual lesion during EUS, a well-detailed wall layer study is necessary to guide diagnosis, and EUS-FNA is mandatory for histological confirmation.

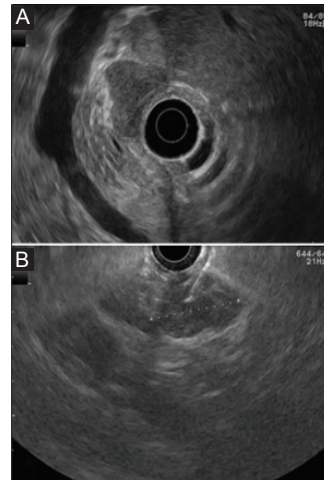


Figure 1 (A) Hypoechoic, triangular, homogeneous, grayish mass evoking an inflammatory enlargement of lymph node mass between the pancreas and the duodenal wall. (B) Endoscopic ultrasound fine needle aspiration biopsy of the lesion

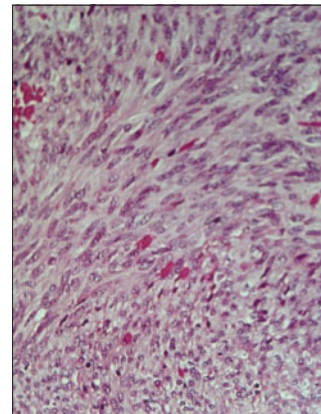


Figure 2 Gastrointestinal stromal tumor characterized by spindled cells

^aUnité d'Endoscopie Interventionnelle, Hôpital Privé des Peupliers, Générale de Santé (Gianfranco Donatelli, Bertrand M. Vergeau, Bruno Meduri); ^bClinique du Trocadero (Gilles Roseau), Paris, France

Conflict of Interest: None

Correspondence to: Gianfranco Donatelli, Hôpital Privé des Peupliers, Générale de Santé, Unité d'Endoscopie Interventionnelle, 8 Place de l'Abbé G. Hénocque 75013 Paris, France, e-mail: endoscopie@gmail.com

Received 9 March 2014; accepted 13 May 2014

© 2014 Hellenic Society of Gastroenterology

References

1. Kwon SH, Cha HJ, Jung SW, et al. A gastrointestinal stromal tumor of the duodenum masquerading as a pancreatic head tumor. *World J Gastroenterol* 2007;13:3396-399.
2. Acar F, Sahin M, Ugras S, et al. A gastrointestinal stromal tumor of the third portion of the duodenum treated by wedge resection: A case report. *World J Gastrointest Surg* 2013;5:332-336.

www.annalsgastro.gr