

## The role of protease-activated receptors in regulating other ion channels

Michael Eisenhut

Luton and Dunstable University Hospital NHS Foundation Trust, Luton, United Kingdom

The authors of a recent review article on the main ion channels and receptors associated with visceral hypersensitivity in irritable bowel syndrome (IBS) emphasized the key role of protease-activated receptors (PAR)-2 in visceral hyperalgesia [1]. For the understanding of symptoms of IBS, it is fundamental to understand the interaction of ion channels systems: PAR-2 has been shown to potentiate transient receptor potential vanilloid (TRPV) 1 activation through protein kinase (PK) C- and PKA-dependent mechanisms. This involves translocation of these PKs to the plasma membrane and phosphorylation of TRPV1 as demonstrated for dorsal root ganglia cells. Inhibition of PKC in rats *in vivo* inhibited the hyperalgesic response to PAR-2 agonists and capsaicin, the TRPV1 stimulator [2]. Another interaction of ion channels, which may help understand the symptom of diarrhea if it is not related to increased peristalsis in a variant of IBS, has become evident from more recent experiments in an intestinal epithelial cell line mounted in Ussing chambers. It was revealed that basolateral PAR-2 activation induces cystic fibrosis transmembrane-conductance regulator (CFTR)-mediated chloride secretion by prostaglandin (PG) E2 confirming the general applicability of this mechanism, previously thought to be the likely explanation for PGE2- and PGF1-mediated stimulation of chloride secretion by PAR-2 activation [3]. The interaction with CFTR may explain changes in bowel habit by inducing the diarrhea phenotype of IBS because chloride secretion is a key event in the pathogenesis of secretory diarrhea through reduction in the osmotic gradient across intestinal epithelial cells.

Consequently, therapeutic studies are warranted to explore PKC and PG inhibitors in the treatment of IBS-related symptoms.

### References

- de Carvalho Rocha HA, Dantas BP, Rolim TL, Costa BA, de Medeiros AC. Main ion channels and receptors associated with visceral hypersensitivity in irritable bowel syndrome. *Ann Gastroenterol* 2014;27:200-206.
- Amadesi S, Cottrell GS, Divino L, et al. Protease-activated receptor 2 sensitizes TRPV1 by protein kinase Cε and A-dependent mechanisms in rats and mice. *J Physiol* 2006;575:555-571.
- van der Merwe JQ, Ohland CL, Hirota CL, MacNaughton WK. Prostaglandin E2 derived from cyclooxygenases 1 and 2

mediates intestinal epithelial ion transport stimulated by the activation of protease-activated receptor 2. *J Pharmacol Exp Ther* 2009;329:747-752.

Department of Pediatrics, Luton and Dunstable University Hospital NHS Foundation Trust, Luton, United Kingdom

Conflict of Interest: None

Correspondence to: Michael Eisenhut, Luton & Dunstable University Hospital NHS Foundation Trust, Luton, United Kingdom, Tel.: +44 8451270127, e-mail: michael\_eisenhut@yahoo.com

Received 1 August 2014; accepted 4 August 2014

## Is the use of non-selective beta-blockers necessary in cirrhotic patients with small varices?

Xingshun Qi<sup>a,b</sup>, Xiaozhong Guo<sup>a</sup>, Daiming Fan<sup>b</sup>

<sup>a</sup>General Hospital of Shenyang Military Area, Shenyang;

<sup>b</sup>Xijing Hospital of Digestive Diseases, Fourth Military Medical University, Xi'an, China

Non-selective β-blockers (NSBBs) could effectively prevent the development of first variceal bleeding in cirrhotic patients with medium/large varices. However, as recently reviewed by Giannelli *et al* [1], the clinical benefit of NSBBs remains controversial in cirrhotic patients with small varices. In line with their considerations, we would like to further comment on the controversy.

A previous meta-analysis demonstrated that the incidence of first variceal bleeding was not different between patients with small varices who received NSBBs and those who did not [2]. On the other hand, two randomized controlled trials (RCT) demonstrated that NSBBs could not prevent the development of large varices in patients with small varices. In a previous study by Cales *et al*, the NSBB group had a higher proportion of development of large varices than the placebo group (52/60 versus 30/67, P<0.0001, Chi-square test) [3]. In a recent study by Sarin *et al*, the cumulative incidence of growth of varices was similar between NSBB and placebo groups (11% versus 16%, P=0.786, log-rank test) [4]. By contrast, another RCT by Merkel *et al* achieved a positive result, suggesting that the cumulative risk of growth of varices was significantly lower in the NSBB group than in the placebo group (20% versus 51%, P<0.001, log-rank test) [5]. But it should be noted that NSBB did not improve the survival and increase the rate of adverse events.

Taken together, we should acknowledge the inconsistency of evidence regarding the benefit of NSBBs for the management of small varices in liver cirrhosis. Additionally, given the potential drug-related adverse events, the use of NSBBs might be unnecessary in such patients.

## References

1. Giannelli V, Lattanzi B, Thalheimer U, Merli M. Beta-blockers in liver cirrhosis. *Ann Gastroenterol* 2014;**27**:20-26.
2. D'Amico G, Pagliaro L, Bosch J. The treatment of portal hypertension: a meta-analytic review. *Hepatology* 1995;**22**:332-354.
3. Cales P, Oberti F, Payen JL, et al. Lack of effect of propranolol in the prevention of large oesophageal varices in patients with cirrhosis: a randomized trial. French-Speaking Club for the Study of Portal Hypertension. *Eur J Gastroenterol Hepatol* 1999;**11**:741-745.
4. Sarin SK, Mishra SR, Sharma P, Sharma BC, Kumar A. Early primary prophylaxis with beta-blockers does not prevent the growth of small esophageal varices in cirrhosis: a randomized controlled trial. *Hepatol Int* 2013;**7**:248-256.
5. Merkel C, Marin R, Angeli P, et al. A placebo-controlled clinical trial of nadolol in the prophylaxis of growth of small esophageal varices in cirrhosis. *Gastroenterology* 2004;**127**:476-484.

<sup>a</sup>Department of Gastroenterology, General Hospital of Shenyang Military Area, Shenyang (Xingshun Qi, Xiaozhong Guo); <sup>b</sup>Xijing Hospital of Digestive Diseases, Fourth Military Medical University, Xi'an (Xingshun Qi, Daiming Fan), China

Conflict of Interest: None

Correspondence to: Prof. Xiaozhong Guo, Department of Gastroenterology, General Hospital of Shenyang Military Area, No 83 Wenhua Road, Shenyang, China, e-mail: guo\_xiao\_zhong@126.com

Received 15 July 2014; accepted 16 July 2014

## Successful peroral endoscopic myotomy for radical treatment of sigmoid-type esophageal achalasia by Greek gastroenterologists

**Nikolas Eleftheriadis<sup>a</sup>, Andreas Protopapas<sup>a</sup>, John Katsogridakis<sup>b</sup>, Apostolos I. Hatzitolios<sup>a</sup>**

AHEPA University Hospital, Aristotle University of Thessaloniki; Gastroenterology Unit of Athens, Greece

Peroral endoscopic myotomy (POEM) is currently considered the least invasive, innovative endoscopic intervention for permanent treatment of all types of esophageal achalasia [1]. POEM, however, is a technically demanding procedure, necessitating high-quality endoscopic abilities to manage the individualized technical difficulties. Herein we report a successful POEM in a 75-year-old male with sigmoid-type achalasia performed by Greek gastroenterologists.

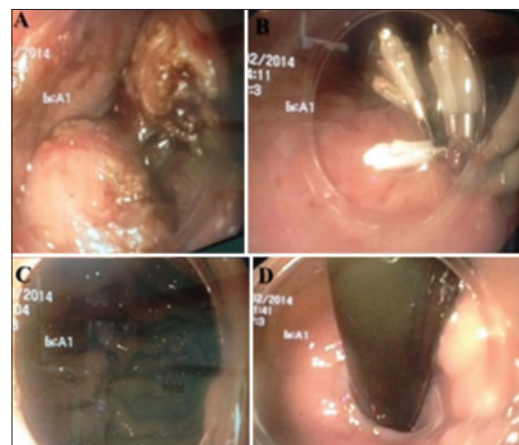
The patient had a 45-year history of achalasia, diagnosed by manometry, endoscopy and esophagogram, treated by repeated balloon dilatations up to 40 mmHg. He also

had a history of coronary bypass surgery and was under anticoagulants and antianginal drugs. He was referred for POEM due to severe deterioration of dysphagia despite treatment, including nitrates for his angina. Eckard score was 10 (stage III). Control esophagoscopy revealed esophageal dilatation and fluid stasis, resistance at gastroesophageal junction (GEJ) and sigmoid type I achalasia, according to Inoue *et al* [1].

Esophagogram showed esophageal dilatation >3 cm and high lower esophageal sphincter (LES) pressure. After detailed information the patient agreed and signed to undergo POEM, performed at AHEPA Hospital, Aristotle University of Thessaloniki, according to Inoue's [1] technique (Fig. 1). CO<sub>2</sub> insufflation was administered during procedure, while Triangle-T knife was exclusively used for submucosal tunnel creation and myotomy. Selective circular myotomy 15 cm in length, 13 cm at the esophageal and 2 cm at the gastric side, was finally completed, without serious complications.

Special problems, which prolonged POEM duration (3 h), were: a) the extremely thick circular muscle, which made myotomy difficult and time consuming; b) difficulty in orientation within the submucosal space and identification of GEJ due to sigmoid esophagus. Continuous control within the esophageal lumen and retroversion in the stomach and identification of ectopic longitudinal muscle fiber [2] in front of circular muscle when approaching GEJ were helpful to extend myotomy to the gastric side; c) severe mucosal bleeding was controlled using coagulation forceps, paying attention to coagulate the vessel and avoid mucosal perforation; d) mucosal entry closure was completed with difficulty after many attempts (25 clips) and longer fasting (to 3 days).

Esophagogram and control endoscopy the day after POEM showed intact esophageal mucosa, no leakage and open GEJ with no resistance (Fig. 1B-D). He was discharged on day 3 post-operatively. During the two-month follow up he reported almost complete relief of dysphagia.



**Figure 1** Endoscopic image during peroral endoscopic myotomy. (A) Thick circular muscle during myotomy. (B) Closure of the mucosal entry by clips. (C) Open gastroesophageal junction (GEJ) at forward view and (D) open GEJ at retroversion

According to this difficult and technically demanding case, we consider POEM feasible, safe and effective treatment, even for sigmoid-type esophageal achalasia, by Greek Gastroenterologists. Although it has been already proved that POEM is possible in sigmoid type achalasia, international experience in these advanced cases is still limited, and this is the first successful Greek case. Further experience and long-term results are necessary and awaited.

## Acknowledgement

Prof. Dr. Haruhiro Inoue (Digestive Disease Center, Showa University Northern Yokohama Hospital, Japan) for POEM training and case consultation

## References

1. Inoue H, Minami H, Kobayashi Y, et al. Peroral endoscopic myotomy (POEM) for esophageal achalasia. *Endoscopy* 2010;42:265-271.
2. Eleftheriadis N, Inoue H, Ikeda H, et al. *In vivo* observation of aberrant innermost longitudinal muscle bundles in front of the circular muscle layer at the level of the esophagogastric junction during peroral endoscopic myotomy. *Gastrointest Endosc* 2013;78:676.

<sup>a</sup>1<sup>st</sup> Propedeutic Department of Internal Medicine, AHEPA University Hospital, Aristotle University of Thessaloniki (Nikolas Eleftheriadis, Andreas Protopapas, Apostolos I. Hatzitolios); <sup>b</sup>Gastroenterology Unit of Athens (John Katsogridakis), Greece

Conflict of Interest: None

Correspondence to: Nikolas Eleftheriadis, Scientific Associate, A' Propedeutic Department of Internal Medicine, AHEPA University Hospital, Thessaloniki, Greece, Tel.: +30 6977 778832, e-mail: nikoseleftheriadis@yahoo.com

Received 20 April 2014; accepted 20 April 2014

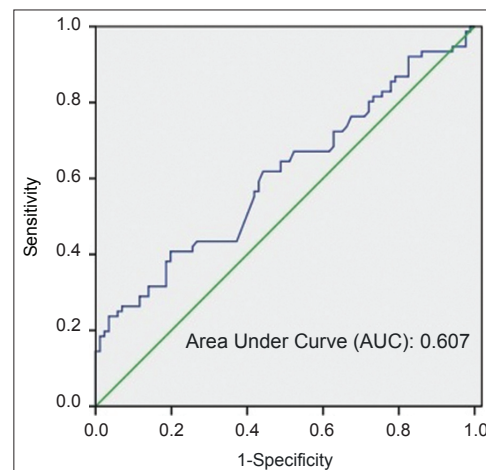
## Neutrophil-to-lymphocyte ratio as a sensitive marker in diagnosis of celiac disease

**Murat Sarikaya, Zeynal Dogan, Bilal Ergul, Levent Filik**

Ankara Education and Research Hospital, Ankara, Turkey

Celiac disease (CD) is a small intestinal mucosal disease leading to malabsorption due to inflammatory reaction

to gluten [1-4]. CD has a prevalence of approximately 1% of the population. But, it is estimated that up to 90% are undiagnosed due to subclinical presentations [5]. Also, diverse clinical manifestations can lead to delays in diagnosis [4]. Laboratory indices and biomarkers used in daily general medical practice are important in detecting new cases of CD, otherwise a delayed diagnosis can lead to development of important complications such as osteoporosis [6-9]. Neutrophil-to-lymphocyte ratio (NLR) was introduced as a useful index for diagnosis or prognosis of different diseases [7]. We hypothesized that NLR might change in patients with CD as an inflammatory disease. Blood count changes such as anemia, leukopenia are well-known but there is no data for NLR in CD [8,9]. In this regard, we prospectively checked the diagnostic role of the NLR in 76 patients with CD (M:26, F:50) at the time of diagnosis. Diagnosis of study patients was based on celiac antibodies (anti-gliadin, anti-endomysium and tissue transglutaminase), and duodenal biopsy [1,10]. Eighty-six patients with functional dyspepsia (M:33, F:53), all of whom had a normal complete blood cell count, C-reactive protein (CRP), and negative serology for anti-gliadin and anti-endomysium antibodies were recruited as control group. Statistical analyses were performed using SPSS version 17.0. Chi-square test was used for comparison of categorical variables. A P-value <0.05 was considered statistically significant. The Receiver Operating Characteristics (ROC) curve analysis was carried out to indicate the sensitivity and specificity of NLR and its respective optimal cut-off value for predicting CD. Mean ages of groups were  $38.5 \pm 12.11$  years in CD patients and  $36.5 \pm 12.2$  years in controls ( $P > 0.05$ ). NLR was significantly higher in patients with CD ( $2.42 \pm 1.24$ ) when compared to control group ( $1.92 \pm 0.58$ ) ( $P < 0.019$ ). The success of NLR in diagnosing CD was statistically remarkable when tested with ROC analysis (Fig. 1). The cut-off value of NLR was 2.32. According to this cut-off value, sensitivity was 80% and specificity 41%.



**Figure 1** The receiver-operating characteristic curve of neutrophil-to-lymphocyte ratio for predicting celiac disease

Neutrophils and lymphocytes are the cells that play a major role in inflammatory processes. Therefore, counts of neutrophils and lymphocytes temporarily change in inflammation. Cellular immunity obviously plays a major role in intestinal damage in CD [1,2,8]. The main pathogenesis of CD is believed to be related to a gluten-specific T-lymphocyte-mediated response resulting in an overexpression of interferon- $\gamma$  in the epithelial compartment [1]. Inflammation is not confined to duodenum but also involves other gastrointestinal mucosa. Accordingly, surface lymphocytic infiltration of the stomach and colon can also be seen [9]. NLR change seems to be linked with this inflammation and cytokines. In conclusion, NLR might be used as a sensitive laboratory index in screening and diagnosis of CD.

## References

1. Ciclitira PJ. Recent advances in coeliac disease. *Clin Med* 2003;**3**:166-169.
2. Rostami K, Kerckhaert J, Tiemessen R, von Blomberg BM, Meijer JW, Mulder CJ. Antiendomysium and antigliadin antibodies in untreated celiacs: disappointing in clinical practice. *Am J Gastroenterol* 1999;**94**:888-894.
3. Dickey W, McMillan SA, Hughes DF. Sensitivity of serum tissue transglutaminase antibodies for endomysial antibody positive and negative coeliac disease. *Scand J Gastroenterol* 2001;**36**:511-514.
4. Rubio-Tapia A, Kyle RA, Kaplan EL, et al. Increased prevalence and mortality in undiagnosed celiac disease. *Gastroenterology* 2009;**137**:88-93.
5. Lohi S, Mustalahti K, Kaukinen K, et al. Increasing prevalence of coeliac disease over time. *Aliment Pharmacol Ther* 2007;**26**:1217-1225.
6. Rubio-Tapia A, Hill ID, Kelly CP, Calderwood AH, Murray JA. ACG Clinical guidelines: diagnosis and management of celiac disease. *Am J Gastroenterol* 2013;**108**:656-676.
7. Motomura T, Shirabe K, Mano Y, et al. Neutrophil-lymphocyte ratio reflects hepatocellular carcinoma recurrence after liver transplantation via inflammatory microenvironment. *J Hepatol* 2013;**58**:58-64.
8. Halfdanarson TR, Litzow MR, Murray JA. Hematologic manifestations of celiac disease. *Blood* 2007;**109**:412-421.
9. See J, Murray JA. Gluten-free diet: the medical and nutrition management of celiac disease. *Nutr Clin Pract* 2006;**21**:1-15.
10. Marsh MN. Studies of intestinal lymphoid tissue. XI-The immunopathology of cell-mediated reactions in gluten sensitivity and other enteropathies. *Scanning Microsc* 1988;**2**:1663-1684.

Gastroenterology Department, Ankara Education and Research Hospital, Ankara, Turkey

Conflict of Interest: None

Correspondence to: Dr. Levent Filik, Ankara Education and Research Hospital, Gastroenterology Department, Ulucanlar, Altındağ, Ankara, TR 06230, Turkey, e-mail: leventfilik@yahoo.co.uk

Received 30 April 2014; accepted 25 May 2014

## Primary aldosteronism during long-term ulcerative colitis: a diagnostic challenge

**John K. Triantafyllidis, George Malgarinos, Achilles Rentis, Konstantinos Vagianos**

Iaso General Hospital, Athens, Greece

Primary aldosteronism (PA) represents an important cause of secondary hypertension. This situation is currently increasingly being diagnosed accounting for more than 10% of patients with secondary hypertension [1]. It is characterized by a variety of clinical features including cardiovascular, renal, and metabolic consequences, especially hypokalemia [2].

Ulcerative colitis (UC) often requires large doses of corticosteroids in order for the flare-ups to be settled. Hypertension or aggravation of already existing hypertension represents a well-known side effect related to the administration of corticosteroids. Significant losses of potassium could also appear during prolonged administration of corticosteroids for UC [3]. Thus, UC and PA may have overlapping manifestations.

So far, there is only one report referring to two cases of PA appearing during the course of Crohn's disease [4]. A coexistence of PA with UC has not yet been described.

The case described herein refers to a male patient, aged 49, who suffered from UC since the age of 33. The left-sided UC ran with remissions and exacerbations of mild to moderate severity once every 2 or 3 years. During the flare-ups he received short (4 to 8 weeks) courses of prednisone (30 mg/d orally in reduced doses) plus mesalamine (3.2 g/d orally; and 4 g/d in the form of enemas). Current maintenance treatment consisted of oral mesalamine 1.6 g/d and azathioprine 2 mg/kg/d.

During the last two years, he noticed a mild elevation in blood pressure, managed with oral diuretics and  $\beta$ -blockers (combination of atenolol and chlortalidon 50 and 12.5 mg, respectively). In September 2011, he complained of fatigue, myalgias, and mild epigastric pain. Hypokalemia was noticed, erroneously attributed to the use of diuretics. Despite the oral administration of potassium, hypokalemia persisted.

On admission, physical examination revealed hypertension (180/100 mmHg) and arrhythmia. Routine blood tests, including complete blood count, C-reactive protein, and liver and renal function tests, were normal. Erythrocyte sedimentation rate was 45 mm/1st h. Abdominal computed tomography, celiac and renal artery angiography, and cardiac Doppler ultrasound, revealed no significant findings. However, hormonal evaluation confirmed the diagnosis of PA due to adrenal hyperplasia. The values of aldosterone in both decubitus and upright position were significantly increased. Serum renin level and renin activity were abnormal (Table 1). Underlying bowel disease was quiescent.

**Table 1** Results of serum hormonal and urine (24 h) estimation

Parameter	Result	Normal values
Cortisol (µg/dL)	16.4	7.0-25.0 (morning)
	5.6	2.0-9.0 (evening)
ACTH (pg/mL)	33.7	7.0-64.0 (morning)
	18.2	5.0-30.0 (evening)
Renin (pg/mL)		
(decubitus position)	0.20	1.10-20.20
(upright position)	0.20	1.80-59.40
Renin activity (ng/mL/h)		
(decubitus position)	0.01	0.20-1.40
(upright position)	0.01	0.50-4.70
Aldosterone (ng/dL)		
(decubitus position)	45.3	1.0-16.0
(upright position)	66.3	4.0-31.0
Urine vanillylmandelic acid (mg/24h)	3.7	1.8-6.7
Urine metanephrines (µg/24h)	460.0	100.0-800.0
Urine free cortisol (µg/24h)	75.2	20.0-90.0
Urine aldosterone (µg/24h)	23.9	2.8-30.0
Urine hydroxyproline (mg/24h/m <sup>2</sup> )	13.8	6.0-22.0
Urine creatinine (mg/dL)	306.0	30-125
Urine Na <sup>+</sup> (mg/dL)	42.0	20-110
Urine K <sup>+</sup> (mg/dL)	76.8	12-62

ACTH, adrenocorticotrophic hormone

Based on the results of hormonal evaluation, the patient was started on eplerenone (Inspra 25 mg per day), which contains a blocker of aldosterone, binding at the mineralocorticoid receptor. The clinical results were quite favorable. Both blood pressure and serum potassium values returned to normal. He was asymptomatic on discharge, and remains so six months later, being under close clinical and laboratory surveillance. Bowel disease remains quiescent.

PA is now thought to be the commonest potentially curable and specifically treatable form of hypertension. The detection of this situation is of utmost importance because it allows a targeted treatment of hypertension to be applied, resulting in the prevention from aldosterone-induced tissue damage. Some pathophysiological events concerning the relationship between corticosteroids and adrenomedullary hormones must be stressed. Thus, glucocorticoids and adrenomedullary hormones may be influenced and may contribute to hypertension in PA. Moreover, cortisol and adrenomedullary hormones are different between PA subtypes and they might involve regulation of blood pressure [5]. It is of interest that aldosterone induces inflammation and oxidative stress that could be attenuated by mineralocorticoid receptor blockers (spironolactone) [6]. Further studies concerning the role of these hormones could be of value in patients with UC.

In our case, the appearance of PA during the course of UC is probably coincidental. However, we suggest that clinicians should bear in mind the possibility of the concurrent existence of the two situations when managing a patient with UC and hypertension, especially if hypokalemia is present.

## References

1. Douma S, Petidis K, Doumas M, et al. Prevalence of primary hyperaldosteronism in resistant hypertension: a retrospective observational study. *Lancet* 2008;**371**:1921-1926.
2. Sukor N. Primary aldosteronism: from bench to bedside. *Endocrine* 2012;**41**:31-39.
3. Triantafyllidis JK, Georgopoulos F, Merikas E. Current and emerging drugs for the treatment of inflammatory bowel disease. *Drug Des Devel Ther* 2011;**5**:185-210.
4. Astegiano M, Bresso F, Demarchi B, et al. Association between Crohn's disease and Conn's syndrome. A report of two cases. *Panminerva Med* 2005;**47**:61-64.
5. Ye F, Tang ZY, Wu JC, et al. Hormones other than aldosterone may contribute to hypertension in 3 different subtypes of primaryaldosteronism. *J Clin Hypertens (Greenwich)* 2013;**15**:264-269.
6. Samavat S, Ahmadpoor P, Samadian F. Aldosterone, hypertension, and beyond. *Iran J Kidney Dis* 2011;**5**:71-76.

IBD Unit, IASO General Hospital, Athens, Greece

Conflict of Interest: None

Correspondence to: Prof. John K. Triantafyllidis, Iera Odos 354, Haidari, 12461, Athens, Greece, Tel.: 6944432917, e-mail: jktrian@gmail.com

Received 3 May 2014; accepted 15 May 2014

## Development of Crohn's disease in husband and wife: the role of major psychological stress

**John K. Triantafyllidis, Charalambos Spyropoulos, Achilleas Rentis, Konstantinos Vagianos**

Iaso General Hospital, Athens, Greece

The influence of environmental factors on the development of Crohn's disease (CD) is well established. The development of CD in a married couple might be an example underlying the importance of environmental factors involved in the pathogenesis of the disease. So far, scattered cases of the appearance of CD during the period of marriage in both the husband and wife appeared in the literature [1-3].

We describe the case of a husband and wife who developed severe CD soon after they had divorced. Five years after their divorce, one of their children, a boy, now aged 20, developed CD of the terminal ileum. To our knowledge, no similar cases have been described so far.

The wife, aged 41, developed CD of the terminal ileum at the age of 35. The diagnosis was based on the histological picture of the surgical specimen of a right hemicolectomy performed on the basis of a catastrophic situation compatible with acute abdomen (bowel perforation) appearing as the first manifestation of the disease. The postoperative course was uneventful, and she was discharged from the hospital in good health. During the six-year follow up, she experienced at least two flare-ups of mild to moderate severity. Exacerbations were promptly settled with oral administration of steroids. She is under regular follow up in our unit, on maintenance treatment with azathioprine and immunomodulating diet (Modulen IBD).

Her husband, now aged 43, developed ileocecal CD at the age of 36. The course of the disease was quite severe requiring the use of anti-tumor necrosis factor- $\alpha$  agent (adalimumab) at a dose of 160 mg at week 0, 80 mg at week 2, and 40 mg every 2 weeks, thereafter. Under this treatment the disease is running with a mild profile.

In both patients, CD was diagnosed 12 and 20 months respectively after their divorce, while they were not cohabitants. Both patients were smokers for many years. The female patient gave up smoking soon after the operation. However, her husband continues to be a smoker.

Their marriage lasted for 13 years. During this period, they acquired two children (a boy and a girl) aged now 20 and 17 years, respectively. Six months ago, their son (aged 20) developed CD of the terminal ileum. The diagnosis was based on the compatible clinical picture, and the findings of ileoscopy. Histology of the ileal mucosa confirmed the diagnosis of CD. The patient responded well to oral administration of budesonide (9 mg per day). He is now under maintenance treatment with oral budesonide, and we are planning to continue this kind of treatment for at least one year.

The development of CD after marriage in both the husband and wife seems to be a rare event, although the frequency of inflammatory bowel disease (IBD) in children could be higher if both parents had already developed IBD at the time of conception [4]. There is increasing evidence that psychological stress is linked with and can adversely affect the course of IBD [5]. Stress has both central and peripheral effects, promoting anxiety and depression. Moreover, stress can exacerbate symptoms of CD by lowering visceral pain thresholds, thus increasing the sense of it and decreasing mucosal barrier function [5]. It is of interest that our patients strongly emphasized the fact that their divorce acted as a strong and persistent psychological stress being a causative factor for the development of IBD. However, most gastroenterologists actually dispute the role of psychological disorders in CD, and a number of conflicting opinions are expressed in the literature based on the fact that prospective investigations of life events as causative factors for IBD are relatively few.

In conclusion, we strongly believe that severe psychological stress (due to the divorce) triggered the appearance of CD in this couple, acting as an environmental risk factor.

## References

1. Bustamante M, Devesa F, Pareja V, Ferrando MJ, Ortuño J, Borghol A. Development of inflammatory bowel disease in a husband and wife. *Gastroenterol Hepatol* 2002;**25**:244-246.
2. Comes MC, Gower-Rousseau C, Colombel JF, et al. Inflammatory bowel disease in married couples: 10 cases in Nord Pas de Calais region of France and Liège county of Belgium. *Gut* 1994;**35**:1316-1318.
3. Laharie D, Debeugny S, Peeters M, et al. Inflammatory bowel disease in spouses and their offspring. *Gastroenterology* 2001;**120**:816-819.
4. Bennett RA, Rubin PH, Present DH. Frequency of inflammatory bowel disease in offspring of couples both presenting with inflammatory bowel disease. *Gastroenterology* 1991;**100**:1638-1643.
5. Triantafyllidis JK, Merikas E, Gikas A. Psychological factors and stress in inflammatory bowel disease. *Expert Rev Gastroenterol Hepatol* 2013;**7**:225-238.

---

Inflammatory Bowel Disease Unit, "IASO General" Hospital, Athens, Greece

Conflict of Interest: None

Correspondence to: Prof. John K. Triantafyllidis, Iera Odos 354, Haidari, 12461, Athens, Greece, Tel.: 6944432917, e-mail: jktrian@gmail.com

Received 3 May 2014; accepted 15 May 2014

## Large fundal varices: to glue or not to glue?

**Syed Adnan Mohiuddin<sup>a</sup>,  
Manik Sharma<sup>a</sup>, Ragesh Babu Thandassery<sup>a</sup>,  
Muneera Al Mohannadi<sup>a</sup>, Rafie Yakoob<sup>a</sup>,  
Ahmed Muzrakchi<sup>b</sup>, Saad Rashid Al Kaabi<sup>a</sup>**

Hamad General Hospital, Doha, Qatar

A 45-year-old man was admitted with a one-day history of hematemesis and melena. He was had been followed up for chronic hepatitis C-related cirrhosis and had been admitted previously for management of spontaneous bacterial peritonitis. He was hemodynamically stable and general physical examination was noncontributory except for mild icterus. Investigations revealed hemoglobin 9.6 g/L, platelet count 66,000/mm<sup>3</sup>, INR 1.6, serum albumin 26 g/L, alanine transaminase 132 IU/mL, aspartate transaminase 141 IU/mL and serum bilirubin 53 mmol/L (normal <24). Abdominal ultrasound and doppler scan revealed cirrhotic liver, splenomegaly and patent hepatic and portal veins. Urgent gastroscopy revealed a large fundal varix (IGV1) with stigmata of recent bleed. He was planned for glue injection. As we injected 1 mL of glue (0.5 mL n-butyl cyanoacrylate mixed with 0.5 mL lipiodol) into the fundal varix, there was active spurting (Fig. 1). The patient developed significant bleeding and became hypotensive. He was stabilized with intravenous fluids, blood transfusion and terlipressin. An attempt was

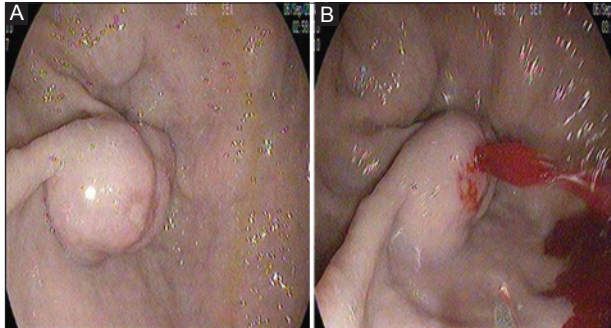
made to radiologically embolize the gastrosplenic shunt by Balloon Retrograde Transvenous Obliteration (BRTO). A large gastrosplenic shunt was identified and embolization with absolute alcohol was attempted after balloon occlusion of the gastrosplenic shunt (Fig. 2B). Four hours later a repeat venography revealed rupture of the balloon with minimal obliteration of collaterals. As the patient was a poor risk candidate for surgical devascularization, a second attempt was made endoscopically and 3 mL of glue (1.5 mL n-butyl cyanoacrylate mixed with 1.5 mL lipiodol) was injected. We confirmed hardening of varix with catheter probe and the procedure was uneventful (Fig. 2B). Post procedure, the patient remained stable and was discharged a week later. He is asymptomatic on follow up after 3 months.

Gastric varices account for about one-fifth of cases of variceal bleed and can result in severe bleeding with high mortality [1]. Treatment options for fundal variceal bleeding include endoscopic injection therapy with n-butyl cyanoacrylate, radiological measures (BRTO and transjugular intrahepatic portosystemic shunt) and surgical devascularization [1,2]. Recently, use of endoscopic ultrasound-guided therapy with coils has also been advocated [3]. Various studies have recommended different volumes of glue, varying from 0.5-4 mL of glue per session with each injection consisting of not more than one mL (glue and lipiodol combined) [1-4]. In the index case, during the first session of glue injection, immediately after injection, the patient developed significant bleeding. Unfortunately, BRTO also failed in the index case. In a recent series of 41 patients who underwent BRTO, rupture of the balloon leading to technical failure of the

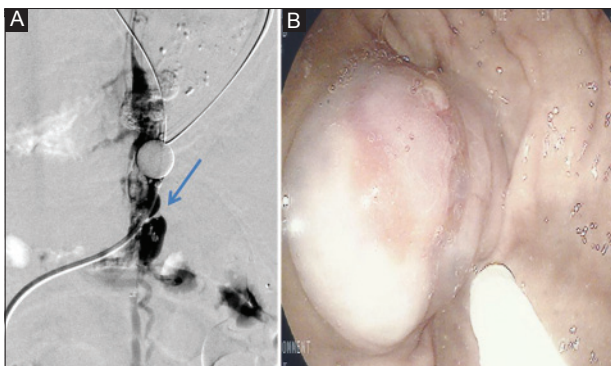
procedure has been described in about 14% of patient [5]. As a salvage measure we injected a relatively large volume of glue (three times the usual dose per injection) to control the bleeding and this was successful. We wish to emphasize that, even in cases where initial endoscopic and radiological measures had failed, a repeat endoscopic glue injection can be attempted, especially in a large fundal varix, which can be lifesaving. Larger volumes per injection (up to 1.5 mL of glue) can result in complete obliteration of fundal varices without any significant risk of embolization.

## References

1. Garcia-Tsao G, Sanyal AJ, Grace ND, Carey W; Practice Guidelines Committee of the American Association for the Study of Liver Diseases; Practice Parameters Committee of the American College of Gastroenterology. Prevention and management of gastroesophageal varices and variceal hemorrhage in cirrhosis. *Hepatology* 2007;**46**:922-938.
2. de Franchis R, Baveno V. Faculty. Revising consensus in portal hypertension: report of the Baveno V consensus workshop on methodology of diagnosis and therapy in portal hypertension. *J Hepatol* 2010;**53**:762-768.
3. Romero-Castro R, Ellrichmann M, Ortiz-Moyano C, Subtil-Inigo JC. EUS-guided coil versus cyanoacrylate therapy for the treatment of gastric varices: a multicenter study (with videos). *Gastrointest Endosc* 2013;**78**:711-721.
4. Seewald S, Ang TL, Imazu H, et al. A standard injection technique and regimen ensures success and safety of N-butyl-2-cyanoacrylate injection for the treatment of gastric fundal varices. *Gastrointest Endosc* 2008;**68**:447-454.
5. Saad WE, Nicholson D, Lippert A. Balloon-occlusion catheter rupture during balloon-occluded retrograde transvenous obliteration of gastric varices utilizing sodium tetradecyl sulfate: incidence and consequences. *Vasc Endovascular Surg* 2012;**46**:664-670.



**Figure 1** (A) Fundal varix with stigmata of recent bleeding (B) Active bleeding after glue injection



**Figure 2** Venogram (A) showing large gastrosplenic shunt (arrow) and (B) endoscopic appearance of varix after successful glue injection

Departments of <sup>a</sup>Gastroenterology (Syed Adnan Mohiuddin, Manik Sharma, Ragesh Babu Thandassery, Muneera Al Mohannadi, Rafie Yakoob, Saad Rashid Al Kaabi); <sup>b</sup>Radiodiagnosis (Ahmed Muzrakchi), Hamad General Hospital, Doha, Qatar

Conflict of Interest: None

Correspondence to: Ragesh Babu Thandassery, Endoscopy Unit, 2 South 2, Hamad General Hospital, Hamad Medical Corporation, Doha, Qatar, e-mail: doc.ragesh@gmail.com

Received 11 March 2014; accepted 18 March 2014

## Tuberculous peritonitis after treatment for chronic hepatitis C

**Evangelos Cholongitas, Theodora Nakouti, Evangelos Akriviadis**

Medical School of Aristotle University, Hippocraton General Hospital of Thessaloniki, Greece

A 71-year-old man was admitted to our Department with weakness, low-grade fever, and weight loss (approximately 10 kg) during the last 3 months. The patient had received antiviral therapy for chronic hepatitis C in another clinic (pegylated interferon-2a 180 mcg/week plus ribavirin 1000 mg/day) for 4 months, but this regimen had been discontinued 2 months before his admission due to the development of severe leukopenia (neutrophil count 450/mm<sup>3</sup>). On admission, the patient was febrile (37.5°C), with abdominal distension and lower limb edema. Admission laboratory findings included: hematocrit: 36.4%, white blood cells: 3.1x10<sup>3</sup>/μL (neutrophils: 61%, lymphocytes: 21%), platelet count: 110,000/μL, albumin: 3.0 g/dL, alanine aminotransferase: 104 IU/L [upper limit of normal (ULN)<40], alkaline phosphatase: 270 IU/L (ULN<120), γ-glutamyl transferase: 386 IU/L (ULN<38), bilirubin: 4.6 mg/dL (direct: 2.95 mg/dL), INR: 1.2, and C-reactive protein (CRP): 12 mg/L. Abdominal computed tomography showed cirrhotic liver with splenomegaly and ascites without other abnormal findings, and cardiac ultrasound was normal. Analysis of ascitic fluid revealed: leukocytes: 800/mm<sup>3</sup> (neutrophils: 500/mm<sup>3</sup>), serum-ascites albumin gradient (SAAG) >1.1, protein: 2.6 g/dL. With the diagnosis of spontaneous bacterial peritonitis (SBP), the patient received ceftriaxone 2 g intravenously/day, but three days later, new paracentesis of ascitic fluid showed poor response to antibiotic therapy (leukocytes: 1000/mm<sup>3</sup>, neutrophils: 800/mm<sup>3</sup>). At this time, ceftriaxone was changed to imipenem 2 g/day intravenously. After 2 days, new paracentesis revealed that the number of neutrophils in ascitic fluid remained unchanged and the patient was still febrile. All cultures of ascitic fluid were negative for the common bacteria. Further evaluation of ascites was decided. Although tuberculin skin test and Ziehl-Neelsen staining of the ascitic fluid were both negative, amplified *Mycobacterium tuberculosis* direct test (Gen-Probe) of the fluid was intensively positive [10<sup>6</sup> relative light units (RLU) (>500,000 RLU indicates active infection from *Mycobacterium tuberculosis*)]. Computed tomography of the chest showed no indication for pulmonary tuberculosis. With the diagnosis of peritoneal tuberculosis (TBP), the patient was commenced on isoniazid 300 mg, rifabacin 600mg and ethambutol 2 gr per day for 2 months and continued with isoniazid, and rifampicin for another 4 months. He showed good response with normal ranges of CRP one month after initiation of anti-tuberculosis therapy. The patient was followed up in the clinic, and, fortunately, without adverse events during anti-tuberculosis therapy.

Patients with cirrhosis are considered at higher risk for development of TBP [1]. Analysis of ascitic fluid in TBP usually reveals lymphocytic ascites with SAAG <1.1 g/dL [2]. However, similar to our case, patients with concomitant cirrhosis may have neutrophil predominance and SAAG >1.1 g/dL in up to 40% and 71% of cases, respectively [2]. In our patient, we were able to establish the diagnosis of TBP based on Gen-Probe, which is a quick, specific, but expensive test for the activity of tuberculosis.

In the literature, few patients with pulmonary tuberculosis during or after discontinuation of antiviral therapy for hepatitis C virus (HCV) infection have been described [3]. Although tuberculosis has been associated

with the development of interferon-induced neutropenia/lymphopenia, recent studies have found that other factors, such as age over 50 years and diabetes mellitus, are significantly associated with the occurrence of infections in patients under anti-HCV therapy (our patient was older than 50 years) [4,5]. To our knowledge, this is the first case report of TBP associated with antiviral therapy against HCV infection.

## References

1. Guirat A, Koubaa M, Mzali R, et al. Peritoneal tuberculosis. *Clin Res Hepatol Gastroenterol* 2011;**35**:60-69.
2. Sanai FM, Bzezi KI. Systematic Review: tuberculous peritonitis - presenting features, diagnostic strategies and treatment. *Aliment Pharmacol Ther* 2005;**22**:685-700.
3. Sabbatani S, Manfredi R, Marinacci G, et al. Reactivation of severe, acute pulmonary tuberculosis during treatment with pegylated interferon-alpha and ribavirin for chronic HCV hepatitis. *Scand J Infect Dis* 2006;**38**:205-208.
4. Roomer R, Hansen BE, Janssen H, de Knecht RJ. Risk factors for infection during treatment with peginterferon alfa and ribavirin for chronic hepatitis C. *Hepatology* 2010;**52**:1225-1231.
5. Striki A, Manolakopoulos S, Deutsch M, et al. Cirrhosis but not neutropenia is associated with the development of infection in patients with chronic hepatitis C undergoing treatment with pegylated interferon-alpha and ribavirin. *J Viral Hepat* 2014;**21**:624-632.

4<sup>th</sup> Department of Internal Medicine, Medical School of Aristotle University, Hippokraton General Hospital of Thessaloniki, Greece

Conflict of Interest: None

Correspondence to: Evangelos Cholongitas, Assistant Professor of Internal Medicine, 4<sup>th</sup> Department of Internal Medicine, Medical School of Aristotle University, Hippokraton General Hospital of Thessaloniki, 49, Konstantinopoleos Street, 546 42 Thessaloniki, Greece, Tel.: +30 2310 892110, Fax: +30 2310 855566, e-mail: cholongitas@yahoo.gr

Received 25 April 2014; accepted 29 April 2014

## Right-sided pancreaticopleural fistula

**Larisa Vasilieva<sup>a</sup>, Sofia Adamidi<sup>a</sup>, Naso Kittou<sup>a</sup>, Konstantinos Papiris<sup>b</sup>, Andreas Romanos<sup>b</sup>, Spyros P. Dourakis<sup>a</sup>**

Athens University Medical School; Hippokraton Hospital, Athens, Greece

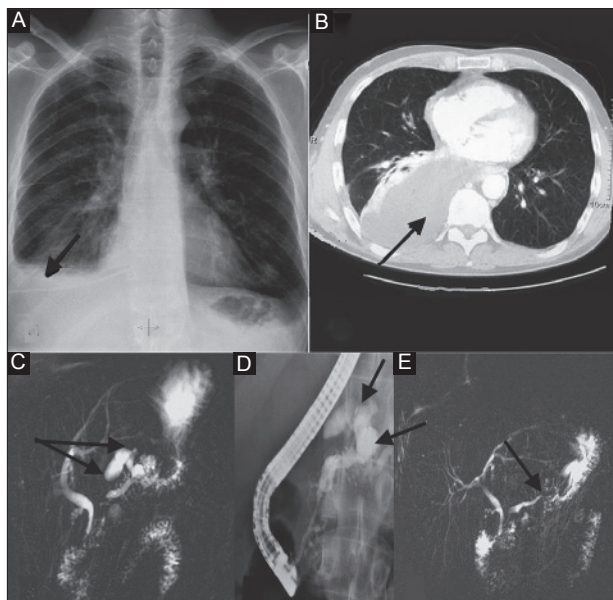
Pancreaticopleural fistula (PPF) is a rare complication of chronic pancreatitis due to communication of the pleural cavity (usually the left) with the pancreatic duct [1-5]. In contrast to fistulization, pleural effusion associated with acute



pancreatitis is usually small, left-sided and described as either chemically-induced, sympathetic in nature, or due to the diffusion of pancreatic enzymes through diaphragmatic lymphatics.

We report the case of a 47-year-old alcoholic male with a history of chronic pancreatitis, who was admitted because of non-productive cough, dyspnea and orthopnea. Chest x-ray examination (Fig. 1A) and chest computed tomography (CT) revealed a large right pleural effusion (Fig. 1B) and flocking pancreatic calcifications. A chest drain was inserted and 3.8 L of exudative polymorphonuclear fluid with amylase 34455 U/mL were drained. Magnetic resonance cholangiopancreatography (MRCP) examination (Fig. 1C) showed chronic pancreatitis and PPF, and endoscopic retrograde cholangiopancreatography (ERCP) imaging revealed a pancreatic duct with characteristics of chronic pancreatitis and upper part communication with the pleural cavity (Fig. 1D). Initially, we performed pancreatic sphincterotomy. Guide wire catheterization with subsequent balloon cleansing produced secretions. Finally, after a pig tail stent was inserted and somatostatin was prescribed, the health of the patient improved. A second MRCP showed partial closure of the fistula (Fig. 1E) and undetectable amylase in the pleural effusion. The patient is in good health 18 months after endoscopic treatment. No pathological findings were detected in a recent chest CT. A second ERCP was not needed since the pancreatic stent was automatically rejected.

Therapeutic treatment of PPF consists of administration of somatostatin [1] and endoscopic drainage with pancreatic sphincterotomy and stenting of the pancreatic duct [1]. However, this approach is not always possible and the patients are subject to surgical treatment [6].



**Figure 1** (A) A chest x-ray examination showing a right pleural effusion. (B) A chest computed tomography showing a right pleural effusion. (C) Communication of the pancreatic duct with the pleural cavity on magnetic resonance cholangiopancreatography (MRCP) imaging. (D) The pleuropancreatic fistula on endoscopic retrograde cholangiopancreatography imaging. (E) The pleuropancreatic fistula partially closed on MRCP imaging

In conclusion, this case reminds us that PPF is associated rarely with right pleuritis and endoscopic treatment with somatostatin infusion can be effective.

## References

1. Roberts KJ, Sheridan M, Morris-Stiff G, Smith AM. Pancreaticopleural fistula: etiology, treatment and long-term follow-up. *Hepatobiliary Pancreat Dis Int* 2012;**11**:215-219.
2. King JC, Reber HA, Shiraga S, Hines OJ. Pancreatic-pleural fistula is best managed by early operative intervention. *Surgery* 2010;**147**:154-159.
3. Keyashian K, Buxbaum J. Pleural effusion caused by a pancreatic pleural fistula. *Gastrointest Endosc* 2012;**76**:422-424.
4. Cooper ST, Malick J, McGrath K, Slivka A, Sanders MK. EUS-guided rendezvous for the treatment of pancreaticopleural fistula in a patient with chronic pancreatitis and pancreas pseudodivisum. *Gastrointest Endosc* 2010;**71**:652-654.
5. Halttunen J, Weckman L, Kemppainen E, Kylänpää ML. The endoscopic management of pancreatic fistulas. *Surg Endosc* 2005;**19**:559-562.
6. Sonoda S, Taniguchi M, Sato T, *et al.* Bilateral pleural fluid caused by a pancreaticopleural fistula requiring surgical treatment. *Intern Med* 2012;**51**:2655-2661.

<sup>a</sup>2<sup>nd</sup> Department of Internal Medicine, Athens University Medical School (Larisa Vasilieva, Sofia Adamidi, Naso Kittou, Spyros P. Dourakis); <sup>b</sup>Endoscopic Surgery Unit, Hippokraton Hospital (Konstantinos Papiris, Andreas Romanos), Athens, Greece

Conflict of Interest: None

Correspondence to: Larisa E. Vasilieva, MD, 2<sup>nd</sup> Dept of Internal Medicine, Athens University Medical School, 15562 Themistokleous 39 Holargos Athens, Greece, Tel.: +30 210 6519430, e-mail: larisatheo@yahoo.gr

Received 1 April 2014; accepted 6 April 2014

## Extensive cervical, thoracic, and abdominal wall emphysema and pneumomediastinum following ERCP: a rare scenario

**Anil K John, Ragesh Babu Thandassery, Syed Hammad Alam, Saad Rashid Al Kaabi**

Hamad General Hospital, Doha, Qatar

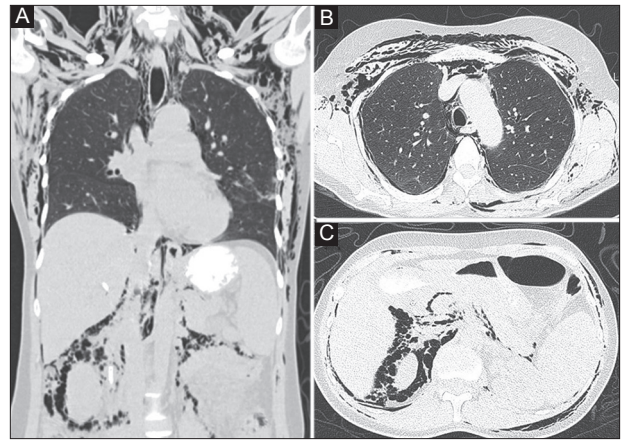
A 42-year-old woman underwent endoscopic retrograde cholangiopancreatography (ERCP) for cholangitis due to choledocholithiasis and biliary sphincterotomy with double pigtail biliary stent placement was performed. Four-six hours after the procedure, she developed subcutaneous swelling over the neck with crepitus over it. In the next

few hours the swelling extended all over the abdomen and chest. Abdominal computed tomography (CT) scan showed extensive subcutaneous emphysema in abdomen, thorax, neck, pneumoretroperitoneum and pneumomediastinum (Fig. 1). There was no evidence of contrast leak on CT indicative of overt bowel perforation. She did not have any other symptoms and was managed with intravenous antibiotics and fluids. The subcutaneous emphysema started to resolve in another 48 h. Patient was discharged after resolution of emphysema and underwent repeat ERCP with stone extraction 4 weeks later. She is asymptomatic on follow up.

Duodenal perforation leads to retroperitoneal air collection, which tracks into thorax and subsequently into subcutaneous tissues. It is believed that congenital or acquired pores in the diaphragm allow air to move between the abdominal and thoracic cavity [1]. Another hypothesis is that trauma to the duodenal wall by the endoscope allows air to enter the mucosa and extend along the perineural and perivascular sheaths to enter the mediastinum [2]. The visceral space of the deep fascia in the neck surrounds the trachea and esophagus and is contiguous with the diaphragmatic and/or esophageal hiatus and major airways of the thorax [3]. This establishes free communication between the retroperitoneum, mediastinum, and subcutaneous tissues of the neck. Subcutaneous emphysema emerges in the neck and extends to the chest wall through the endothoracic fascia and then to abdomen through transversalis fascia.

ERCP-related perforations are classified by 2 systems. Howard *et al* proposed a 3-group classification system based on the mechanism of ERCP-related perforation (group 1: guidewire related; group 2: periampullary; and group 3: duodenal perforations) [4]. Alternatively, Stapfer *et al* classified perforations into 4 types based on severity and anatomical location (type I: lateral or medial duodenal wall perforations (Howard group III); type II: peri-Vaterian injury (Howard group II); type III: bile or pancreatic duct injury (comparable to Howard group I since the majority of these perforations are caused by guidewire handling); and type IV: presence of retroperitoneal air alone [5].

Treatment of ERCP-related perforations depends on the type of injury and the patient's clinical status. All Stapfer type I perforations require immediate surgery [4,5]. The type of surgery depends on the size of perforation (oversewing with omental patch, gastrojejunostomy, tube duodenostomy, and extensive debridement). The approach to management of type II perforations is variable. Most tend to seal spontaneously by 48-72 hours, but 10-40% of patients may require surgical repair [6,7]. Type III perforations usually close spontaneously. They can be conservatively managed with placement of a biliary stent [4]. Type IV perforations result in retroperitoneal air leak. They may not have an overt transmural perforation as in the index case and can



**Figure 1** Coronal multi planar reconstruction (A) and axial computed tomography images (B,C) of chest and abdomen (lung window) show extensive pneumoretroperitoneum, pneumomediastinum, neck, thoracic, and abdominal wall subcutaneous emphysema

be managed non-operatively. There are only few reports of such extensive subcutaneous emphysema subsequent to ERCP [2].

## References

1. Kirschner PA. Porous diaphragm syndromes. *Chest Surg Clin N Am* 1998;**8**:449-472.
2. Jaiswal SK, Sreevastava DK, Datta R, Lamba NS. Unusual occurrence of massive subcutaneous emphysema during ERCP under general anaesthesia. *Indian J Anaesth* 2013;**57**:615-617.
3. Maunder RJ, Pierson DJ, Hudson LD. Subcutaneous and mediastinal emphysema. Pathophysiology, diagnosis, and management. *Arch Intern Med* 1984;**144**:1447-1453.
4. Howard TJ, Tan T, Lehman GA, et al. Classification and management of perforations complicating endoscopic sphincterotomy. *Surgery* 1999;**126**:658-663.
5. Stapfer M, Selby RR, Stain SC, et al. Management of duodenal perforation after endoscopic retrograde cholangiopancreatography and sphincterotomy. *Ann Surg* 2000;**232**:191-198.
6. Makni A, Chebbi F, Ben Safta Z. Pneumoretroperitoneum, bilateral pneumothorax and emphysema following endoscopic biliary sphincterotomy. *Acta Chir Belg* 2012;**112**:307-309.
7. Enns R, Eloubeidi MA, Mergener K, et al. ERCP-related perforations: risk factors and management. *Endoscopy* 2002;**34**:293-298.

Department of Gastroenterology, Hamad General Hospital, Doha, Qatar

Conflict of Interest: None

Correspondence to: Ragesh Babu Thandassery, MD, DM, 2 South 2, Endoscopy unit, Hamad General Hospital, Hamad Medical Corporation, Doha, Qatar, Tel.: +974 4439 2532, e-mail: doc.ragesh@gmail.com

Received 4 April 2014; accepted 14 April 2014