

## An unusual duodenal cloverleaf

**Antonio Tursi**

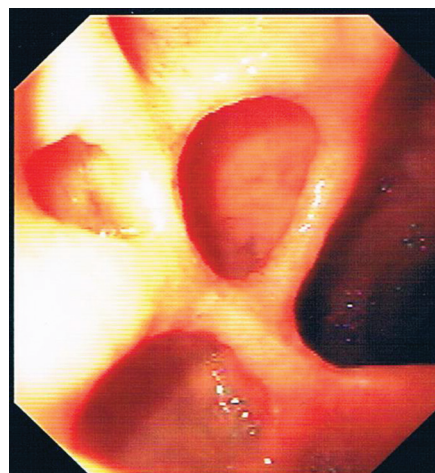
ASL BAT, Andria (BT), Italy

A 69-year-old female underwent an esophago-astroduodenoscopy (EGD) due to a 6-month history of recurrent episode of vomiting. She had been suffering from rheumatoid arthritis for 20 years, and was under intermittent treatment with non-steroid anti-inflammatory drugs (NSAIDs).

On endoscopic examination, esophagus was normal, and stomach showed mild antral hyperemia. On the anterior wall of the duodenal bulb, four pseudo-diverticula were found designing a kind of cloverleaf, with long white scars on the stalk of this pattern (Fig. 1). Rapid urease test was positive a diagnosis of complicated scars of healed *Helicobacter pylori* (*H. pylori*)-positive duodenal ulcer was posed, and the patient was successfully treated with *H. pylori* eradication regimen.

*H. pylori* infection is the most important cause of duodenal ulcer. Although its prevalence and incidence is currently decreasing in the western world, it is still able to cause complications.

Both *H. pylori* infection and NSAID use are currently identified as independent risk factors for the development of peptic ulcer disease and associated bleeding. Current guidelines advise *H. pylori* eradication before starting long-term NSAID treatment, whilst *H. pylori* eradication in those who are already long-term users is of no clear benefit. Treatment with



**Figure 1** Four pseudo-diverticula located on the duodenal anterior wall and designing a kind of cloverleaf with long white scars on the stalk of this pattern

maintenance proton pump inhibitors (PPIs) for preventing NSAID-associated ulcers is advised too [1].

It is therefore hypothesized that the “duodenal cloverleaf” discovered in our patient may be the outcome of a complicated duodenal ulcer, associated with chronic *H. pylori* infection and worsened by long-term NSAID use without concurrent PPI gastroprotection.

Servizio di Gastroenterologia Territoriale, ASL BAT, Andria, BT, Italy

Conflict of Interest: None

Correspondence to: Dr. Antonio Tursi, MD, Servizio di Gastroenterologia Territoriale DSS n°4, ASL BAT, Via Torino 49, 76123 Andria (BT), Italy, Tel.: +39 0883 551094, Fax: + 39 0883 1978210, e-mail: antotursi@tiscali.it

Received 19 April 2014; accepted 22 April 2014

### Reference

1. Malfertheiner P, Megraud F, O'Morain CA et al. European Helicobacter Study Group. Management of *Helicobacter pylori* infection-the Maastricht IV/Florence Consensus Report. *Gut* 2012;**61**:646-664.