

Ampullary tumor presenting as acute cholangitis

Sunil Dadhich, Amitava Goswami, Narendra Bhargava

Dr. Sampurnanand Medical College, Jodhpur, Rajasthan, India

We herein present a 78-year-old man with a 3-day history of jaundice and fever with chills. His past medical history was unremarkable except for smoking. He presented clinically with jaundice, anemia, abdominal scratch marks and hypotension. Laboratory investigation revealed microcytic hypochromic anemia, leukocytosis and an elevated serum creatinine (1.8 mg/dL). Liver function tests were deranged with hyperbilirubinemia and raised alkaline phosphatase [total bilirubin 11.4 mg/dL (0.1-1.1); direct bilirubin 8.6 mg/dL (0.1-0.4); alkaline phosphatase 874 IU/L (30-140)]. All viral serology was normal and CA 19-9 was 156 U/mL (0-37). Abdominal ultrasonography showed a dilated common bile duct (10 mm) with abrupt distal tapering. MRI/MRCP were done which showed a mass lesion at ampulla with a proximally dilated common bile duct. Side viewing endoscopy for management of acute cholangitis was done (Fig. 1A). However a choledochoscopy with an ultrathin neonatal endoscope revealed a calculus and ductal clearance was done with balloon sweep (Fig. 1B). Histological examination of the biopsy was suggestive of ampullary adenocarcinoma.

Acute ascending cholangitis may be an initial presentation of ampullary tumor and requires urgent biliary decompression with endoscopic biliary drainage [1]. Elderly patients with cholangitis also have a higher incidence of coexisting medical problems like cardiovascular, pulmonary, neurological and other systemic diseases. Due to the high incidence of severe cholangitis, hypotension, altered sensorium and associated other concurrent systemic diseases, the management of acute cholangitis in the elderly becomes difficult [2]. Biliopancreatic malignancy constitutes a common cause of biliary obstruction in elderly patients compared to benign diseases in younger patients. However a commoner etiology of acute suppurative cholangitis may be missed without choledochoscopy.

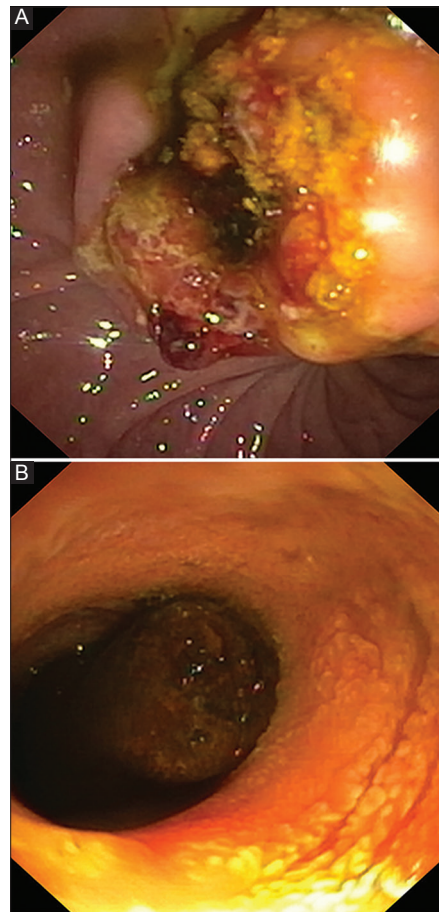


Figure 1 (A) Ampullary tumor. (B) Choledochoscopy showing solitary choledocholithiasis

Department of Gastroenterology, Dr. Sampurnanand Medical College, Jodhpur, India

Conflict of Interest: None

Correspondence to: Amitava Goswami, Department of Gastroenterology, Dr Sampurnanand Medical College, Jodhpur 342001, Rajasthan, India, Tel.: +91 876 994 7345, e-mail: amitavagoswami77@gmail.com

Received 28 February 2014; accepted 4 March 2014

References

1. Kumar R, Sharma BC, Singh J, Sarin SK. Endoscopic biliary drainage for severe acute cholangitis in biliary obstruction as a result of malignant and benign diseases. *J Gastroenterol Hepatol* 2004;**19**:994-997.
2. Sugiyama M, Atomi Y. Treatment of acute cholangitis due to choledocholithiasis in elderly and younger patients. *Arch Surg* 1997;**132**:1129-1133.