

Application of confocal laser endomicroscopy in the diagnosis and management of Barrett's esophagus

Cadman L. Leggett, Emmanuel C. Gorospe

Mayo Clinic, Rochester, Minnesota, USA

Abstract

Confocal laser endomicroscopy is an advanced endoscopic imaging modality that can be used for the diagnosis of early mucosal dysplasia in various gastrointestinal conditions. It provides histology-like images at 1000-fold magnification. The technology offers potential advantages in the diagnosis of Barrett's esophagus and early esophageal cancer due to the low yield of the current practice of surveillance endoscopy with biopsies. Confocal laser endomicroscopy has the potential to eliminate the need for biopsy, establish diagnosis and facilitate application of endoscopic therapy during the time of actual endoscopy. There are several studies that have demonstrated reasonable diagnostic accuracy in patients undergoing surveillance for Barrett's esophagus from tertiary academic medical centers. However, the application of confocal laser endomicroscopy in routine clinical endoscopy is still in the process of refinement. Its role in the diagnosis and treatment of Barrett's-associated dysplasia will continue to evolve with improvement in technology, criteria for diagnosis and experience among endoscopists in interpreting confocal imaging.

Keywords Confocal laser endomicroscopy, confocal endomicroscopy, Barrett's esophagus, esophageal cancer, mucosal dysplasia, fluorescein, 2-NBDG

Ann Gastroenterol 2014; 27 (3): 193-199

Introduction

Barrett's esophagus (BE) results from the metaplastic transformation of the esophageal mucosa in response to chronic gastroesophageal reflux and inflammation [1]. This condition carries the potential to develop dysplasia that may progress to esophageal adenocarcinoma. Surveillance of BE is achieved by examining the esophageal mucosa under white-light endoscopy and acquiring biopsies at set intervals along the BE segment. This approach is limited by sampling error given that dysplasia is not distributed uniformly throughout the BE segment [2].

Advanced imaging techniques including narrow band imaging, optical coherence tomography, and confocal laser endomicroscopy (CLE) allow for real-time evaluation of the esophageal mucosa. In particular, CLE is capable of generating high-resolution microscopy images that approximate histologic

evaluation. These *in vivo* images could almost qualify as virtual biopsies that can facilitate diagnosis at the point-of-care setting instead of the need to wait for specimen processing and histopathologic interpretation. Although the current state of CLE application in BE is not yet firmly established to replace endoscopic biopsies, a study by Dunbar *et al* demonstrated improvement in the diagnostic yield of surveillance endoscopy accompanied by a decreased number of random biopsies [3].

The aim of this review is to summarize the current literature on the application of this novel imaging modality and its utility in the diagnosis and management of BE. The success of CLE will depend on its acceptability among endoscopists, its ease of use, interpretability of confocal imaging and improvement of diagnostic accuracy in detecting dysplasia in BE in an efficient manner that is suitable for routine endoscopic examination.

CLE principles and platforms

The principles of confocal laser endomicroscopy are derived from conventional confocal microscopy systems. The concept of confocal microscopy has been in use since the 1960's for the purposes of acquiring optical sections of tissue specimens [4]. Coherent light emitted by a laser (argon blue, 488 nm) passes through a pinhole aperture and is focused at a point of interest. Reflected light from this point is focused on a second pinhole aperture positioned in front of a photodetector.

Barrett's Esophagus Unit, Department of Gastroenterology and Hepatology, Mayo Clinic, Rochester, Minnesota, USA

Conflict of Interest: None

Correspondence to: Cadman L. Leggett, MD, Department of Gastroenterology and Hepatology, Mayo Clinic, 200 First Street SW, Rochester, Minnesota, 55905 USA, Fax: +507 538 5820, e-mail: leggett.cadman@mayo.edu

Received 27 February 2014; accepted 21 April 2014

This setup allows for high-resolution imaging of a discrete point by rejecting light that is out of focus. A grayscale image is generated by scanning the focused beam over a plane of interest. This facilitates creation of different optical sections representing different planes within the tissue. CLE can achieve a magnification of a 1000-fold with axial and lateral resolutions in the micrometer range.

There are two commercially available CLE systems used in BE imaging: endoscope-based (eCLE, Pentax Medical Corporation, Tokyo, Japan) and probe-based (pCLE, Mauna Kea Technologies, Paris, France). The specifications of each system are summarized in Table 1. The eCLE system (EG-3870CILK) is a standard-definition white light gastroscope with a confocal imaging aperture and instrument channel (Fig. 1). Endomicroscopy images are acquired by placing the imaging aperture directly in contact with the esophageal mucosa. Controls on the endoscope handle allow for adjustment over imaging direction and depth. The image output is displayed on a screen and can be viewed alongside the standard-definition endoscopy screen. The endoscopic field of view is 475 by 475 μm . Imaging depth can be varied from surface to 250 μm deep. Image resolution is dependent on acquisition rate and can be changed from 1.6 images/sec (1024 \times 512 pixels) to 0.8 images/sec (1024 \times 1024 pixels).

The pCLE system uses endomicroscopy mini-probes that can be inserted through the working channel of a standard

endoscope (Fig. 2). This system and its processor are separate from the endoscopic imaging system and stands in its own console. Images are acquired by placing the probe in contact with the esophageal mucosa. A rapid image acquisition rate at 12 images/sec generates videos of the esophageal mucosa with output to a dedicated monitor. The lateral resolution and field of view vary depending on the mini-probe used with higher resolution probes having narrower fields of view. Two GastroFlex pCLE mini-probes are available for upper gastrointestinal endoscopy: 1) the standard mini-probe with a field of view of 600 μm , lateral resolution of 3.5 μm and confocal depth of 70-130 μm ; and 2) the high-definition mini-probe with a field of view of 240 μm with a lateral resolution of 1 μm and confocal depth of 55 to 65 μm . Under the mosaic function, acquired images are constructed together and can expand the field of view.

Both CLE systems are capable of generating high-resolution endomicroscopy images capable of characterizing dysplasia in BE. The eCLE system has a wider range of imaging depth but it is limited by its acquisition rate as compared to the pCLE system which has the advantage of having video capability. The pCLE mini-probes can be used through any standard instrument channel. However, unlike the eCLE system, pCLE probes have a limited number of uses. Approximately 20 uses are available for the high-definition mini-probes.

Table 1 Comparison of endoscope-based (eCLE) and probe-based (pCLE) confocal laser endomicroscopy system

	eCLE	pCLE	
	EG-3870CILK, Pentax	Standard probe	HD probe
Field of view (μm)	475 \times 475	600	240
Lateral resolution (μm)	0.7	3.5	1.0
Axial resolution (μm)	7	15	5
Imaging depth (μm)	0-250	70-130	55-65




Figure 1 Endoscope-based confocal laser endomicroscopy system (CLE)

Contrast agents

Confocal laser endomicroscopy requires the use of a fluorescent contrast agent to enhance visualization of cells. Contrast agents can be administered intravenously or topically. Intravenous fluorescein sodium is the most widely used contrast agent in endomicroscopy. Although its use is considered off-label for CLE by the U.S. Food and Drug Agency, its safety is well documented in several CLE trials [5]. Self-limited yellowing of the skin, eyes and urine occurs in all patients. As such, this side effect should be disclosed to patients as part of the procedural consent process.



Figure 2 Probe-based confocal laser endomicroscopy system

CLE can be performed shortly following injection of fluorescein (2.5 to 5.0 mL) with its fluorescence lasting approximately 30 min. Fluorescein highlights mucosal capillaries as well as the extracellular space and lamina propria but does not penetrate the nucleus. The topical agent acriflavine hydrochloride can be used independently or in conjunction with fluorescein to highlight the cell nucleus. The use of acriflavine has fallen out of favor, however, over the concern with its carcinogenic potential. Another topical agent, cresyl violet is a cytoplasmic stain used to outline the nucleus. Moreover, acriflavine and cresyl violet are limited in terms of depth of penetration of the esophageal mucosa.

A newer topical agent, 2-[N-(7-nitrobenz-2-oxa-1,3-dioxol-4-yl) amino]-2-deoxyglucose (2-NBDG) is a glucose analog that is readily transported into cells with high metabolic activity. This glucose analog becomes fluorescent after cellular incorporation [6]. *Ex vivo* studies performed on endoscopic mucosal resection specimens, demonstrate that 2-NBDG has high specificity for dysplastic BE cells [7,8]. Its enhanced uptake in dysplastic Barrett's cells is mediated by a glucose transporter (GLUT-1) mechanism which is well recognized to be upregulated in esophageal neoplasia [9]. The use of 2-NBDG is currently being evaluated for *in vivo* endomicroscopy [10].

CLE technique for BE

The basic endomicroscopy technique relies on adequate contact of the imaging aperture in eCLE or the actual probe in pCLE with the esophageal mucosa. Stabilization to reduce movement artifact is crucial in order to obtain high quality images. In the eCLE system, suction is gently applied to stabilize the mucosa. Image sections are acquired starting at the surface and deep into the mucosa using controls on the endoscope handle. In the pCLE system the mini-probe can be stabilized using suction or with positioning of the probe within an endoscopic mucosal resection cap while images are captured using a foot pedal or computer interface.

Acquisition of targeted biopsies can be achieved with both CLE systems. In pCLE, an area adjacent to the area of interest can be marked using argon plasma coagulation. The mini-probe is then removed to allow for biopsy acquisition through the instrument channel. In the eCLE system biopsy acquisition and endomicroscopy can be performed simultaneously, however, it must be taken into account that the confocal imaging window is located to the side of the standard-endoscopy window and as a result the view under white-light endoscopy does not represent the area of interest under endomicroscopy. The endoscopist must adjust for this discrepancy by targeting sites to the left of the suction channel using a suction mark as a reference point.

CLE criteria for the detection of Barrett's dysplasia

The first report on the use of eCLE in BE was conducted by Kiesslich *et al* [11]. Vessels and cellular architecture

observed under endomicroscopy were compared to histology from targeted biopsies. Based on their observation, Kiesslich *et al* organized the confocal Barrett's classification system, also known as the Mainz criteria (Fig. 3). With expert image acquisition and interpretation, use of the Mainz criteria demonstrated a sensitivity and specificity of 98% and 94% for BE and 93% and 94% for BE-associated dysplasia, respectively in predicting *in vivo* histology. In addition, excellent inter and intra-observer agreement was reported using this classification system (kappa 0.84 and 0.89 respectively). A subsequent prospective randomized double-blinded crossover trial compared the diagnostic efficiency of eCLE with targeted biopsies to a standard endoscopy biopsy acquisition protocol [3]. The investigators report that eCLE with targeted biopsies improved the diagnostic yield for high-grade dysplasia compared to random biopsies (33.7% versus 17.2%) and lowered the mean number of acquired mucosal biopsy specimens (9.8 versus 23.7). Of note, this study was not designed to assess diagnostic accuracy given that mucosal biopsies during eCLE were only performed for suspected BE lesions with high grade dysplasia. A more recent study that compared high-definition white-light endoscopy with random biopsies to endoscopy plus eCLE with targeted biopsies showed that the use of eCLE can help guide *in vivo* decision making and alter endoscopic outcomes. In this study, the combination of high-definition white light endoscopy and eCLE increased the diagnostic yield for neoplasia (22% versus 6%) and significantly lowered the number of required biopsies [12].

The application of the Mainz criteria to pCLE had technical differences which lead to the development of a pCLE-specific classification system. Several studies have examined confocal images using pCLE to distinguish dysplastic from non-dysplastic BE. The parameters used to differentiate dysplastic from non-dysplastic BE are presented in Table 2. The reported average sensitivity and specificity in this preliminary study were 75% and 90% respectively with a positive predictive value of 44% and negative predictive value of 98%. There was good inter-observer agreement (kappa 0.6). These criteria were further refined and validated to become the current Miami criteria for pCLE [13] (Fig. 4). The sensitivity and specificity for the detection of dysplasia using these criteria was 88% and 96% respectively with substantial inter-observer agreement (kappa 0.72) [14]. *In vivo* detection of dysplasia using pCLE was evaluated in a multicenter non-inferiority study by Bajbouj *et al* that interpreted pCLE recordings during endoscopy with a follow-up of 3 months post-procedurally. A total of 670 pCLE videos were compared to matching biopsy histopathology. *In vivo* evaluation of dysplasia yielded a specificity of 95% and sensitivity of 12% with a negative predictive value of 92% and positive predictive value of 18%. Post-procedure evaluation showed slightly higher specificity (97%) and sensitivity (28%) with a negative predictive value of 93% and positive predictive value of 46%. The authors conclude that pCLE is non-inferior to standard biopsy surveillance but recommend against completely replacing standard biopsy acquisition with endomicroscopy imaging.




Figure 3 Cellular and vascular characteristic of gastric, Barrett's and neoplastic epithelium in confocal laser endomicroscopy based on the Mainz criteria. Adapted from Kiesslich *et al* [11]

Table 2 Characteristics of dysplastic Barrett's esophagus in probe-based confocal laser endomicroscopy system

Characteristics
Irregular epithelial lining
Variable width of epithelial lining
Fusion of glands
Decreased uptake of fluorescein
Irregular vascular pattern

A subsequent multicenter international randomized controlled trial (DON'T BIOPCE) compared high-definition endoscopy, narrow band imaging and pCLE to matching biopsy histopathology [15]. The specificity and sensitivity for the detection of high-grade dysplasia using high-definition endoscopy alone was 34% and 93% respectively, compared to 68% and 88% in combination with pCLE. The authors conclude that pCLE led to significant improvement in the detection of neoplasia but recognize that the study was conducted by gastroenterologists with previous experience in endomicroscopy.

pCLE criteria using the newer high-definition mini-probe were recently developed in a single center two phase study of 50 pCLE videos from the DON'T BIOPCE trial were compared to histopathology by a gastroenterologist with experience in pCLE and an experienced gastrointestinal pathologist [16]. Criteria

with high sensitivity and specificity (>70%) were pre-selected resulting in two or more of six criteria to define dysplasia such as saw-toothed epithelial surface, enlarged pleomorphic cells, unequal gland size and distance and not easily identifiable goblet cells. The sensitivity and specificity in the diagnosis of dysplasia tested on 30 different pCLE videos was 76% and 85%, respectively. The positive predictive and negative predictive values were 76% and 85% respectively. Accuracy in diagnosing dysplasia was 82% with substantial agreement (kappa 0.61) and no difference between experts and non-experts. These criteria have not undergone *in vivo* validation.

We recently published a comparative study of the diagnostic performance of eCLE and pCLE platforms for Barrett's dysplasia using a topical fluorescent marker, 2-NBDG [17]. In this study, we also introduced a new set of simplified fluorescence intensity criteria for CLE (Fig. 5). The new fluorescence criteria in conjunction with the eCLE system resulted in significantly higher accuracy in dysplasia detection and inter-observer agreement. This fluorescence criteria improved diagnostic accuracy of dysplasia even when used by gastroenterologists with no prior CLE experience. *In vivo* validation of these criteria is still being conducted by our research center.

CLE-guided therapy in BE

CLE has the potential to guide BE therapy by providing real-time assessment of dysplasia. In a retrospective case series,

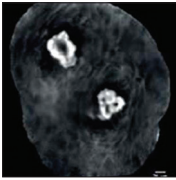
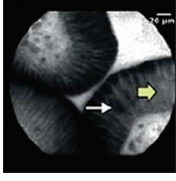
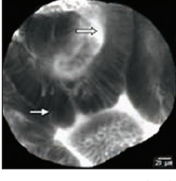
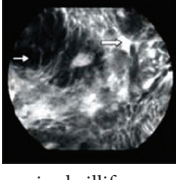
Histology	Confocal laser endomicroscopy characteristics
Normal squamous epithelium	 <p>(A) Flat cells with bright intrapapillary capillary loops</p>
Non-dysplastic Barrett's epithelium	 <p>(B) Uniformed villiform architecture with dark goblet cells</p>
Barrett's esophagus with high-grade dysplasia	 <p>(C) Villiform structures with dark, irregular and thick borders</p>
Adenocarcinoma	 <p>(D) Disorganized villiform architecture and dilated irregular vessels</p>

Figure 4 Confocal laser endomicroscopy characteristics of squamous, dysplastic and non-dysplastic Barrett's esophagus and associated adenocarcinoma based on the Miami criteria. Adapted from Wallace *et al* [13]

Johnson *et al* used pCLE in four patients with high-grade dysplasia to guide endoscopic mucosal resection and ablation therapy [18]. In this study, pCLE was also used after therapy to evaluate post-treatment margins with one patient undergoing repeat endoscopic mucosal resection. Another case series of seven patients with high grade dysplasia used pCLE as part of the initial and subsequent treatment session [19]. In this series, pCLE led to additional endoscopic mucosal resections in one patient over an area that was not immediately apparent under high definition white light endoscopy.

The only report of eCLE application for BE therapy at the point-of-care setting is a single case reported by Leung *et al* in which endomicroscopy helped guide endoscopic mucosal resection in a patient with focal high-grade dysplasia [20]. A case series of 27 patients undergoing endoscopic therapy for gastric cancer used eCLE two weeks following endoscopic mucosal resection to evaluate the circumferential margins for

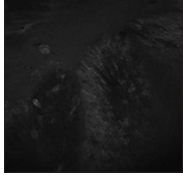
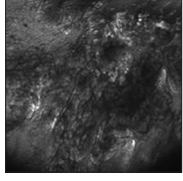
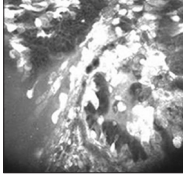
Histology	Characteristics
Normal gastric epithelium	 <p>(A) Absence of fluorescence</p>
Non-dysplastic Barrett's epithelium	 <p>(B) Minimal extracellular fluorescence</p>
Barrett's esophagus with dysplasia	 <p>(C) Intense fluorescence and disorganized cellular architecture</p>

Figure 5 Fluorescence criteria in differentiating gastric type epithelium, dysplastic and non-dysplastic Barrett's esophagus. Adapted from Gorospe *et al* [17]

completeness of excision [21]. Twenty patients underwent eCLE by an endoscopist blinded to histopathology. The accuracy of eCLE in predicting incomplete resection was 92% with a sensitivity and specificity of 100% and 90% respectively. There were 6 patients who had additional endoscopic mucosal resections guided by eCLE.

The role of endomicroscopy in post radiofrequency ablation BE patients was assessed in a multicenter randomized-controlled trial in which post-ablation patients underwent surveillance with high-definition white light endoscopy or high definition white light endoscopy plus pCLE [22]. Patients with suspected dysplasia underwent biopsy plus ablation while patients with no suspected dysplasia underwent biopsy alone. The main outcome of the study was the proportion of optimally treated patients, defined as the absence of dysplasia. This study was terminated early due to lack of statistical difference in the proportion of optimally treated patients between both groups concluding that there is no evidence of improved treatment outcomes with the addition of pCLE to high definition white light endoscopy in post-ablation patients.

Limitations and directions for future development

CLE has an acceptable sensitivity but a poor positive predictive value in detecting early neoplasia in BE [23,24]. In addition, a recent meta-analysis on the diagnostic performance

of CLE showed a per-lesion pooled sensitivity and specificity of 68% (95% CI: 64-73%) and 88% (95% CI: 87-89%), respectively [25]. The major limitation of CLE is its narrow field of view that is prone to sampling error depending on the placement of the CLE probe in the esophageal mucosa. Furthermore, available contrast agents for CLE are not specific for dysplasia as they simply rely on vascular and cellular staining patterns.

While CLE may not readily replace biopsies with histopathology at its present state of technology, CLE may enhance BE surveillance by providing real-time evaluation and the ability to recognize suspected focal areas of dysplasia for targeted biopsy. The development of topical fluorescent peptides with high affinity to BE dysplasia along with newer endoscopes with fluorescence capability may allow for both endoscopic and near-histologic evaluation when used in conjunction with CLE [26]. CLE can also be used in combination with narrow band imaging but this does not appear to have a significant incremental diagnostic yield compared to high-definition white light endoscopy [27]. Other enhanced endoscopic imaging modalities such as chromoendoscopy and I-SCAN have also fallen out of favor for the detection of Barrett's-associated dysplasia. Due to their low diagnostic yield, we do not foresee any advantage in combining CLE with these relatively less popular imaging technologies [28].

Comprehensive wide-field examination of the esophagus can now be performed with volumetric laser endomicroscopy (VLE), a novel imaging technology similar to optical coherence tomography [29]. The use of VLE alongside CLE may provide the dual advantage of both wide-field imaging and a narrow high magnification of dysplastic mucosa *in vivo* setting.

Concluding remarks

CLE can facilitate *in vivo* diagnosis of BE and associated dysplasia. Its accuracy in detecting high grade dysplasia is comparable to conventional biopsies. However, there is still room for improvement for other grades of dysplasia. The role of CLE in BE surveillance and treatment is evolving. The high resolution point-imaging capability of CLE may be an excellent adjunct to newer imaging technologies capable of achieving comprehensive views of the esophagus. The current classification criteria and available contrast agents will continue to be refined in order to enhance interpretability of confocal imaging and acceptability among practicing endoscopists, specializing in the management of BE and early esophageal cancers.

References

1. Chandra S, Gorospe EC, Leggett CL, Wang KK. Barrett's esophagus in 2012: updates in pathogenesis, treatment, and surveillance. *Curr Gastroenterol Rep* 2013;15:322.
2. Peters FP, Curvers WL, Rosmolen WD, et al. Surveillance history of endoscopically treated patients with early Barrett's neoplasia: nonadherence to the Seattle biopsy protocol leads to sampling

error. *Dis Esophagus* 2008;21:475-479.

3. Dunbar KB, Okolo P, 3rd, Montgomery E, Canto MI. Confocal laser endomicroscopy in Barrett's esophagus and endoscopically inapparent Barrett's neoplasia: a prospective, randomized, double-blind, controlled, crossover trial. *Gastrointest Endosc* 2009;70:645-654.
4. De Palma GD. Confocal laser endomicroscopy in the "in vivo" histological diagnosis of the gastrointestinal tract. *World J Gastroenterol* 2009;15:5770-5775.
5. Wallace MB, Meining A, Canto MI, et al. The safety of intravenous fluorescein for confocal laser endomicroscopy in the gastrointestinal tract. *Aliment Pharmacol Ther* 2010;31:548-552.
6. O'Neil RG, Wu L, Mullani N. Uptake of a fluorescent deoxyglucose analog (2-NBDG) in tumor cells. *Mol Imaging Biol* 2005;7:388-392.
7. Gorospe EC, Tian JM, Anderson M, et al. A Potential new marker of dysplasia: 2-Nbdg in Barrett's esophagus cell lines. *Gastroenterology* 2011;140:S215-S215.
8. Thekkekk N, Maru DM, Polydorides AD, Bhutani MS, Anandasabapathy S, Richards-Kortum R. Pre-clinical evaluation of fluorescent deoxyglucose as a topical contrast agent for the detection of Barrett's-associated neoplasia during confocal imaging. *Technol Cancer Res Treat* 2011;10:431-441.
9. Kato H, Takita J, Miyazaki T, et al. Glut-1 glucose transporter expression in esophageal squamous cell carcinoma is associated with tumor aggressiveness. *Anticancer Res* 2002;22:2635-2639.
10. Leggett CL, Sun G, Chowdhury S, et al. Topical esophageal delivery of a fluorescent marker of dysplasia in Barrett's esophagus: a feasibility study. *Gastroenterology* 2013;144:S694-S694.
11. Kiesslich R, Gossner L, Goetz M, et al. In vivo histology of Barrett's esophagus and associated neoplasia by confocal laser endomicroscopy. *Clin Gastroenterol Hepatol* 2006;4:979-987.
12. Canto MI, Anandasabapathy S, Brugge W, et al. In vivo endomicroscopy improves detection of Barrett's esophagus-related neoplasia: a multicenter international randomized controlled trial (with video). *Gastrointest Endosc* 2014;79:211-221.
13. Wallace M, Lauwers GY, Chen Y, et al. Miami classification for probe-based confocal laser endomicroscopy. *Endoscopy* 2011;43:882-891.
14. Wallace MB, Sharma P, Lightdale C, et al. Preliminary accuracy and interobserver agreement for the detection of intraepithelial neoplasia in Barrett's esophagus with probe-based confocal laser endomicroscopy. *Gastrointest Endosc* 2010;72:19-24.
15. Sharma P, Meining AR, Coron E, et al. Real-time increased detection of neoplastic tissue in Barrett's esophagus with probe-based confocal laser endomicroscopy: final results of an international multicenter, prospective, randomized, controlled trial. *Gastrointest Endosc* 2011;74:465-472.
16. Gaddam S, Mathur SC, Singh M, et al. Novel probe-based confocal laser endomicroscopy criteria and interobserver agreement for the detection of dysplasia in Barrett's esophagus. *Am J Gastroenterol* 2011;106:1961-1969.
17. Gorospe EC, Leggett CL, Sun G, et al. Diagnostic performance of two confocal endomicroscopy systems in detecting Barrett's dysplasia: a pilot study using a novel bioprobe in ex vivo tissue. *Gastrointest Endosc* 2012;76:933-938.
18. Johnson EA, De Lee R, Agni R, Pfau P, Reichelderfer M, Gopal DV. Probe-based confocal laser endomicroscopy to guide real-time endoscopic therapy in Barrett's esophagus with dysplasia. *Case Rep Gastroenterol* 2012;6:285-292.
19. Konda VJ, Chennat JS, Hart J, Waxman I. Confocal laser endomicroscopy: potential in the management of Barrett's esophagus. *Dis Esophagus* 2010;23:E21-E31.
20. Leung KK, Maru D, Abraham S, Hofstetter WL, Mehran R, Anandasabapathy S. Optical EMR: confocal endomicroscopy-targeted EMR of focal high-grade dysplasia in Barrett's esophagus. *Gastrointest Endosc* 2009;69:170-172.

21. Li Z, Yu T, Zuo XL, et al. Confocal laser endomicroscopy for in vivo diagnosis of gastric intraepithelial neoplasia: a feasibility study. *Gastrointest Endosc* 2010;**72**:1146-1153.
22. Wallace MB, Crook JE, Saunders M, et al. Multicenter, randomized, controlled trial of confocal laser endomicroscopy assessment of residual metaplasia after mucosal ablation or resection of GI neoplasia in Barrett's esophagus. *Gastrointest Endosc* 2012;**76**:539-547 e531.
23. Pohl H, Rosch T, Vieth M, et al. Miniprobe confocal laser microscopy for the detection of invisible neoplasia in patients with Barrett's oesophagus. *Gut* 2008;**57**:1648-1653.
24. Bajbouj M, Vieth M, Rosch T, et al. Probe-based confocal laser endomicroscopy compared with standard four-quadrant biopsy for evaluation of neoplasia in Barrett's esophagus. *Endoscopy* 2010;**42**:435-440.
25. Gupta A, Attar BM, Koduru P, Murali AR, Go BT, Agarwal R. Utility of confocal laser endomicroscopy in identifying high-grade dysplasia and adenocarcinoma in Barrett's esophagus: a systematic review and meta-analysis. *Eur J Gastroenterol Hepatol* 2014;**26**:369-377.
26. Li M, Anastassiades CP, Joshi B, et al. Affinity peptide for targeted detection of dysplasia in Barrett's esophagus. *Gastroenterology* 2010;**139**:1472-1480.
27. Jayasekera C, Taylor AC, Desmond PV, Macrae F, Williams R. Added value of narrow band imaging and confocal laser endomicroscopy in detecting Barrett's esophagus neoplasia. *Endoscopy* 2012;**44**:1089-1095.
28. Verna C, Feyles E, Lorenzi L, et al. I-SCAN targeted versus random biopsies in Barrett's oesophagus. *Dig Liver Dis* 2014;**46**:131-134.
29. Yun SH, Tearney GJ, Vakoc BJ, et al. Comprehensive volumetric optical microscopy in vivo. *Nat Med* 2006;**12**:1429-1433.