

Hepatic artery duplex Doppler ultrasound in severe alcoholic hepatitis and correlation with Maddrey's discriminant function

Haridas Abhilash, Madhavan Mukunda, Premaletha Sunil, Krishnadas Devadas, Katoor Ramakrishnan Nair Vinayakumar

Government Medical College, Thiruvananthapuram, Kerala, India

Abstract

Background Alcoholic hepatitis is associated with altered hepatic artery hemodynamics. Maddrey's discriminant function (MDF) can identify patients with poor prognosis ($DF > 32$). We studied hepatic artery hemodynamic parameters of hepatic artery diameter (HAD), resistive index (RI) and pulsatility index (PI) in severe acute alcoholic hepatitis (SAAH) and for the presence of correlation of parameters with severity factor MDF.

Methods A total of 20 consecutive SAAH patients defined as $MDF > 32$ and a group of 20 alcoholic cirrhosis patients without alcoholic hepatitis formed the two study groups. Hepatic artery Doppler parameters HAD, RI, PI were determined after admission in the Gastroenterology Department, Government Medical College, Thiruvananthapuram, India. MDF score of SAAH was calculated at the time of admission to the hospital.

Results The mean HAD showed statistically significant increase in SAAH compared with cirrhosis (3.96 ± 0.51 vs. 2.86 ± 0.41 , $P < 0.001$). There was statistically significant decrease in mean RI (0.49 ± 0.08 vs. 0.81 ± 0.09 , $P < 0.001$) and mean PI (1.67 ± 0.13 vs. 1.80 ± 0.13 , $P < 0.001$) in SAAH compared with alcoholic cirrhosis. Statistically significant correlation between MDF and HAD ($r = 0.63$, $P < 0.003$) was found in SAAH. On linear regression, 36% of the variability in MDF could be independently predicted by HAD.

Conclusion Hepatic artery parameters of HAD, RI, PI had a significant difference in SAAH compared with alcoholic cirrhosis patients thereby being useful as a diagnostic tool. HAD showed correlation with MDF score assessing the severity of alcoholic hepatitis and may be a useful non-invasive prognostic tool.

Keywords Alcoholic hepatitis, hepatic artery, duplex Doppler ultrasound, Maddrey's discriminant function

Ann Gastroenterol 2015; 28 (2): 271-275

Introduction

The spectrum of alcoholic liver disease comprises steatosis, alcoholic hepatitis, cirrhosis, and the development of hepatocellular cancer. Acute alcoholic hepatitis (AAH) is a clinicopathologic syndrome leading to the development of cirrhosis in at least 40% of cases [1]. Alcoholic hepatitis is associated with hepatic bruit due to increased flow, and

Doppler studies have shown their utility in the diagnosis by assessing hepatic artery peak systolic velocity (PSV) and pseudo parallel channel sign (PPCS) [2,3]. Severe alcoholic hepatitis has a high mortality, and prognostic models have been designed to identify patients with severe alcoholic hepatitis at high risk of early mortality. The Maddrey's discriminant function (MDF) was the first score to be developed and remains the most widely used. In the absence of treatment, the 1-month spontaneous survival of patients with a $MDF \geq 32$ has fluctuated between 50% and 65% [4,5]. There is a scarcity of data on hemodynamic studies in severe alcoholic hepatitis. We examined hepatic artery hemodynamic parameters of HAD, resistive index (RI) and pulsatility index (PI) in severe acute alcoholic hepatitis (SAAH) patients compared with alcoholic cirrhosis patients without alcoholic hepatitis, and looked for the presence of any correlation of these parameters with the severity factor MDF.

Government Medical College, Thiruvananthapuram, Kerala, India

Conflict of Interest: None

Correspondence to: Dr Haridas Abhilash, DM Gastroenterology Resident, Department of Gastroenterology, Government Medical College, Thiruvananthapuram, Kerala, India, Tel.: +098 953 04566, e-mail: abhilashsaras@gmail.com

Received 01 July 2013; accepted 15 August 2014

Patients and methods

The study subjects were 20 consecutive SAAH patients and 20 alcoholic cirrhosis patients without alcoholic hepatitis who served as controls. All patients were treated at the Gastroenterology Department, Government Medical College, Thiruvananthapuram, India, from September 2011 to September 2012. Diagnostic criteria for alcoholic hepatitis included chronic alcohol consumption of at least 20 g per day with a recent history of heavy alcohol ingestion, elevation of serum aspartate aminotransferase (AST) at least twice above the alanine aminotransferase (ALT) level, jaundice, coagulopathy, and at least two of the following features: tender hepatomegaly, presence of a hepatic bruit, fever (temperature >100°F), or leukocytosis (white blood cell count >10,000/mm³). The study included SAAH patients as defined by MDF >32 on admission. The control group included patients with clinically, radiologically, and biochemically proven alcoholic cirrhosis without alcoholic hepatitis and alcohol abstinent for at least 1 year. Exclusion criteria included patients with portal vein thrombosis, active gastrointestinal bleeding, active infection including spontaneous bacterial peritonitis, patients already on steroids or pentoxifylline, MDF <32 and patients in whom hepatic artery Doppler was not feasible due to anatomical variations.

Duplex Doppler ultrasound (Toshiba Nemio, Japan) examination was performed using transducers with a frequency of 3.5 MHz. All subjects had fasted for at least 8 h before scanning. Scans were performed with the patients in the supine position using both Gray-scale and color Doppler imaging to identify vascular landmarks. Doppler tracings were acquired during suspended respirations. The right hepatic artery was visualized at the porta hepatis as it crosses the main portal vein in all patients. At least three similar, sequential waveforms were obtained at measured angles of insonation of <60°. The best tracing was selected for analysis. RI and PI were then calculated as follows: RI = (PSV – end diastolic velocity)/PSV, and PI = (PSV – end diastolic velocity)/mean velocity. An average HAD was obtained using Gray scale imaging in the transverse plane. Patients in SAAH group had severity assessed by MDF on admission before initiating pentoxifylline or prednisolone.

Statistical analysis

Quantitative variables were expressed as mean ± standard deviation, and qualitative variables as proportions. The mean difference in HAD, RI and PI between the two groups were compared using Student's *t*-test. Correlation of MDF with HAD, RI, and PI was checked using Pearson correlation. Linear regression was used to predict MDF. SPSS version 16 was used for statistical analysis.

Results

The clinical and laboratory characteristics of both study groups are presented in Table 1. All patients were male. The

mean age of patients and duration of alcohol consumption did not differ significantly between the two groups. Fever and hepatic bruit were present in 12 SAAH patients, and in none of the cirrhotic patients. Ascites though more frequent in the alcoholic cirrhosis group was not significantly different between groups (P value >0.05), and hepatomegaly was significantly greater in SAAH group (P value <0.05) (Table 1).

Liver function test showed a statistically significant difference in serum bilirubin (P value <0.001), AST (P value <0.001) and ALT (P value <0.001) levels. Their mean values were higher in SAAH group compared with alcoholic cirrhosis group. The prothrombin time and albumin were comparable in two groups (P value >0.05). Leukocyte count (P value <0.001) and serum creatinine (P value <0.001) were also significantly higher in severe alcoholic hepatitis group (Table 1).

Duplex Doppler parameters of HAD, RI and PI of both groups are summarized in Table 1. The mean hepatic artery diameter (HAD) in SAAH was 3.96±0.51 mm compared with cirrhotic patients with 2.86±0.41 mm (P<0.001) (Fig. 1). The mean RI in SAAH was lower with 0.49±0.08 compared with cirrhotic patients with 0.81±0.09 (P<0.001). The mean PI in SAAH was lower 1.67±0.13 compared with cirrhotic patients with 1.80±0.13 (P<0.003). The coefficient of variation (CV) for intraobserver variability was 7.4±4.2% for RI and 8.8±5.2% for PI; the corresponding figures for interobserver variability were 6.2±3.9% and 10.2±5.6%, respectively.

Table 1 Baseline characteristics

	SAAH (n=20)	Alcoholic cirrhosis (n=20)	P value
Gender (Male)	20	20	NS
Mean age (years)	40.6±10.8	40.2±9.5	NS
Alcohol use (in years)	15±6.2	16.5±5	NS
Ascites	12	15	NS
Hepatomegaly	20	14	0.008
Bruit	12	0	<0.001
Fever	12	0	<0.001
Total bilirubin (mg/L)	15±7.6	4.9±1.9	<0.001
AST (IU/L)	196±53	77±16	<0.001
ALT (IU/L)	72±23	38±7.7	<0.001
PT (s)	21.7±3	20±2.8	NS
Albumin (g/dL)	2.9±0.4	2.8±0.2	NS
WBC count (×1000/mL)	13.7±4.7	7.6±1.3	<0.001
Creatinine (mg/dL)	1.3±0.5	1.1±0.3	<0.003
HAD in mm	3.95±0.5	2.8±0.4	<0.001
RI	0.48±0.07	0.8±0.08	<0.001
PI	1.6±0.13	1.8±0.13	<0.003

P values were determined using the Chi-square test or Fisher's exact test for the dichotomous variables and Student's *t*-test for continuous variables. NS, not significant; SAAH, severe acute alcoholic hepatitis; AST, aspartate aminotransferase; ALT, alanine aminotransferase; PT, prothrombin time; WBC, white blood cells; HAD, hepatic artery diameter; RI, resistive index; PI, pulsatility index

The mean MDF was 58. HAD showed a significant correlation with MDF (Table 2 and Fig. 2). Regression analysis showed that 36% of the variability in MDF could be independently predicted by HAD. Coefficients of regression analysis are provided in Table 3.

Discussion

Duplex Doppler ultrasonography can noninvasively assess hepatic hemodynamics [6,7]. In our study, ultrasound Doppler revealed a significantly greater dilatation of the hepatic artery in SAAH compared to alcoholic cirrhosis patients (3.96±0.51 mm vs. 2.86±0.4 mm). Wing *et al* described a unique “parallel tubular” appearance of intrahepatic vessels in a cohort of alcoholic patients, which subsequently was demonstrated to represent dilated intrahepatic arteries [8]. In alcoholic hepatitis,

intrahepatic artery dilation has been described by Sumino *et al* and termed as pseudoparallel channel sign characterized by dilated intrahepatic arterial branch with an adjacent portal venous tract. They observed PPCS in 90% of patients of AAH and in 23% of patients other than alcoholic liver disease. PPCS gave a sensitivity of 82%, specificity of 87% and diagnostic accuracy of 84% in diagnosing AAH [2,3]. Han *et al* showed quantitatively that there was a significant increase in HAD and peak systolic velocity in patients with AAH compared with cirrhotic patients and healthy subjects [9].

In our study, all patients were male. Experimental porcine model showed a significant difference in biomechanical properties of the hepatic artery with respect to gender [10]. There is a scarcity of clinical studies on hepatic artery hemodynamics with respect to gender.

A prospective multicenter study shows that severely altered portal flow is common in patients with severe AH and associated with poor outcome [11]. The hepatic arterial buffer response (HABR) is proposed to occur in conditions of decreased portal flow. HABR is an intrinsic regulatory mechanism of the liver to maintain total hepatic blood flow when portal perfusion decreases. Increased hepatic arterial blood flow mediated by adenosine washout in the portal triad compensates for the reduced portal blood flow [12,13]. Histological studies demonstrate the presence of dense sinusoidal collagen deposits in patients with AAH. Increased sinusoidal resistance impedes blood flow through the hepatic sinusoids. Ultimately, sinusoidal pressure builds until portal blood flow is compromised in a retrograde manner, with

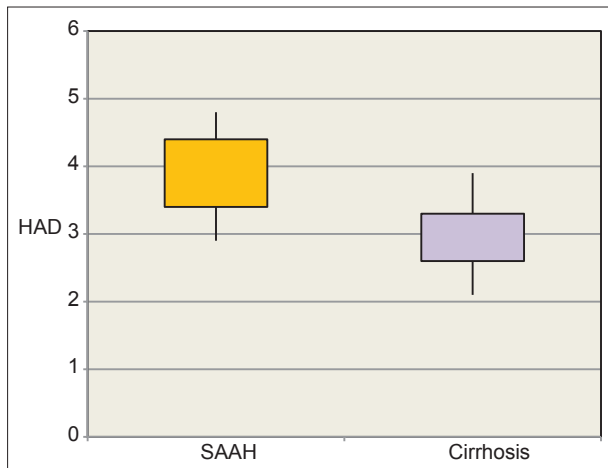


Figure 1 The mean HAD in SAAH was 3.96±0.51 mm compared to cirrhosis group with 2.86±0.41 mm which was statistically significant (P<0.001)
HAD, hepatic artery diameter; SAAH, severe acute alcoholic hepatitis

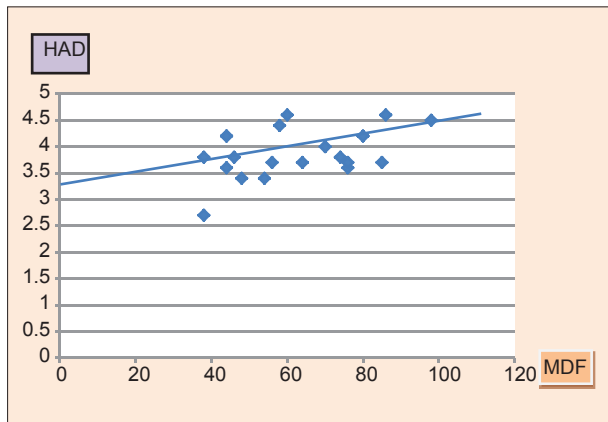


Figure 2 In severe alcoholic hepatitis there was statistically significant co-relation between DF and HAD
MDF, Maddrey's discriminant function; HAD, hepatic artery diameter

Table 2 Correlation of duplex Doppler ultrasound parameters to Maddrey's discriminant function (MDF) in severe alcoholic hepatitis

Hepatic artery parameters	Pearson correlation (r)	P value
HAD	0.625	0.003
RI	-0.295	0.2
PI	0.144	0.5

Correlation of MDF with HAD, RI and PI was checked using Pearson correlation

HAD, hepatic artery diameter; RI, resistive index; PI, pulsatility index

Table 3 Regression analysis with variables inserted and coefficients

SAAH	Regression analysis - coefficients ^a				
	Unstandardized coefficients		Standardized coefficients	t	Sig.
	B	Std. error	Beta		
(Constant)	-50.469	53.698	-00.940	0.361	
HAD	19.851	6.962	0.588	2.851	0.012
RI	-25.027	46.680	-0.115	-00.536	0.599
PI	25.702	25.144	0.201	1.022	0.322

^aDependent variable: MDF, HAD, RI and PI were used to predict MDF using multiple linear regression. Using stepwise backward elimination, only HAD significantly predicted MDF in the final model

SAAH, severe acute alcoholic hepatitis; HAD, hepatic artery diameter; RI, resistive index; PI, pulsatility index; MDF, Maddrey's discriminant function; Sig., significance

marked reduction in portal venous perfusion of the sinusoids. The reciprocal response of hepatic arterial blood flow to reduction in portal venous perfusion is well-established [12]. To preserve the perfusion to the liver, compensatory dilation of the hepatic artery occurs with subsequent increase in hepatic artery flow. The mean HAD was greater in our study as we studied only SAAH patients with MDF >32 compared to MDF range of 13.0-64.6 in the study by Han *et al* [9].

Hepatic bruit was present in 12 of 20 SAAH patients but none in the alcoholic cirrhosis group. In AAH, hepatic artery angiography demonstrates stretched and elongated hepatic arteries, whereas others describe long and tortuous arteries [13,14]. Hepatic bruit results from the high-frequency vibration of the perivascular tissue induced by turbulent flow through the tortuous hepatic artery, but is not specific for alcoholic hepatitis, however as it can also occur in hepatoma, arterio-venous fistula and hemangioma [15].

In our study, we found significantly lower RI and PI in SAAH compared to cirrhotic patients. Han *et al* in their study found RI and PI to be significantly lower in patients with AAH compared with healthy controls, although not significantly different from patients with decompensated alcoholic cirrhosis [9]. Their study did confirm an increase in hepatic arterial blood flow, evidenced by significantly higher PSV and HAD in patients with AAH when compared with cirrhotic patients and healthy controls. In the study by Colli *et al* a significant difference in RI and PI between patients with alcoholic hepatitis and alcoholic cirrhosis was found [16]. The variables RI and PI are indicators of vascular impedance. Ethanol itself may be responsible for hepatic artery dilatation as it has been seen in chronic alcoholic patients without liver damage [16]. However, progression of alcoholic hepatitis to cirrhosis profoundly impairs the hepatic arterial responsiveness as a result of fibrosis with a vascular distortion. In our study, the CV for intraobserver variability was $7.4 \pm 4.2\%$ for RI and $8.8 \pm 5.2\%$ for PI; the corresponding figures for interobserver variability were $6.2 \pm 3.9\%$ and $10.2 \pm 5.6\%$ respectively. The relevance of the hepatic artery RI in AAH has been challenged by Han *et al*, who reported a high variability of this sign in patients with liver disease due to factors such as vessel compliance and different states of fasting [9].

The most interesting finding of our study was the significant correlation of HAD with MDF of SAAH and that 36% of the variability in MDF could be independently predicted by HAD. Other Doppler parameters RI and PI showed no correlation with MDF. In the study by Han *et al* there was no correlation between the duplex Doppler ultrasound parameters and the severity of liver disease as assessed by MDF. We included only SAAH patients with mean MDF of 58 compared with mean MDF 34 (range of 13.0-64.6) in the study by Han *et al*. The SAAH group in our study had high mean MDF and mean serum creatinine indicating severe liver dysfunction.

In the past, hepatic artery caliber assessed angiographically has been studied as an index for liver function in chronic liver disease [17]. Severe alcoholic hepatitis is associated with major changes in portal flow defined as reversal or alternating flow in the portal trunk and/or in intrahepatic portal branches and is independently associated with poor survival. Resolution of AH can contribute to both the restoration of portal blood flow toward

normal and the improvement in liver function [11]. In a similar manner, our study found hepatic artery dilatation to correlate with the severity of alcoholic hepatitis and it is reasonable to suggest that resolution of SAAH can result in regression of hepatic artery dilatation. In SAAH as portal flow decreases, HADR compensatory response tries to maintain hemodynamics, adequate liver function and metabolic homeostasis [18]. The increase in hepatic arterial blood flow however is capable of buffering up to 25-60% of the decreased portal flow [12,18].

Hepatic artery dilatation could also be due to high levels of endotoxemia that has been documented among patients who have alcoholic hepatitis; probably because of increased intestinal permeability [19]. In models of continuous intravenous infusion of *Escherichia coli* in rats, portal venous flow was reduced, and increased hepatic arterial flow resulted in unchanged total hepatic blood flow. The increased hepatic arterial flow could be a result of an active HADR [20,21]. Sato *et al* showed the effect of portal pressure (shear stress) to the triggering of regeneration and suggested that there was an upper limit to a beneficial effect of elevated portal pressure. Furthermore, it has been demonstrated that prevention of

Summary Box

What is already known:

- Alcoholic hepatitis is associated with altered hepatic hemodynamics
- Alcoholic hepatitis is associated with dilated intrahepatic arterial branch lying adjacent to portal venous branch called "pseudo parallel channel sign"
- Hepatic bruit is a feature of acute alcoholic hepatitis due to marked tortuosity and turbulent flow through hepatic arteries
- Severe alcoholic hepatitis has high mortality and Maddrey's discriminant function (MDF) >32 is associated with 1-month mortality of about 50%

What the new findings are:

- Hepatic artery hemodynamics as assessed by duplex Doppler are significantly altered in severe alcoholic hepatitis in comparison to alcoholic liver cirrhosis
- Hepatic artery diameter (HAD), hepatic artery resistive index and pulsatility index are useful parameters in the diagnosis of severe alcoholic hepatitis clinically
- Severe alcoholic hepatitis is associated with hepatic arterial buffer response induced marked hepatic artery dilatation evidenced by increased HAD in Doppler ultrasound
- HAD shows a significant correlation with MDF in severe alcoholic hepatitis and may be a useful non-invasive prognostic tool

shear stress after partial hepatectomy blocked the activation of regeneration cascade [22]. Hepatic artery dilatation could also be attributed to increase in oxygen consumption and attempted liver regeneration although altered immune response, presence of portocaval shunts and abnormal intrahepatic hemodynamics remain a major cause of reduced hepatic regenerative capacity. These hypotheses could explain why even in the absence of treatment, the 1-month spontaneous survival of patients with a MDF ≥ 32 fluctuates between 50% and 65% [4,5].

We did not study portal vein hemodynamics due to procedural time constraint and discomfort to SAAH study group. A hepatic artery Doppler study in a larger cohort of SAAH with follow-up scan after steroid treatment could be useful in assessing the prognostic value of this non-invasive tool.

In conclusion, duplex Doppler ultrasound parameters of the hepatic artery may be a useful tool in the diagnosis of SAAH in appropriate clinical setting and HAD may have a prognostic role in these patients.

Acknowledgment

We would like to thank the teaching community and staff members Government Medical College Thiruvananthapuram, Kerala, India. We express our gratitude to Dr. Rekha Rachel Philip, Assistant Professor, Department of Community Medicine, for assisting us in statistical work.

References

- Galambos JT, Shapira R. Natural history of alcoholic hepatitis. IV. Glycosaminoglycuronans and collagen in the hepatic connective tissue. *J Clin Invest* 1973;**52**:2952-2962.
- Sumino Y, Kravetz D, Kanel GC, McHutchison JG, Reynolds TB. Ultrasonographic diagnosis of acute alcoholic hepatitis 'pseudoparallel channel sign' of intrahepatic artery dilatation. *Gastroenterology* 1993;**105**:1477-1482.
- Sumino Y, Kusano M, Suzuki M, et al. Ultrasonographic diagnosis of acute alcoholic hepatitis: is "pseudoparallel channel sign" of intrahepatic artery dilatation available in Japan? *Ultrasound Med Biol* 1997;**23**:38.
- Lucey MR, Mathurin P, Morgan TR. Alcoholic hepatitis. *N Engl J Med* 2009;**360**:2758-2769.
- Maddrey WC, Boitnott JK, Bedine MS, Weber FL Jr, Mezey E, White RI Jr. Corticosteroid therapy of alcoholic hepatitis. *Gastroenterology* 1978;**75**:193-199.
- Grant EG, Schiller VL, Millener P, et al. Color Doppler imaging of the hepatic vasculature. *AJR Am J Roentgenol* 1992;**159**:943-950.
- Igneer A, Gebel M, Caspary WF, Dietrich CF. Doppler imaging of hepatic vessels - review. *Z Gastroenterol* 2002;**40**:21-32.
- Wing VW, Laing FC, Jeffrey RB, Guyon J. Sonographic differentiation of enlarged hepatic arteries from dilated intrahepatic bile ducts. *AJR Am J Roentgenol* 1985;**145**:57-61.
- Han SH, Rice S, Cohen SM, Reynolds TB, Fong TL. Duplex Doppler ultrasound of the hepatic artery in patients with acute alcoholic hepatitis. *J Clin Gastroenterol* 2002;**34**:573-577.
- Li J, Li WC, Song J, et al. Effect of sex on biomechanical properties of the proper hepatic artery in pigs and humans for liver xenotransplant. *Exp Clin Transplant* 2012;**10**:356-362.
- Duvoux C, Radier C, Roudot-Thoraval F, et al. Low-grade steatosis and major changes in portal flow as new prognostic factors in steroid-treated alcoholic hepatitis. *Hepatology* 2004;**40**:1370-1378.
- Eipel C, Abshagen K, Vollmar B. Regulation of hepatic blood flow: the hepatic arterial buffer response revisited. *World J Gastroenterol* 2010;**16**:6046-6057.
- Ho H, Sorrell K, Bartlett A, Hunter P. Modeling the hepatic arterial buffer response in the liver. *Med Eng Phys* 2013;**35**:1053-1058.
- Rourke JA, Bosniak MA, Ferris EJ. Hepatic angiography in "alcoholic hepatitis". *Radiology* 1968;**91**:290-296.
- Goldstein LI. Enlarged, tortuous arteries and hepatic bruit. *JAMA* 1968;**206**:2518-2520.
- Colli A, Coccio M, Mumoli N, Cattalini N, Fraquelli M, Conte D. Hepatic artery resistance in alcoholic liver disease. *Hepatology* 1998;**28**:1182-1186.
- Ezaki T, Mitsudomi T, Ikeda M, Yoshida Y, Okamura T, Ohnari N. Hepatic inflow vessels caliber as an index for liver function. *Hepatogastroenterology* 1996;**43**:427-431.
- Lautt WW. Regulatory processes interacting to maintain hepatic blood flow constancy: vascular compliance, hepatic arterial buffer response, hepatorenal reflex, liver regeneration, escape from vasoconstriction. *Hepatol Res* 2007;**37**:891-903.
- Gao B, Bataller R. Alcoholic liver disease: pathogenesis and new therapeutic targets. *Gastroenterology* 2011;**141**:1572-1585.
- Ghosh S, Latimer RD, Gray BM, Harwood RJ, Oduro A. Endotoxin-induced organ injury. *Crit Care Med* 1993;**21**:S19-S24.
- Fish RE, Lang CH, Spitzer JA. Regional blood flow during continuous low-dose endotoxin infusion. *Circ Shock* 1986;**18**:267-275.
- Sato Y, Tsukada K, Hatakeyama K. Role of shear stress and immune responses in liver regeneration after a partial hepatectomy. *Surg Today* 1999;**29**:1-9.