

Polycystic liver disease presenting as pruritus

Deepak Kochummen Johnson, Shihab Panchili, Sandesh Kolasseri,
Ramachandran Thazhath Mavali

Calicut Medical College, Calicut, India

Abstract

Polycystic liver disease (PCLD) is a rare autosomal dominant disorder which usually occurs in association with autosomal dominant polycystic kidney disease. Biliary obstruction is a rare complication of PCLD. Treatment options include percutaneous aspiration and sclerosis, surgical deroofing of cysts, liver resection or liver transplantation. Medical treatment involves the use of somatostatin analogues or mTOR inhibitors. We present a case of PCLD presenting for the first time with longstanding pruritus as the only symptom.

Keywords Polycystic liver disease, pruritus, autosomal dominant polycystic kidney disease

Ann Gastroenterol 2014; 27 (1): 76-78

Introduction

Polycystic liver disease (PCLD) is a rare autosomal dominant disorder characterised by multiple diffuse cystic lesions of the liver parenchyma. PCLD usually occurs in association with autosomal dominant polycystic kidney disease (ADPKD) [1] but can also present as isolated polycystic liver disease [2]. Liver cysts in PCLD usually remain asymptomatic. Jaundice due to biliary obstruction occurs in less than five percent of cases. We hereby report a rare presentation of a rare complication of a rare disease.

Case report

A 52-year-old female presented with generalized grade three pruritus of six months duration. There was no history of any skin lesions, fever, abdominal pain, jaundice or fatigue. Neither did she have any history of leg swelling, facial puffiness, decreased urine output or gastrointestinal bleed. She was detected to be hypertensive one year back for which Amlodipine was prescribed. Examination revealed a 5 cm hepatomegaly more in the epigastric region along with separate masses in both lumbar regions which were bimanually palpable and ballotable. Liver function test revealed normal bilirubin and

aminotransferases but a more than three times elevation of serum alkaline phosphatase and γ -glutamyl transferase. Renal function was normal and there was no proteinuria.

Initial ultrasound scan was followed by CT scan of abdomen (Fig. 1) which showed multiple noncommunicating cysts of varying size in both lobes of liver. There was mild dilation of intrahepatic biliary radicles in both lobes. Common hepatic duct and common bile duct (CBD) appeared normal. Both kidneys were bulky with multiple noncommunicating cysts.

MRI abdomen (Fig. 2) with MRCP (Fig. 3) showed multiple T2WI high signal parenchymal cysts mostly in the left lobe of liver, the largest measuring 9.8 x 6.7 cm. Mild dilation of intrahepatic bile ducts was seen. A few small cysts in communication with the dilated bile radicles were also noted. The proximal CBD was not visualized due to compression by the cysts at the porta hepatis. The distal CBD was normal in caliber. Spleen and pancreas were normal. Both kidneys

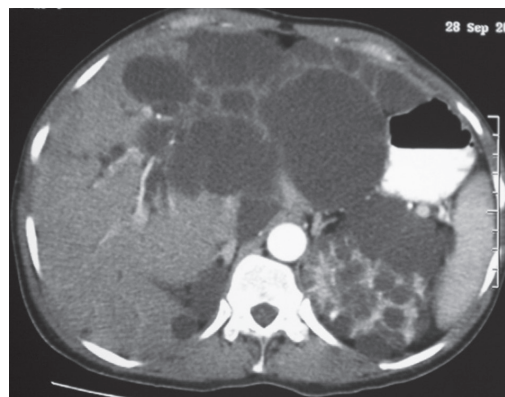


Figure 1 CT scan showing multiple non-communicating cysts in liver and kidney

Department of Gastroenterology, Calicut Medical College,
Calicut, India

Correspondence to: Ramachandran Thazhath Mavali, Additional
Professor, Department of Gastroenterology, Calicut Medical
College, Calicut 673008, India, Tel.: +91 98460 30979, e-mail:
drtmram@yahoo.com

Conflict of Interest: None

Received 16 April 2013; accepted 31 May 2013

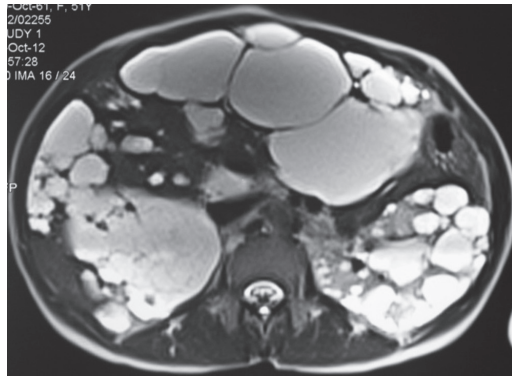


Figure 2 T2 weighted MRI showing multiple hyperintense cysts in liver and both kidneys

were markedly enlarged with parenchyma totally replaced by innumerable cortical cysts, the largest measuring 7x5.6 cm. The large cysts in the left lobe of liver and porta hepatis compressing the bile ducts were not communicating with the biliary system. A diagnosis of polycystic liver disease with Caroli's disease and biliary obstruction was made. The patient also had polycystic kidney disease. Hence our patient presented for the first time with longstanding pruritus as the only manifestation of polycystic liver disease.

The patient was planned for laparoscopic deroofting of liver cysts. However she was lost to follow up.

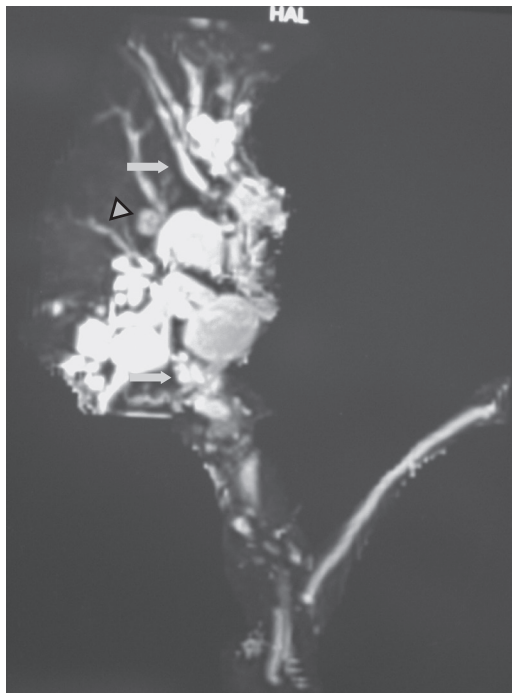


Figure 3 MRCP image shows mild dilation of intrahepatic biliary radicles (upper arrow), small cystic dilations communicating with bile ducts suggesting co-existent Caroli's disease (arrowhead) and non-communicating cysts near the porta compressing the proximal bile duct (lower arrow)

Discussion

Polycystic liver is arbitrarily defined when >20 hepatic cysts are present. The majority of cases occur in association with ADPKD. PCLD develops in 24% of ADPKD by the 3rd decade and in 80% by the 6th decade. Isolated PCLD accounts for less than seven percent of all PCLD based on autopsy series [3].

Both ADPKD and PCLD are autosomal dominant. Eighty five percent of ADPKD is due to mutation in *PKD1* gene which codes for polycystin1 whereas the remainder are due to *PKD2* gene mutation encoding polycystin 2. PCLD is caused by *PRKCSH* or *SEC63* mutations [4]. The protein product of these genes (hepatocystin and Sec63, respectively) act together to maintain proper topology and folding of integral membrane or secreted glycoproteins in the endoplasmic reticulum.

Liver cysts arise from malformation of the ductal plate during embryonic liver development. In PCLD, complexes of disconnected intralobular bile ductules, also termed Von Meyenburg complexes, are retained. These complexes can grow into cysts in adult life. In ADPKD and PCLD, liver cysts are scattered throughout the parenchyma, without connection to the biliary tree, which appears anatomically intact and without accompanying fibrosis. Caroli's disease is characterized by nonobstructive saccular or fusiform dilation of intrahepatic bile ducts associated with intrahepatic stone formation and recurrent bacterial cholangitis. Caroli's disease can be associated with autosomal recessive polycystic kidney disease or, rarely, autosomal dominant polycystic kidney disease [9]. By contrast, in Caroli's disease, liver cysts are connected to the biliary tree, which appear distorted and embedded in abundant fibrotic tissue.

PCLD is asymptomatic in more than eighty percent of cases [5] and diagnosis is often made incidentally. Symptoms occur due to mechanical effects of larger and more numerous cysts as in women, pregnancy, estrogen intake and renal failure. Massively enlarged liver may lead to epigastric pain, abdominal distension, early satiety, nausea, vomiting or shortness of breath. Severe abdominal pain may be experienced with rupture or infection of a cyst, bleeding into a cyst, or torsion of a pedunculated cyst. Obstructive jaundice is a rare complication, being described only in case reports. Portal hypertension is a rare complication either due to direct compression of hepatic veins or inferior vena cava by the cysts or due to coexisting congenital hepatic fibrosis.

The main aim of treatment of PCLD is to reduce symptoms by decreasing liver volume. Options include conservative management, invasive, or medical measures. Percutaneous aspiration and sclerosis of cysts is a feasible option in high risk patients and those with a large dominant cyst, but is associated with higher recurrence rates [6]. Surgical options include: laparoscopic fenestration and/or resection, open fenestration and/or resection, and liver transplantation. Medical treatment was initially attempted using somatostatin analogues. Cyst growth is maintained by cAMP dependent secretion of fluid by biliary epithelia. Somatostatin analogues

inhibit cAMP levels and may ultimately lead to shrinking of hepatic cysts [7]. Animal models of polycystic kidney disease showed upregulation of mTOR. A study using Sirolimus, an mTOR inhibitor for immunosuppression after renal transplant in ADPKD with PCLD achieved reduction in liver volume by 11.9% when given for an average of 19.4 months [8].

In conclusion, polycystic liver disease is a rare congenital disorder of cholangiocyte signalling. Co-existent Caroli's disease is a very rare association. Presentation with pruritus alone due to biliary obstruction is a rare manifestation. However, the majority of patients are asymptomatic and do not require any specific therapy.

References

1. D'Agata ID, Jonas MM, Perez-Atayde AR, et al. Combined cystic disease of the liver and kidney. *Semin Liver Dis* 1994;**14**:215-228.
2. Pirson Y, Lannoy N, Peters D, et al. Isolated polycystic liver disease as a distinct genetic disease, unlinked to polycystic kidney disease 1 and polycystic kidney disease 2. *Hepatology* 1996;**23**:249-252.
3. Kwok MK, Lewin KJ. Massive hepatomegaly in adult polycystic liver disease. *Am J Surg Pathol* 1988;**12**:321-324.
4. Waanders E, te Morsche RH, de Man RA, Jansen JB, Drenth JP. Extensive mutational analysis of PRKCSH and SEC63 broadens the spectrum of polycystic liver disease. *Hum Mutat* 2006;**27**:830.
5. Vauthey JN, Maddern GJ, Blumgart LH. Adult polycystic disease of the liver. *Br J Surg* 1991;**78**:524-527.
6. Andersson R, Jeppsson B, Lunderquist A, Bengmark S. Alcohol sclerotherapy of non-parasitic cysts of the liver. *Br J Surg* 1989;**76**:254-255.
7. Van Keimpema L, de Man RA, Drenth JP. Somatostatin analogues reduce liver volume in polycystic liver disease. *Gut* 2008;**57**:1338-1339.
8. Qian Q, Du H, King BE, et al. Sirolimus reduces polycystic liver volume in ADPKD patients. *J Am Soc Nephrol* 2008;**19**:631-638.
9. Gunay-Aygun M, Avner ED, Bacallao RL, et al. Autosomal recessive polycystic kidney disease and congenital hepatic fibrosis: summary statement of a first National Institutes of Health/Office of Rare Diseases conference. *J Pediatr* 2006;**149**:159-164.