

A path uncommonly traveled

Sreekanth Appasani, Jahangeer Basha, Kartar Singh, Rakesh Kochhar

Postgraduate Institute of Medical Education and Research, Chandigarh, India

A 48-year-old gentleman presented with abdominal pain for 1 year. He had undergone an abdominal surgery for recurrent abdominal pain 10 years back, details of which were not available. Clinical examination, blood chemistries and ultrasound were normal. He underwent esophagogastroduodenoscopy for evaluation of abdominal pain.

Endoscopic examination revealed evidence of gastrojejunostomy with normal afferent and efferent loops. However since the duodenum was also normal and no evidence of gastric outlet obstruction noted, the endoscope was further negotiated into the duodenum after shortening the loop in the stomach. The endoscope could be negotiated into proximal jejunum and the site of gastrojejunostomy could be reached. The present image (Fig. 1) shows the view through the gastrojejunostomy site. The single arrow in the left lower corner shows the GE junction while the double arrow shows the pyloric opening. The gastrojejunostomy site can be seen towards the right part of the image with tripe arrow pointing the opening of the efferent jejunal limb.

Gastrojejunostomy (Billroth II reconstruction) along with truncal vagotomy was a standard procedure for management of peptic ulcer disease in the pre - proton pump inhibitor era [1]. However this procedure was generally done for complicated peptic ulcer disease, especially with gastric outlet obstruction. Hence we rarely can traverse the normal duodenum to reach the gastrojejunostomy site. Our case presents a unique image since the gastric outlet along with duodenum was normal

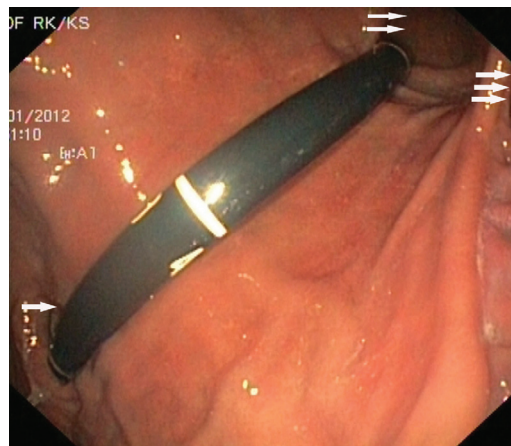


Figure 1 This endoscopic image depicts the view through the gastrojejunostomy site. The single arrow in the left lower corner shows the GE junction while the double arrow shows the pyloric opening and the triple arrow shows one of the gastrojejunostomy site openings

allowing us to reach the gastrojejunostomy site in jejunum, an area uncommonly seen on endoscopy.

Reference

1. Weil PH, Buchberger R. From Billroth to PCV: a century of gastric surgery. *World J Surg* 1999;23:736-742.

Department of Gastroenterology, Postgraduate Institute of Medical Education and Research, Chandigarh, India

Conflict of Interest: None

Correspondence to: Dr Sreekanth Appasani, Senior Research Associate, Department of Gastroenterology, Postgraduate Institute of Medical Education and Research, Chandigarh 160012, India, Tel.: +91 9781 122733 (mobile), +91 172 2756617 (office), Fax: +91 172 2744401, e-mail: drasreekanth@gmail.com

Received 24 February 2013; accepted 7 March 2013