

Synchronous gastric gastrointestinal stromal tumor (GIST) and other primary neoplasms of gastrointestinal tract: report of two cases

Ramneet Kaur^a, Sunita Bhalla^a, Samiran Nundy^b, Sunila Jain^a

Sir Ganga Ram Hospital, New Delhi, India

Abstract

Gastrointestinal stromal tumors (GIST) are the most common mesenchymal neoplasms of the gastrointestinal tract with a malignant potential. However, uncommonly they can be associated with synchronous tumors of different histogenesis. We herein report two cases of gastric GIST with synchronous tumors. The first case is of a 50-year-old male patient who was suspected with GIST of stomach and was incidentally found to have an associated duodenal neuroendocrine neoplasm. The second case is of a 62-year-old male who, while undergoing surgery for a primary colon adenocarcinoma, was incidentally detected to have a coexistent gastric GIST initially suspected to be a metastatic nodule. Coexistence of gastric GIST with neuroendocrine tumor is extremely rare. To the best of our knowledge this is the second case of gastric GIST coexisting with duodenal neuroendocrine tumor to be reported in the literature. Similarly, association of GIST with adenocarcinoma is uncommon. We herein analyze the pathological findings of two such cases, and we review the malignant potential of these synchronous tumors.

Keywords Gastrointestinal stromal tumor, adenocarcinoma, neuroendocrine tumor, synchronous tumors, gastric

Ann Gastroenterol 2013; 26 (4): 356-359

Introduction

Gastrointestinal stromal tumors (GIST) are the most common mesenchymal tumors of the gastrointestinal (GI) tract although accounting for only 0.1-3% of all GI neoplasms. These can arise anywhere along the GI tract. The synchronous occurrence of GIST and other primary GI malignancies is uncommon [1,2].

Case reports

Case 1

A 50-year-old male presented with history of two episodes of melena and drop in hemoglobin for 3 months. Barium meal study showed an eccentric rounded impression in the gastric

fundus. Additionally there was an eccentric impression on the superior wall of the duodenal bulb. Upper GI endoscopy revealed a nodular lesion in the gastric fundus with a central ulcer. Another sessile polyp of about 1 cm size was seen in the first part of duodenum (Fig. 1A, B). Both were thought to be leiomyomas endoscopically. Contrast-enhanced computed tomography (CT) of upper abdomen showed a large nodular lesion in the fundus of stomach and another small lesion in first part of duodenum.

Pathological examination

Wedge resection of gastric tumor and duodenal polypectomy was performed. Stomach showed a firm submucosal tumor measuring 4.5x3.5 cm. Overlying mucosa was focally ulcerated. Microscopically, the tumor was seen in the submucosa and wall and was composed of fascicles of spindle cells (Fig. 1C). Immunohistochemistry demonstrated positive staining for CD117 (Fig. 1D) and CD34. Tumor cells were negative for SMA and S100. Features were consistent with benign GIST (*American Joint Committee on Cancer*, pT2pN0pM0). Duodenal polyp showed a well circumscribed grey yellow nodule measuring 1 cm in diameter. Histology revealed a neuroendocrine tumor, grade 1 involving the duodenal wall (pT2pN0pM0). It was composed of nests and cords of round to oval tumor cells, separated by thin fibrous septae and was seen infiltrating the muscle (Fig. 1E). The cells had moderate

Department of ^aPathology (Ramneet Kaur, Sunita Bhalla, Sunila Jain); ^bGastrosurgery (Samiran Nundy), Sir Ganga Ram Hospital, New Delhi, India

Conflict of Interest: None

Correspondence to: Dr Sunila Jain, Dept of Pathology, Sir Ganga Ram Hospital, Rajinder Nagar New Delhi, 110060 India, Tel.: +91 4225 2134, 91 98711 57767, e-mail: s_isha19@rediffmail.com

Received 1 February 2013; accepted 17 February 2013

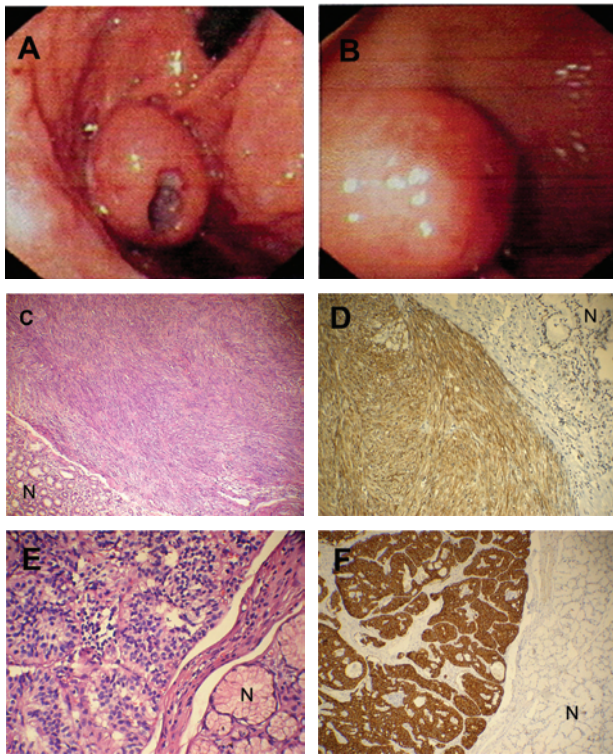


Figure 1 (A) Upper GI endoscopy showing a nodular lesion with smooth surface in the gastric fundus. A central ulcer is also seen. (B) A sessile polyp is seen in the first part of duodenum on endoscopy. (C) Low grade GIST with fascicles of spindle cells. (H&Ex10). Normal gastric mucosa (N) is seen. (D) CD117 positivity in the gastric GIST. Normal glands (N) are seen on the surface. (IHCx10). (E) Histology of duodenal polyp showing nests of neuroendocrine tumor on the left. Normal glands (N) are seen on the right. (H&Ex20). (F) Neuroendocrine tumor of duodenum showing strong positivity for Synaptophysin. Normal mucosa is negative (IHCx20)

amount of finely granular cytoplasm and small round nuclei with fine nucleoli. Mitotic count was less than 2/10 HPF and Ki-67 index was less than 3%. Immunohistochemistry showed strong staining for Synaptophysin confirming the neuroendocrine nature (Fig. 1F).

Case 2

A 62-year-old male was admitted with chief complaints of decrease in appetite and painful abdomen for two months. Colonoscopy revealed a large constricting mass in the recto-sigmoid colon. CT of the abdomen showed thickening of sigmoid colon and ileum with multiple mesenteric lymph nodes and heterogeneous nodular opacities in pelvis. The patient was taken up for surgery of advanced adenocarcinoma of colon. A nodule was found perioperatively in fundus of stomach which was thought to be metastatic in nature. In view of extensive spread with adhesions of small intestine, sigmoidectomy, right hemicolectomy along with wedge resection of stomach was done.

Pathological examination

Grossly, resected wedge of stomach showed a well circumscribed firm submucosal tumor (Fig. 2A) which microscopically was consistent with benign GIST (pT2pN0pM0) (Fig. 2B). Sigmoid colon showed an ulcero-infiltrative tumor measuring 3.5x2.5 cm. Right hemicolectomy also revealed extension of tumor into the ileum with multiple tumor nodules in the mesenteric and mesocolic fat (Fig. 2C). Microscopically, a moderately differentiated adenocarcinoma originating in the sigmoid colon with infiltration into serosal fat was seen (Fig. 2D), infiltrating the ileum. Multiple lymph nodes showed tumor metastasis along with metastatic omental deposits (pT4pN2pM1).

Discussion

GISTs are the commonest mesenchymal tumors of GI tract predominantly involving the stomach (50-62%), small intestine (20-30%), colon (11%) and the rectum (7%) [2]. They originate from interstitial, pacemaker Cajal cells. The percentage of GIST patients with other diagnosed neoplasms is reported to range between 3% and 33% [3]. It has not been ascertained whether the coexistence of a GIST with other unrelated syndromes or tumors is incidental or results from related pathophysiological processes [4]. The most common secondary neoplasms are GI carcinomas. Other coexistent tumors include lymphoma/leukemia, carcinomas of prostate, breast, kidney, lung, female genital tract, soft tissue and bone sarcomas, malignant melanoma and seminomas [5].

The pathological features of two cases of synchronous gastric GIST and synchronous neoplasms of GI tract are described (Table 1). The first case outlines a duodenal neuroendocrine tumor presenting as a polyp along with a coexistent gastric nodule diagnosed as benign GIST on histology. Synchronous GIST and neuroendocrine tumors of duodenum are extremely rare. Only 3 cases of concomitant gastric carcinoid and GIST have been reported in the literature [6,7]. Duodenal carcinoid may coexist with different types of cancer. Burke *et al* [8] studied 99 patients with duodenal carcinoids and found 28 patients with another malignancy. No GIST was however found coexisting with duodenal carcinoid. Cirillo reported association of gastric carcinoid and low risk GIST [7]. Pusiol *et al* [9] reported the first case of synchronous duodenal carcinoid and high-risk gastric GIST. In our study, which is the second case of duodenal neuroendocrine tumor with GIST, the GIST was of low grade. The second case is of a primary advanced colon adenocarcinoma and an incidentally detected gastric nodule that was initially suspected to be metastatic. This is an uncommon association [2] that can lead to diagnostic errors as the neoplasm is mistaken for a metastatic nodule particularly in a scenario of advanced carcinoma. The simultaneous appearance of GIST and another neoplasm in different parts of the GI tract is very rare. These patients have great diagnostic difficulties as the clinical features overlap.

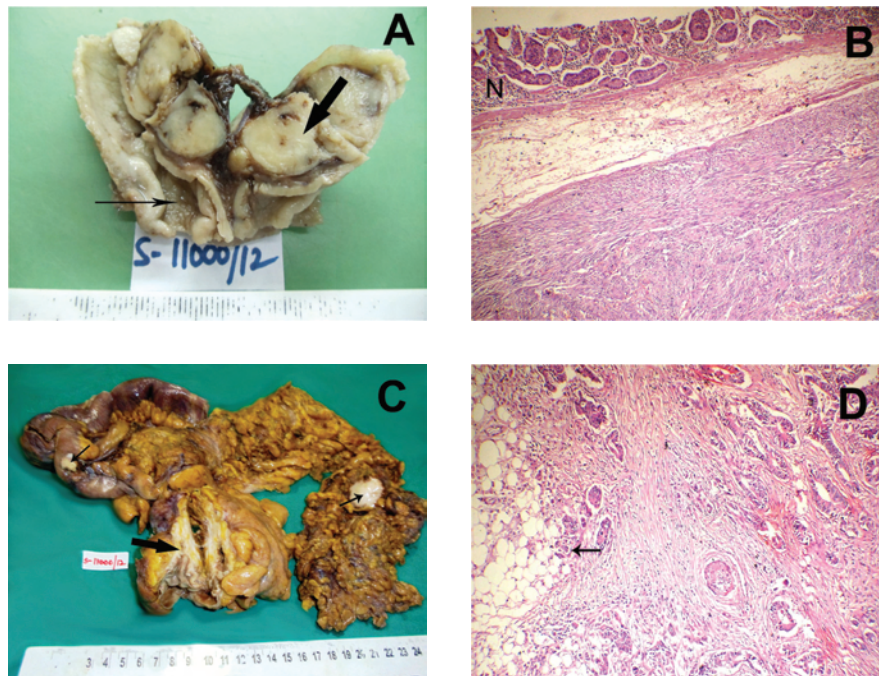


Figure 2 (A) Wedge resection of stomach showing a firm submucosal nodule in the wall (bold arrow). Normal gastric mucosa is seen (thin arrow). (B) Spindle cell tumor in the submucosa and wall. Mucosa (N) appears normal. (C) Large constricting growth in the sigmoid colon. (Bold arrow). Multiple metastatic deposits in the serosal fat. (Thin arrows). (D) Malignant glands infiltrating the wall and serosal fat

The etiology of synchronous occurrence of GISTs with histologically unrelated tumors still remains unclear. Some authors have postulated that they may share common carcinogenic pathways or genetic mutations with proliferation of different cell lines [10]. Given the limited number of cases of associated duodenal neuroendocrine tumors, the possibility of their sporadic occurrence is more likely. Further studies are needed to analyze the molecular and genetic mechanisms of carcinogenesis.

Awareness of occurrence and pattern of synchronous GIST and other neoplasms is important for both histopathologists and surgeons. The associated neoplasms may be both high-grade-like advanced colon carcinoma or low-grade-like well differentiated neuroendocrine tumor in this study. GIST itself can be of any grade. It may not always be possible to diagnose a coexisting tumor preoperatively. Surgeons should be alert to recognize a coexisting tumor before or during surgery and be prepared to modify the plan of surgery accordingly.

Table 1 Summary of histopathological features of two cases of gastric GISTs with synchronous tumors

Gastric GIST								Associated tumor			
Patient	Tumor size (cm)	Morphology of tumor	Nuclear pleomorphism	Mitotic index (per HPF)	Necrosis	Reactivity with CD117	Malignant potential	Location	Size (cm)	Type of tumor	
Case 1	4.5	Spindle cells arranged in bundles and fascicles.	mild	2/50	+	+	Very low	First part of duodenum	1	Neuroendocrine tumor, Grade 1	
Case 2	4.0	Interlacing bundles of spindle cells	mild	4/50	-	+	Very low	Sigmoid colon	3.5	Moderately differentiated adenocarcinoma pT4pN2pM1	

GIST, gastric gastrointestinal stromal tumor

References

1. Ferreira SS, Werutsky G, Marcelo GarciaToneto MG, et al. Synchronous gastrointestinal stromal tumours (GIST) and other primary cancers: Case series of a single institution experience. *Intern J Surg* 2010;**8**:314-317.
2. Nemes C, Rogojan L, Surdea-Blaga T, Seicean A, Dumitrascu DL, Ciuce C. Gastrointestinal stromal tumour (GIST) associated with synchronous colon adenocarcinoma - a case report. *J Gastrointest Liver Dis* 2012;**21**:101-103.
3. Liszka L, Zielińska-Pająk E, Paja J, Gołka D, Huszno J. Coexistence of gastrointestinal stromal tumours with other neoplasms. *J Gastroenterol* 2007; **42**:641-649.
4. Wei L, Xin WU, Ning W, Duo Y, Shu-lan Z. Gastrointestinal stromal tumour with synchronous isolated parenchymal splenic metastasis of ovarian cancer. *Chin Med J* 2011;**124**:4372-4375.
5. Agaimy A, Wunsch PH, Sobin LH, Lasota J, Miettinen M. Occurrence of other malignancies in patients with gastrointestinal stromal tumours. *Semin Diagn Pathol* 2006;**23**:120-129.
6. Lin YL, Wei CK, Chiang JK, Chou AL, Chen CW, Tseng CE. Concomitant gastric carcinoid and gastrointestinal, stromal tumours: a case report. *World J Gastroenterol* 2008;**14**:6100-6103.
7. Cirillo F. Neuroendocrine tumours and their association with rare tumours: observation of 4 cases. *Eur Rev Med Pharmacol Sci* 2010;**14**:577-588.
8. Burke AP, Sobin LH, Federspiel BH, Shekitka KM, Helwig EB. Carcinoid tumours of the duodenum. A clinicopathologic study of 99 cases. *Arch Pathol Lab Med* 1990;**114**:700-704.
9. Pusiol T, Zorzi MG, Morichetti G, Piscioi I, Scialpi M. Synchronous nonfunctional duodenal carcinoid and high risk gastrointestinal stromal tumour (GIST) of the stomach. *Europ Rev Med Pharmacol Sciences* 2011;**15**:583-585.
10. Shariq O, Odedra A, Alexopoulos A-S, Gould S, Soobrah R. Synchronous occurrence of gastrointestinal stromal tumour and ovarian neoplasm in a patient presenting with acute cholecystitis. *J Gastrointest Cancer* 2012;**43**:113-116.