

Trichotillomania with gastric trichobezoar

Shiran Shetty, Krishnaveni Janarathanan, Pavai Arunachalam

PSG Hospitals, PSG Institute of Medical Sciences & Research, Tamil Nadu, India

Bezoars are collections or concretions of indigestible foreign material in the gastrointestinal tract. Trichotillomania is an impetuous disorder of pulling out one's own hair, whereas trichobezoar is the formation of a hairball after trichophagia [1], which contains a large quantity of hair, varying in length, matted together.

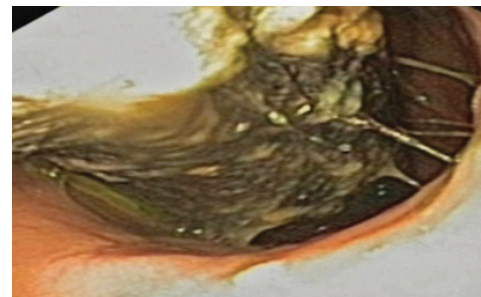
A 13-year-old patient presented with abdominal pain beginning 1 month ago. During this period the patient had reported pain intensity to be from mild to moderate and localized to epigastrium. The patient experienced non-projectile vomiting, containing undigested food particles.

General physical examination exposed patchy alopecia as shown in Fig. 1. Abdominal examination revealed an irregular and non-tender lump overlying a part of the epigastrium. An ultrasound of the abdomen showed an echogenic area with dense acoustic shadow in the stomach region. An upper gastrointestinal endoscopy was performed, revealing a large ball of hair in the body as well as pylorus of the stomach, as shown in Fig. 2A displaying the trichobezoar. Considering the size, the trichobezoar was removed laparoscopically (Fig. 2B) and the patient was referred to a psychiatrist for treatment of trichotillomania.

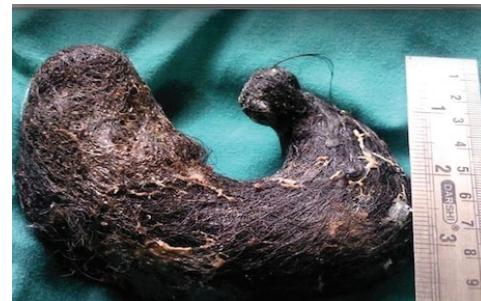Trichobezoar is the most common form of bezoars reported, with hairballs extending to the small intestine causing Rapunzel syndrome in a few cases. Trichophagia is equated to pica syndrome. Abdominal pain, anemia, and weight loss are the most common complaints. Evaluation involves ultrasonography, computed tomography and endoscopy. Endoscopic removal has been tried in few cases, however surgical elimination remains the preferred choice [2]. Treatment of trichotillomania is behavioral therapy. The importance and severity of trichotillomania should not be underrated and alertness of these disorders should be encouraged at primary health care level [3].



Figure 1 Patchy alopecia due to trichotillomania



A



B

Figure 2 (A) Endoscopy showing ball of hair in the stomach (B) Laparoscopically removed trichobezoar from stomach

Gastroenterology Department, PSG Hospitals, PSG Institute of Medical Sciences & Research, India

Conflict of Interest: None

Correspondence to: Shiran Shetty, Department of Gastroenterology, PSG Hospitals, PSG Institute of Medical Sciences & Research, Avinashi Road, Peelamedu, Coimbatore, Tamil Nadu, 641 004, India, Tel.: +91 422 257 0170, Fax: +91 422 259 4400, email: drshiran@gmail.com

Received 25 December 2012; accepted 6 January 2013

© 2013 Hellenic Society of Gastroenterology

References

1. O'Sullivan RL, Keuthen NJ, Christenson GA, Mansueto CS, Stein DJ, Swedo SE. Trichotillomania: behavioral symptom or clinical syndrome? *Am J Psychiatry* 1997;154:1442-1449 B.
2. Bhatia MS, Singhal PK, Rastogi V, Dhar NK, Nigam VR, Taneja SB. Clinical profile of trichotillomania. *J Indian Med Assoc* 1991;89:137-139.
3. Sharma NL, Sharma RC, Mahajan VK, Sharma RC, Chauhan D, Sharma AK. Trichotillomania and trichophagia leading to trichobezoar. *J Dermatol* 2000;27:24-26.

www.annalsgastro.gr