

Bilio-pancreatic endoscopic ultrasonography for diagnosis of biliary parasitosis

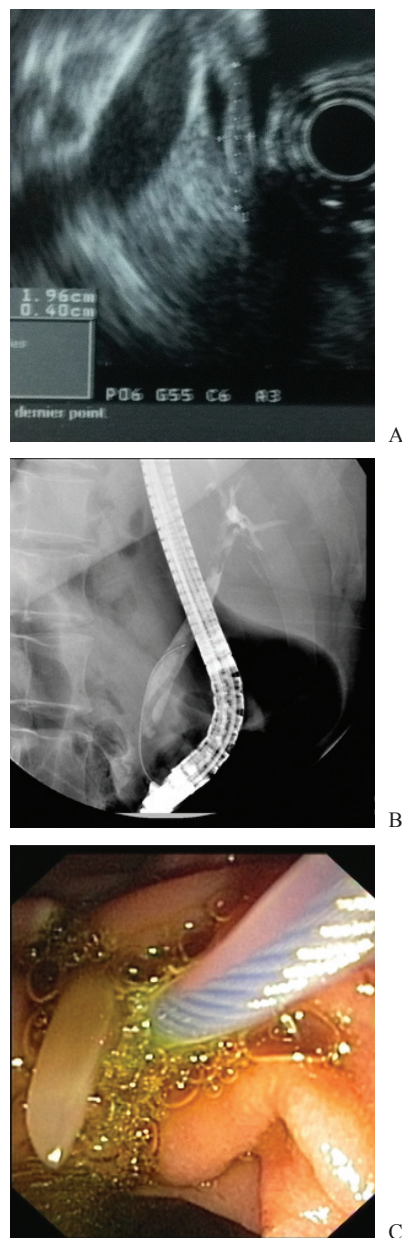
Gianfranco Donatelli, Bertrand Marie Vergeau, Thierry Tuszynski, Bruno Meduri

Hôpital Privé des Peupliers, Paris, France

A 48-year-old Portuguese woman was admitted at the emergency department for severe upper abdominal pain radiating to the back, without any sign of peritonitis. There was no history of drugs or ethanol abuse, pregnancy test was negative and she had not traveled to any other country in the last 5 years. Abdominal CT scan and laboratory tests were completely normal including blood counts. She was started on analgesics, but seeing no response, a diagnostic bilio-pancreatic endoscopic ultrasonography (EUS) was planned in order to rule out acute pancreatitis.

Trans-duodenal study showed an 8 mm dilated common bile duct (CBD) containing a long linear triple-layer structure (Fig. 1A), hyperechoic outside and hypoechoic inside, without acoustic shadow. Characteristics of *Ascaris lumbricoides* were recognized: two classical hyperechoic linear echogenic strips on either side of the longitudinal anechoic (lumen) of the ascaris [1]. Endoscopic retrograde cholangiography showed the linear filling defect due to the worm in CBD (Fig. 1B). Sphincterotomy was performed to retrieve a 15-cm long parasite with the help of a Dormia basket (Fig. 1C). In conclusion, bilio-pancreatic EUS may be helpful for diagnosis of upper abdominal pain if other investigations are negative, and triple linear hyper- hypo-hyperechoic tubular structure inside the CBD is a classical presentation of biliary parasitosis, that can be the cause of severe upper abdominal pain even without eosinophilia and travel to an endemic area.

Figure 1 (A) Echo-endoscopy showing dilated common bile duct containing a long linear triple-layer structure, two hyperechoic outside and one hypoechoic inside, without acoustic shadow characteristic of *Ascaris lumbricoides* (B) Endoscopic retrograde cholangiography showing the linear filling defect due to worm (C) Endoscopic view showing parasite coming out from papilla after the dormia basket is inserted in the common bile duct



Service d'Endoscopie Interventionnelle, Hôpital Privé des Peupliers, Paris, France

Conflict of Interest : None

Correspondence to: Gianfranco Donatelli, MD, Hôpital Privé des Peupliers, Service d'Endoscopie Interventionnelle, 8 Place Abbé G. Henocque, 75013, Paris, France, Tel.: +33 664 9500 70, Fax: +33 144 1652 12, e-mail: endoscopying@gmail.com

Received 13 October 2012 ; accepted 25 October 2012

Reference

1. Sharma M, Carg S. Endoscopic ultrasound for Ascariasis in common bile duct. *Endoscopy* 2009;41(Suppl 2): E209-E210.