

External migration of a percutaneous endoscopic gastrostomy tube through a gastrocutaneous fistula

Ahmed Hashim, Darren Arokianathan, Jessie Colquhoun, Giovanni Tritto

King George Hospital, Goodmayes, Greater London, UK

Complications of percutaneous endoscopic gastrostomy (PEG) tubes range from simple infections to deleterious effects of tube misplacement [1]. We present a unique case of external migration of a PEG tube through a pre-existing post-gastrostomy gastrocutaneous fistula.

A 66-year-old lady was admitted due to a leak around the PEG tube. Following failure of conservative measures, the tube was removed and the patient was fed through a naso-jejunal tube to facilitate healing of the resultant gastrocutaneous fistula. After 4 weeks, a new PEG tube with jejunal extension was inserted 3 cm proximal to the original site.

Two days later, the patient developed severe sepsis requiring aggressive resuscitation. Abdominal inspection revealed external projection of the 'J' extension from the abdominal wall through the old PEG site and endoscopy confirmed the unusual finding (Fig. 1A). Subsequently the "J" tube was repositioned into the second duodenum and clipped in place. Eventually an over-the-scope (OVESCO) clip was applied endoscopically to close the gastrocutaneous fistula and the leakage stopped (Fig. 1B).

This case reveals an unprecedented complication. Persistence of gastrocutaneous fistulas after removal of gastrostomy tubes is common, particularly when the tube had been in place for long periods. Spontaneous healing is the most frequent outcome [2]. The migration of a new feeding tube through the fistula has not been described before and, albeit very unlikely, should be taken into consideration. The OVESCO system is currently a recommended practice in management of non-spontaneously healing gastrocutaneous fistulas [3]. The early use of an OVESCO clip may prevent such complications.

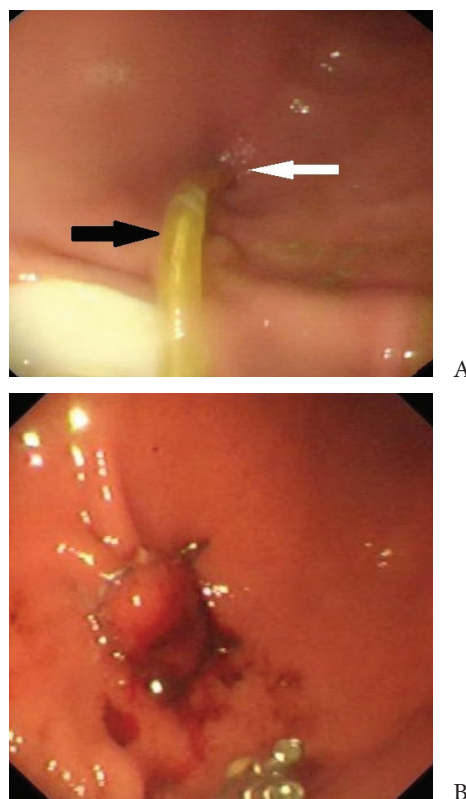


Figure 1 (A) Endoscopic appearance of the external migration and projection of the jejunal extension of the new percutaneous endoscopic gastrostomy (PEG) tube (black arrow) through the old PEG site (white arrow) (B) Over-the-scope clip successfully applied to close the old percutaneous endoscopic gastrostomy site (gastrocutaneous fistula) from the inside

References

- Schrag SP, Sharma R, Jaik NP, et al. Complications related to percutaneous endoscopic gastrostomy (PEG) tubes. A comprehensive clinical review. *J Gastrointest Liver Dis* 2007;**16**:407-418.
- Gordon JM, Langer JC. Gastrocutaneous fistula in children after removal of gastrostomy tube: incidence and predictive factors. *J Pediatr Surg* 1999;**34**:1345-1346.
- Kouklakis G, Zazos P, Liratzopoulos N, et al. Endoscopic treatment of a gastrocutaneous fistula using the over-the-scope-clip system: a case report. *Diagn Ther Endosc* 2011;**2011**:384143.

Gastroenterology Department, King George Hospital, Goodmayes, Greater London, UK

Conflict of Interest: None

Correspondence to: Giovanni Tritto, MD, Gastroenterology Department, King George Hospital, Barley Lane, Ilford, Essex, IG38YB, UK, Tel.: +44 208 9838000, Fax: +44 208 9708124, e-mail: giovanni.tritto@nhs.net

Received 11 October 2012; accepted 1 November 2012