

Achalasia cardia associated with esophageal varices: a therapeutic dilemma

Surinder Singh Rana^a, Deepak Kumar Bhasin^a, Chalapathi Rao^a, Rajiv Sarwal^b, Kartar Singh^a

Post Graduate Institute of Medical Education and Research (PGIMER); Sarwal Gastroenterology Centre, Chandigarh, India

Abstract

A 63-year-old male, chronic alcohol consumer, presented with progressively increasing dysphagia of 6 months duration. Upper gastrointestinal endoscopy revealed dilated esophagus with residue along with esophageal varices. Esophageal manometry revealed findings suggestive of classic achalasia cardia. Endoscopic ultrasound (EUS) examination revealed peri-esophageal collaterals as well as prominent perforators at lower end of esophagus. The co-existence of varices with achalasia is very rare and this case posed a difficult therapeutic dilemma as risk of bleeding from the varices limited the treatment options available. This case was successfully treated with EUS-guided botulinum toxin injection.

Keywords Achalasia cardia, endoscopic ultrasound, cirrhosis, varices

Ann Gastroenterol 2013; 26 (3): 258-260

Introduction

Achalasia cardia is a primary esophageal motility disorder causing dysphagia and the various treatment modalities available include medical therapy in the form of oral nitrates or calcium channel blockers, endoscopic pneumatic dilation, botulinum toxin injection or surgery [1]. The co-existence of portal hypertension & varices with achalasia cardia is very rare and poses a difficult therapeutic dilemma [2]. The risk of bleeding from the varices and the perforators along with compromised liver functions precludes surgery as well as endoscopic pneumatic dilatation and thus poses a therapeutic challenge to the treating clinician.

Case report

A 63-year-old male, chronic alcohol consumer, presented with progressively increasing dysphagia of 6 months duration. There was history of loss of weight. He was a known diabetic

with blood sugar well controlled with oral drugs. However, after onset of dysphagia, his blood sugar control was erratic and had frequent episodes of hypoglycemia. Clinical examination revealed hepatomegaly. Laboratory examination revealed hypoalbuminemia with mildly elevated liver enzymes. Upper gastrointestinal endoscopy revealed dilated esophagus with residue. Esophageal varices were also noted but there was no history of gastrointestinal bleed (Fig. 1). Esophageal manometry revealed high resting lower esophageal sphincter (LES) pressure with non transmitted low amplitude contractions in esophageal body (Fig. 2) suggesting classic achalasia cardia. A contrast-enhanced computed tomography of chest and abdomen revealed dilated esophagus enlarged liver with irregular outline and intra-abdominal collaterals. Endoscopic ultrasound (EUS) examination revealed peri-esophageal collaterals as well as prominent perforators at lower end of esophagus (Fig. 3). Patient was started on calcium channel blockers with no relief of symptoms. The co-existence of varices with achalasia is very rare and this case poses a difficult therapeutic dilemma as risk of bleeding from the varices limit the treatment options available. What to do next?

Because of risk of bleeding from varices following balloon dilatation, the patient underwent EUS-guided botulinum toxin injection. Using a linear echoendoscope with color Doppler, carefully avoiding varices and perforators, 80 units of botulinum toxin was injected into LES in four quadrants (20 units in each quadrant) (Fig. 4). Following this, the patient had marked improvement in his symptoms and was completely free of dysphagia 7 days later and also blood sugar was controlled with oral drugs. He is asymptomatic till the last follow up 3 months after injection. As the patient has chronic liver disease along with portal hypertension, he has been referred for work up for liver transplantation.

^aDepartment of Gastroenterology, Post Graduate Institute of Medical Education and Research -PGIMER (Surinder Singh Rana, Deepak Kumar Bhasin, Chalapathi Rao, Kartar Singh); ^bSarwal Gastroenterology Centre (Rajiv Sarwal), Chandigarh, India

Conflict of Interest: None

Correspondence to: Dr Surinder Singh Rana, Department of Gastroenterology, PGIMER, Chandigarh, 160 012 India, Tel.: +91 172 2749123, Fax: +91 172 2744401, e-mail: drsurinderrana@yahoo.co.in

Received 27 September 2012; accepted 19 October 2012

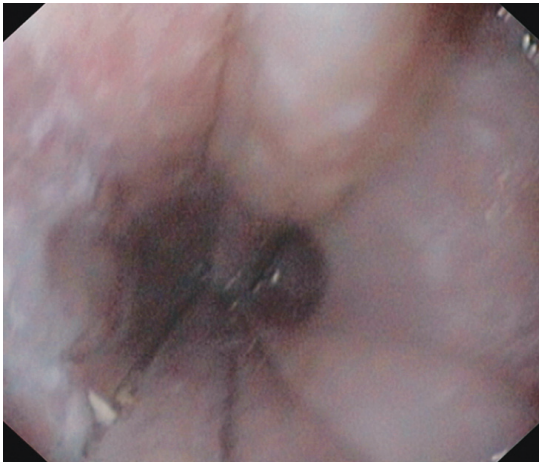


Figure 1 Upper gastrointestinal endoscopy: esophageal varices

Discussion

Achalasia cardia, a primary esophageal motility disorder, has been treated with oral nitrates or calcium channel blockers, endoscopic pneumatic dilation, botulinum toxin injection or surgery [1]. The co-existence of varices with achalasia is very rare and poses a difficult therapeutic dilemma as the risk of bleeding from the varices limits the treatment options available [2]. To decrease the risk of bleeding from esophageal varices, these patients can undergo eradication of esophageal varices first followed by pneumatic dilatation. Endoscopic band ligation or sclerotherapy can be employed for eradication of varices, but this takes time and also patients may develop esophageal scarring that may further worsen symptoms. Transjugular intrahepatic portosystemic shunt is also an attractive option for rapid eradication of varices and this can be followed by pneumatic dilatation [2]. Endoscopic

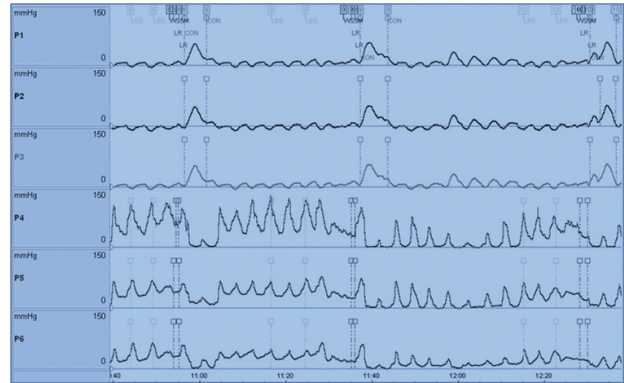


Figure 2 Manometry showing high resting lower esophageal sphincter (LES) pressure with partial transient LES relaxation (P4-P6) and non-transmitted low amplitude esophageal body contractions suggesting achalasia cardia

botulinum toxin injection improves symptoms in achalasia by inhibiting the release of acetylcholine that decreases the LES pressure [3,4].

Although endoscopic-guided inter-variceal botulinum toxin injection using a 25 F needle has been described as a treatment modality for patients with achalasia and portal hypertension [5], EUS-guided botulinum toxin injection is an attractive therapeutic option as it helps in accurately injecting the toxin in the muscularis propria. Also, EUS-guided injection can help avoid submucosal and peri-esophageal collaterals as well as perforators in this tricky situation and thus reduce the risk of bleeding as well as prevent inadvertent injection of toxin into the varices [3,4]. There are few reports in the published literature describing the successful use of EUS-guided botulinum toxin in patients with achalasia cardia and esophageal varices [3,4,6,7].

Although immediate success rates of endoscopic botuli-

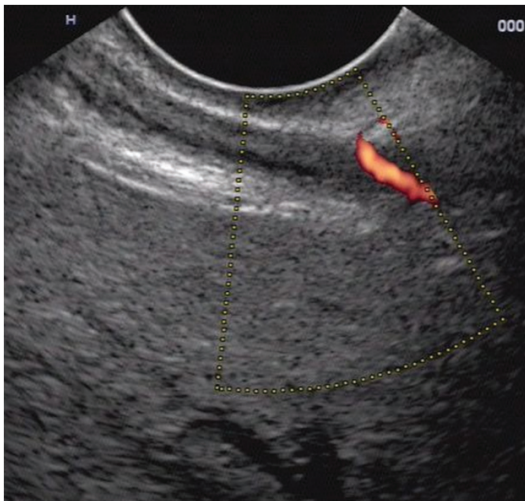


Figure 3 EUS: perforator vessel on power Doppler

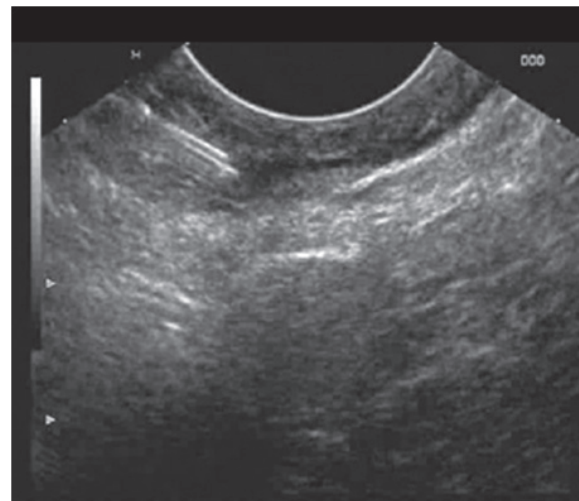


Figure 4 EUS-guided botulinum toxin injected in lower esophageal sphincter

num injection are good, the effect wanes off over time with less than 50% patients being symptom free one year after injection [1,8,9]. However, studies have shown that repeated injections of botulinum toxin may provide clinical relief in 60-85% patients at 2 years [9]. Age less than 50 years, vigorous achalasia, an initial clinical response to injection and decrease in LES pressure in response to injection have been shown to be factors that predict good response to botulinum toxin injection [9]. Our patient, who has shown a good response to botulinum toxin injection, is also planned for a repeat injection in case he has recurrence of symptoms.

In conclusion, the co-existence of varices with achalasia is very rare and this poses a difficult therapeutic dilemma, however, EUS-guided botulinum toxin injection is an attractive therapeutic option in these patients.

References

1. Campos GM, Vittinghoff E, Rabl C, et al. Endoscopic and surgical treatments for achalasia: a systematic review and meta-analysis. *Ann Surg* 2009;**249**:45-57.
2. Pinillos H, Legnani P, Schiano T. Achalasia in a patient with gastroesophageal varices: problematic treatment decisions. *Dig Dis Sci* 2006;**51**:31-33.
3. Hoffman BJ, Knappe WL, Bhutani MS, Verne GN, Hawes RH. Treatment of achalasia by injection of botulinum toxin under endoscopic ultrasound guidance. *Gastrointest Endosc* 1997;**45**:77-79.
4. Lozano-Lanagrán M, Lavín-Castejón I, Alcaín-Martínez G. Treatment of achalasia with botulinum toxin injection guided by endoscopic ultrasonography in a patient with esophageal varices. *Rev Esp Enferm Dig* 2011;**103**:663-664.
5. Dufour JF, Fawaz KA, Libby ED. Botulinum toxin injection for secondary achalasia with esophageal varices. *Gastrointest Endosc* 1997;**45**:191-193.
6. Maiorana A, Fiorentino E, Genova EG, Murata Y, Suzuki S. Echo-guided injection of botulinum toxin in patients with achalasia: initial experience. *Endoscopy* 1999;**31**:S3-S4.
7. Lakhtakia S, Monga A, Gupta R, et al. Achalasia cardia with esophageal varix managed with endoscopic ultrasound-guided botulinum toxin injection. *Indian J Gastroenterol* 2011;**30**:277-279.
8. Zaninotto G, Annese V, Costantini M, et al. Randomized control trial of botulinum toxin versus laparoscopic Heller myotomy for oesophageal achalasia. *Ann Surg* 2004;**239**:364-370.
9. Lake JM, Wong RK. Review article: the management of achalasia - a comparison of different treatment modalities. *Aliment Pharmacol Ther* 2006;**24**:909-918.