

# Precut sphincterotomy for selective biliary duct cannulation during endoscopic retrograde cholangiopancreatography

Tomas DaVee, Jairo A. Garcia, Todd H. Baron

Mayo Clinic, Rochester, Minnesota, USA

## Abstract

Selective biliary cannulation during endoscopic retrograde cholangiopancreatography (ERCP) is required to perform all therapeutic biliary procedures. Despite major advances in imaging, guidewires and sphincterotome catheter designs, the success rate for biliary cannulation by experienced endoscopists during ERCP is approximately 85% when standard cannulation techniques are applied. Precut sphincterotomy, also known as access sphincterotomy, is performed when standard techniques fail to achieve selective biliary cannulation. Precut sphincterotomy significantly increases the rate of biliary cannulation up to 98%. However, precut sphincterotomy has traditionally been considered a risk factor for adverse events following ERCP, especially concerning post-ERCP pancreatitis which results in significant morbidity and financial burden. Recent evidence suggests that precut sphincterotomy alone may not be a risk factor for pancreatitis; rather repeated attempts ( $\geq 10$ ) at biliary cannulation prior to precut sphincterotomy may be the actual cause of post-ERCP pancreatitis. In this paper, we review the different variations of the precut sphincterotomy technique and their corresponding rates of success and adverse events.

**Keywords** precut sphincterotomy, papillotomy, fistulotomy, needle-knife

*Ann Gastroenterol* 2012; 25 (4): 291-302

## Introduction and brief history of precut sphincterotomy

It has been more than half a century since McCune *et al* reported the first endoscopic cannulation of the major duodenal papilla in 1968 at George Washington University [1]. In 1974, the first successful cases of endoscopic biliary sphincterotomy were reported nearly simultaneously by Classen and Demling in Erlangen, Germany [2]; and by Kawai *et al* in Kyoto, Japan [2,3]. In both reports, impacted gallstones were removed, thereby transforming endoscopic retrograde cholangiopancreatography (ERCP) from a diagnostic to a therapeutic procedure, which would eventually become the preferred minimally invasive method for the treatment of pancreaticobiliary diseases. Despite improvements in endoscopes and imaging, which include multilumen flexible video endoscopes, high-definition wide screen displays,

guidewires and accessories, selective biliary cannulation (SBC) using standard techniques has not become uniform, and ranges from 80 to 95% depending on the experience of the endoscopist and the anatomy of the particular patient [4,5].

Precut sphincterotomy (PS), also referred to as access sphincterotomy, was initially developed in the late 1970s and early 1980s as a technique to improve successful biliary cannulation when standard techniques fail [6-8]. The basic technique for PS has evolved much since its introduction, and now includes three widespread techniques, with many variations and modifications of the procedure [5,9]. The decision to use one type of PS over another is based upon patient anatomy and endoscopist experience.

Osnes and Kahrs performed the first reported 'Precut' by creating what they called a choledocho-duodenostomy, with the use of a diathermy snare (Classen-Demling snare) to extend the size of pre-existing choledochoduodenal fistulae which then allowed spontaneous passage of common bile duct (CBD) stones [8]. Shortly thereafter in 1978, Caletti *et al*, performed the first precut fistulotomy (PF), when they created the first *de novo* choledochoduodenal fistulae in cases of difficult biliary cannulation [6].

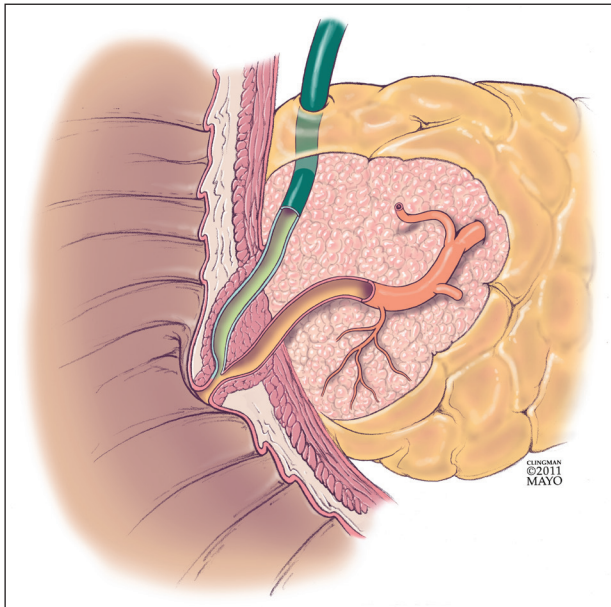
A 'Precut' is defined as an incision into the ampulla of Vater or CBD made *prior* to gaining SBC during ERCP, and is a technique used to *facilitate* SBC. The term 'Precut' appears to have been coined by Siegel in 1980, in the context of reporting the new method of precut papillotomy (PP) with the use of a sphincterotome [7]. During the procedure he

Division of Gastroenterology and Hepatology, Mayo Clinic, College of Medicine, Rochester, USA

Conflict of Interest: None

Correspondence to: Todd H. Baron, MD, FASGE, Division of Gastroenterology and Hepatology, Mayo Clinic, College of Medicine, 200 First Street South West, Rochester, MN, 55905, USA, Tel.: +1 507 284 2174, Fax: +1 507 255 7612, e-mail: baron.todd@mayo.edu

Received 26 May 2012; accepted 28 May 2012



**Figure 1** Normal anatomy of the major duodenal papilla

was unable to cannulate the CBD, however he began cutting into the duodenal papillary orifice *prior to*, and to *facilitate* cannulation of, the CBD.

'PS' has now come to signify a broad range of procedural techniques whereby a controlled surgical incision is created, with the goal of cannulating the CBD. There have been many subtle modifications with regard to the techniques and equipment by which PS is preformed [5,9]. However, a standardized classification and nomenclature system does not exist for PS, which has resulted in confusion among physicians and researchers as to the definition and actual performance of PS techniques. For example, some authors have used the terms 'sphincterotomy' or 'papillotomy' to describe what is actually the creation of a 'fistulotomy' (choledochoduodenal fistulotomy) which, by definition, avoids the papillary orifice, leaving the papillary sphincter at least partially intact.

We propose a classification of the types of PS to allow for standardization of the lexicon with which precut techniques are performed, to create a common nomenclature system to describe new modifications, and importantly to allow for accurate comparison of variations and modifications of the major techniques. In the case of normal anatomy (Fig. 1), all PS techniques fall into 3 broad types based upon the anatomy that is divided to reach the underlying ductal or ampullary system (Table 1). This nomenclature is constant regardless of the type of equipment used, and theoretically may be used in the rare event that the pancreatic duct (PD) is unable to be cannulated, but biliary cannulation is successful.

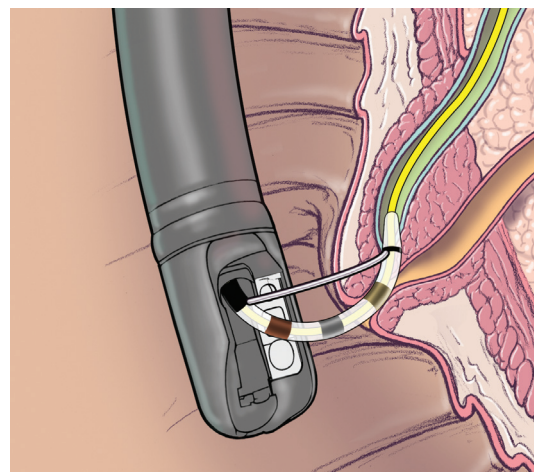
#### Standard technique for selective biliary cannulation

The most accepted standard technique (Fig. 2) for

achieving SBC during ERCP begins with placing the duodenoscope in the short axis position with the tip of the endoscope in the second portion of the duodenum. The ampulla of Vater is positioned in the left upper quadrant of the endoscopic view, orienting its long axis toward the right lower corner of the endoscopic field. Most endoscopists begin cannulation with an Erlangen-type sphincterotome, or a traction sphincterotome (also known as pull-type sphincterotome), which is preloaded with a guidewire to aid in cannulation of the CBD and to facilitate therapeutic procedures. The tip of the sphincterotome is engaged into the orifice of the major duodenal papilla, and is then slightly flexed so that it is aligned with the axis of the ampulla. As an adjunct contrast injection may be used to facilitate fluoroscopic visualization of the ductal anatomy. After initial superficial insertion of the sphincterotome, the guidewire is advanced into the bile duct and the sphincterotome is relaxed using an upward turning motion of the big wheel of the endoscope. Use of a guidewire to assist in attempting SBC has been shown in several studies to decrease the rate of adverse events such as post-ERCP pancreatitis (PEP) when compared to the use of contrast alone [25-27]. In a recent systematic review of 7 randomized controlled trials, which compared cannulation techniques using a guidewire versus contrast injection, the risk of PEP was significantly reduced when a guidewire was used (3.2% versus 8.7%; RR 0.38, 95% CI 0.19-0.76) [28].

When standard cannulation techniques fail, additional options exist with regard to the type of guidewire used. One such option is the use of a small angulated-tip hydrophilic guidewire, such as is commonly used for intravascular procedures. This specialized guidewire is used to probe the ampullary orifice and rotating it clockwise and counterclockwise to permit the guidewire to self-align with the bile duct. The use of a hydrophilic guidewire has been shown to increase the success of biliary cannulation up to 98% [5,29].

In the hands of experienced endoscopists, the time spent in attempting primary SBC with a wire-guided sphincterotome is approximately 5 min and requires only a few attempts. Difficult



**Figure 2** Standard ERCP technique for biliary cannulation

**Table 1** Mayo Clinic Precut Sphincterotomy Classification System

Precut Papillotomy (PP)	
Definition	Any endoscopic technique, regardless of the type of instrument used, that creates an incision into or from the papillary orifice; and/or excises part or all of the major papillary sphincter
Synonyms and Variations	Access Sphincterotomy [5,14], Access Papillotomy [5], Needle-Knife Sphincterotomy [11], Needle-Knife Papillotomy [15], Papillary Roof Incision [16], Erlangen Precut Papillotomy [17], Endoscopic Papillectomy [18], Scissor Precut Papillotomy [19], etc.
Precut Fistulotomy (PF)	
Definition	Any endoscopic technique, regardless of the type of instrument used, which creates of a choledochoduodenal fistula that avoids the orifice of the major duodenal papilla
Synonyms and Variations	Choledochoduodenostomy [6], Needle-Knife Fistulotomy [10], Needle-Knife Sphincterotomy, Precut Biliary Sphincterotomy [11], Suprapapillary Blunt Dissection [13], Suprapapillary Puncture [12], etc.
Transpancreatic Precut Sphincterotomy (TPS)	
Definition	Any endoscopic technique, regardless of the type of instrument used, that incises through the pancreatic tissue between the main pancreatic duct and the common bile duct
Synonyms and Variations	Pancreatic Sphincterotomy [5,20], Transpancreatic Papillary Septotomy, Transpancreatic Sphincter Precut, Transpancreatic Duct Precut [23], Pancreatic Sphincter Precutting [24], etc.

SBC is a subjective term, though has been defined by some as requiring more than 10 min and/or  $\geq 10$  attempts to achieve cannulation [30,31]. If the described steps fail to achieve selective cannulation of the CBD, experienced endoscopists often use PS. Prior to performance of PS additional options to attain SBC must be considered, to include: repeat attempts by the same endoscopist at a different session, repeat attempts by another endoscopist at the same or a different occasion, and percutaneous versus endoscopic ultrasound-guided biliary access.

In cases where biliary cannulation fails with the use of a guidewire, PD cannulation is often easily achieved [32]. In such cases, placement of a pancreatic stent may increase the biliary cannulation rate and obviate the need for PS [33,34]. After several unsuccessful attempts to achieve SBC with a guidewire, a soft plastic stent (generally 3-5 French, and 2-8 cm in length) is placed in the main PD to assist cannulation of the bile duct while reducing the risk of PEP [33,35-39].

Pancreatic stent placement to facilitate cannulation was evaluated in patients in who attempted SBC failed with the use of a guidewire. In a retrospective cohort study Cote *et al* reviewed the charts of 2,345 patients undergoing ERCP; 76 patients had native papilla in which traditional and guidewire-assisted approaches failed. Successful cannulation was achieved in 60/76 (78.9%). The authors then performed PS over the pancreatic stent in the remainder (n=16) which resulted in an overall success rate of 93.4% (71/76) while maintaining an overall PS rate of 19% (16/76) [33].

### Post-ERCP pancreatitis

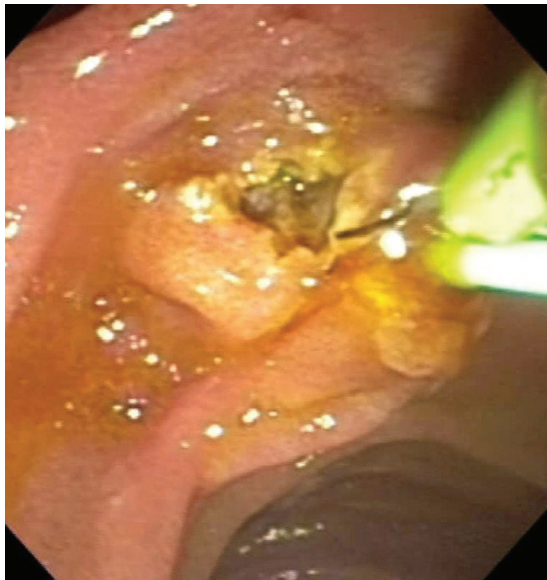PEP is the most common and serious complication of ERCP [40]. Since the consensus definitions by Cotton *et al* in 1991,

and revisions in 2010; PEP has been defined as the development of typical abdominal pain with amylase  $\geq 3X$  the upper limit of normal, and requiring unplanned hospital admission, or prolongation of admission by at least 1 day [41,42]. The development of PEP results in a significant increase in the global cost of care. Based on Medicare cost estimates in 2005, the cost of ERCP with PD stenting was \$1952 compared to \$5687 for the care of patients with PEP [43].

In a systematic review of 21 prospective studies, which included 16,885 patients undergoing both diagnostic and therapeutic ERCP, Andriulli *et al* found the overall rate of PEP was 3.5%, with a corresponding mortality rate of 0.8% [44]. Patients who are considered to be high-risk for development of PEP were identified in a meta-analysis by Macsi *et al* as patients with suspected sphincter of Oddi dysfunction (RR 4.09, 95% CI 3.37-4.96;  $P < 0.001$ ), female gender (RR 2.23, 95% CI 1.75-2.84;  $P < 0.001$ ), and those with a previous history of pancreatitis (RR 2.46, 95% CI 1.93-3.12;  $P < 0.001$ ); additional procedure-related risk factors for PEP were PS (RR 2.71, 95% CI 2.02-3.63;  $P < 0.001$ ) and pancreatic injection (RR 2.2, 95% CI 1.6-3.01;  $P < 0.001$ ) [37].

In a randomized controlled trial involving 70 patients, Ito *et al* demonstrated a significant reduction in the rate of PEP from 23% to 2.9% with the use of PD stents [39]. In a meta-analysis of five controlled trials involving 481 patients Singh and colleagues demonstrated that the use of pancreatic stents reduced the incidence of PEP in high-risk patients from 15.5% to 5.8%; furthermore, the study determined that pancreatic stent placement was successful in 93% of patients [38]. Some endoscopists prefer to remove the internal flange of the pancreatic stent to enable its spontaneous passage following the procedure [45]. Once a pancreatic stent is properly placed, the endoscopist may repeat attempts to cannulate the CBD. If further attempts at SBC are unsuccessful, PS may be performed (Fig. 3).





**Figure 3** Precut fistulotomy with the aid of a pancreatic duct stent

### Precut sphincterotomy techniques

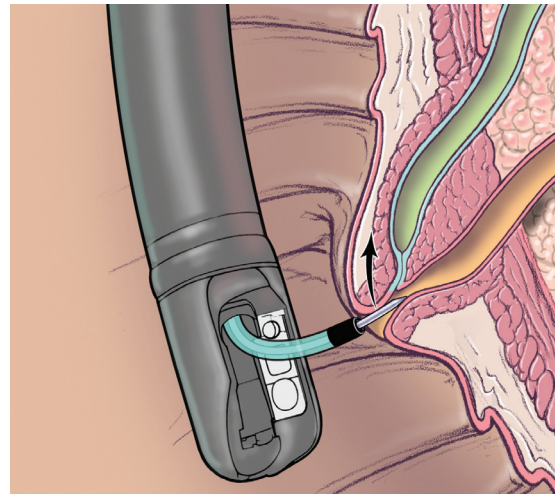
The use of PS access techniques requires an understanding of the anatomy of the biliary and pancreatic ductal system. No consensus exists about the optimal alternative procedure in cases of failed biliary cannulation using standard techniques [13]. As such, there have been multiple PS techniques described, and many variations and modifications to these techniques. The most common PS techniques that are performed are the PP, PF and the transpancreatic PS (TPS) [5,11,40].

#### Precut papillotomy

PP is performed, most commonly, by using a needle-knife (Fig. 4) to carefully dissect the major duodenal papilla in a layer-by-layer fashion to directly visualize and cannulate the CBD. The endoscopist initiates the papillotomy by placing the needle-knife at upper portion of the papillary orifice, near the 12 o'clock position, and initiates the cut upwards from the orifice, or downwards through the papillary sphincter. The incision is extended by cutting in 1-2 mm increments with short-pulses of cutting current (usually with a controlled generator) to de-roof the common biliary duct orifice [46]. Once the biliary sphincter muscle is exposed (it is identified by its whitish, onion-skin appearance) the papilla may be cannulated or the biliary sphincter may be transected, followed by cannulation of the CBD.

#### Precut fistulotomy

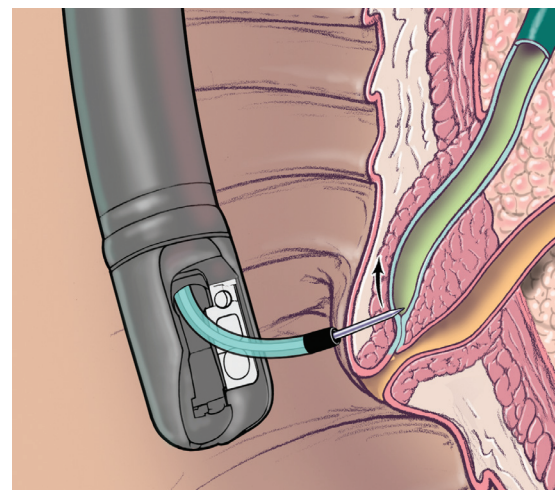
An alternative method to perform a precut is via PF (Fig. 5). This technique commonly employs a needle-knife to create an incision at the level of the intraduodenal segment of the



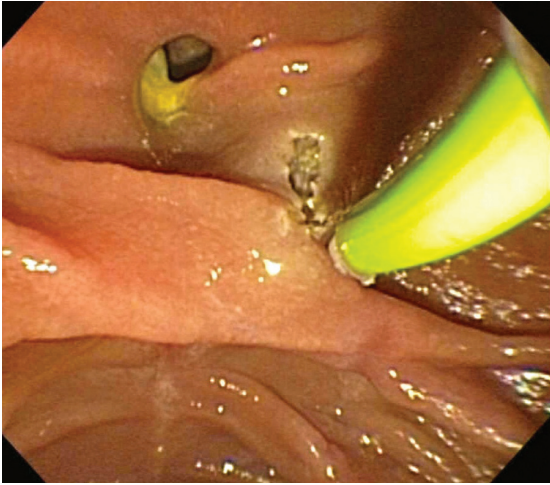
**Figure 4** Precut papillotomy

CBD, which runs proximal to the major duodenal papilla. The incision is begun above the papillary orifice, is then extended either upward in the cephalic direction, or downward toward the papillary orifice. This approach leaves the papillary orifice intact and creates a fistulotomy for direct visualization of the CBD and facilitates SBC (Fig. 6). The success rate of biliary cannulation using the PF technique is up to 98% [5].

After performing PP or PF, a guidewire may be passed into the biliary duct, then additional extensions of the incision can be made by using a standard sphincterotome. Extension of the incision may be especially useful for removal of large bile duct stones ( $\geq 15$  mm). In addition or alternatively, the sphincterotomy/fistulotomy tract may be dilated with a large diameter balloon, which is matched to the size of the stone and/or the diameter of the proximally dilated bile duct. Endoscopic papillary large balloon dilation following PS has been shown to be safe and effective [47].



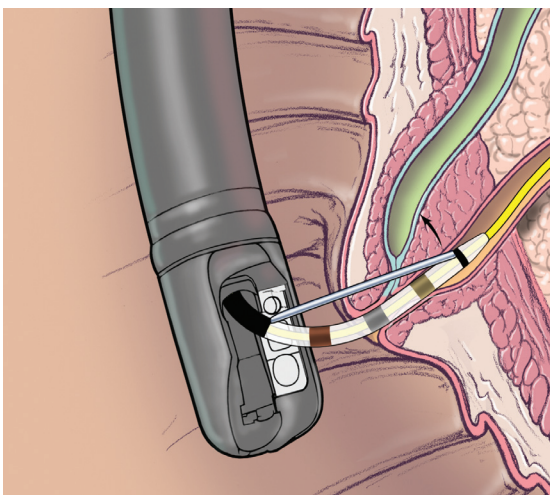
**Figure 5** Precut fistulotomy



**Figure 6** Precut fistulotomy. The major duodenal papilla is visible below the prominent mucosal fold. A peri-ampullary diverticula is present in the left upper corner

### Transpancreatic precut sphincterotomy

The TPS technique (Fig. 7) was first reported in 1995 by Goff as a technique that may be performed after attempts at SBC have led to guidewire passage into the PD [22-24]. The TPS technique uses a standard “traction-type” sphincterotome, which is oriented in the direction of the CBD at approximately the 11 o’clock position, and is then inserted superficially into the PD. The incision is then made to expose the bile duct orifice or the bile duct itself. Once the pancreatic sphincter and major duodenal papilla are cut, biliary cannulation may be re-attempted [22,48,49]. The potential advantages of the TPS include: it is not necessary to exchange the sphincterotome for a needle-knife device; and the depth of incision is more easily controlled, thus the



**Figure 7** Transpancreatic precut sphincterotomy

risk of perforation is theoretically lower [50]. The use of a PD stent after TPS has been shown to reduce the incidence of PEP [51].

### Additional variations of precut sphincterotomy

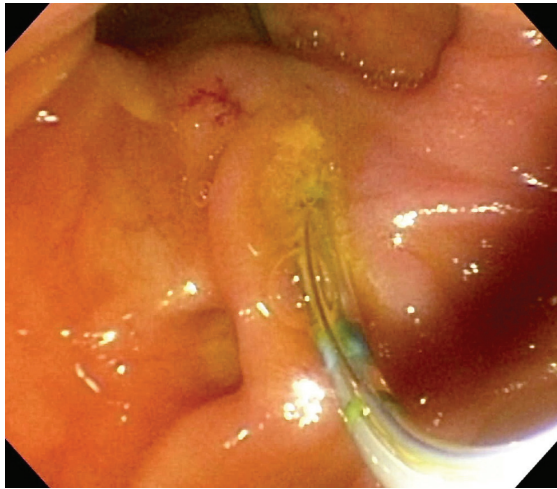
The Erlangen PP (EPP), also known as Papillary Roof Incision, is a subtype of the PP technique that takes its name from the ‘birthplace’ of endoscopic sphincterotomy in Erlangen, Germany [52]. Instead of using a needle-knife to incise the papillary sphincter, the papillotomy is performed using an Erlangen-type sphincterotome which lacks a “nose” such that the cutting wire extends to the tip of the sphincterotome [5,16,17,52]. The procedure was pioneered by Soehendra and colleagues, who performed a randomized control trial comparing outcomes in 146 patients who underwent conventional sphincterotomy with use of a guidewire (CSG) versus 145 patients who underwent primary EPP [53]. The authors found that biliary cannulation failed in 42 patients (28.8%) in the CSG group, after which secondary EPP was successful in 41 of these patients, leading to an overall success rate of 99.3%. Most notably, the success rate using primary EPP was 100% at the first attempt, and cannulation was achieved 1.4 min faster than in the CSG group ( $P < 0.001$ ;  $6.9 \pm 1.8$  min versus  $8.3 \pm 2.1$  min). The adverse event rates in both groups were similar, including the incidence and severity of pancreatitis (2.9% CS group vs. 2.1% EPP group;  $P > 0.05$ ). None of the study patients developed severe hemorrhage, pancreatitis or perforation leading the authors to conclude that primary precut using EPP was possibly faster and at least as safe and successful as CSG.

Intramural incision, initially described by Burdick *et al*, is a PP variation that may be useful when standard attempts at SBC with a guidewire have led to the creation of a false tract through the intraduodenal segment of the bile duct (Fig. 8) [54]. This pseudo-tract is then incised with the sphincterotome (Fig. 9), or with a needle-knife, thereby unroofing and exposing the bile duct and allows for direct visualization of both the pancreatic and biliary sphincters [55,56]. Intramural Incision makes use of an otherwise unplanned event to gain biliary or PD access, or to retrieve fractured stents [57,58].

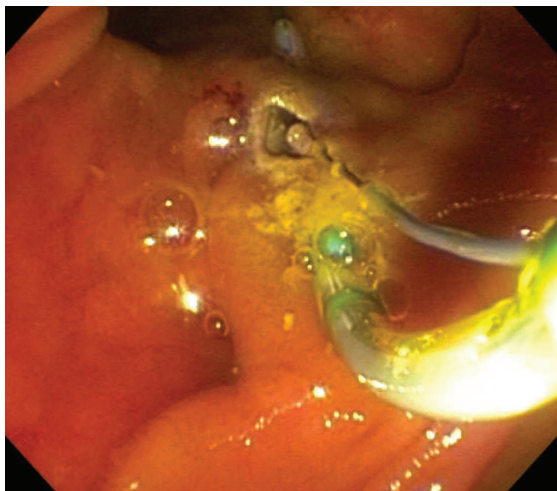
Supra-Papillary Puncture is an evolving subtype of PF [6,12]. This technique creates direct duodenocholedochal access with the use of a specialized catheter fitted with a needle to directly puncture the biliary duct under fluoroscopic guidance, without the use of cautery. Data on the technique are thus far limited; however it may offer a reduced rate of PEP but potentially a higher rate of perforation [59-61]. Endoscopic ultrasound may be a useful adjunct in lowering the rate of adverse events using this technique [62,63].

Supra-Papillary Blunt Dissection is another PF subtype that is similar to Supra-Papillary Puncture. This technique utilizes a cotton “peanut” to bluntly dissect the supra-papillary mucosa and allows for direct visualization and puncture of the CBD [13].





**Figure 8** Precut papillotomy via intramural incision. The guidewire is noted to have inadvertently passed through the mucosa of the intraluminal portion of the major duodenal papilla. Incision of the mucosa using the sphincterotome will follow



**Figure 9** Precut papillotomy via the intramural incision. The sphincterotome is used to incise the intraluminal portion of the major duodenal papilla following the guidewire's path

### Comparing timing and techniques

Regardless of the technique used, historically PS has been considered as a high-risk, technically difficult procedure, which should only be performed by very experienced endoscopists [4,74,75]. There have been many studies that report or evaluate the success and complications associated with PS. For direct comparison of the data from selected major PS studies, please see Table 2.

Recent data suggest that PS is a safe, timesaving and effective technique [30,31,64]. Some have suggested that endoscopists should have completed at least 200 diagnostic ERCPs under supervision, with SBC rates of 80-85% before performing endoscopic biliary sphincterotomy [76,77]. The number of ERCPs

that one should perform before attempting PS is unknown. Based upon data accumulated by one endoscopist, it appears despite a decrease in need to perform PS to obtain cannulation, as well as an increase in success rate of PS, the adverse event rate remains stable with increasing experience [4]. This suggests there is an inherent risk of PS that cannot be eliminated.

As previously mentioned, there have been several publications showing that PS is an independent risk factor for adverse events following ERCP such as PEP, cholangitis, perforation and bleeding [78-80]. On the other hand, the precut technique itself may not be responsible for adverse events, but higher rates of adverse events may be due to using it as a last resort after prolonged attempts at biliary cannulation [10,30,81,82]. Adverse events following PS may be the result of use of cautery and/or trauma from excessive manipulation/repeated cannulation attempts which is thought to impair drainage of the pancreas as a result of papillary edema [40,75,82]. Further, perforation of PD side branches from passage of guidewires and/or overfilling of the PD may also result in pancreatitis [69,80].

### Precut sphincterotomy versus standard cannulation techniques

Few studies have directly compared PS versus standard cannulation techniques, the PS data from selected studies are presented in Table 2. In a meta-analysis of six prospective, randomized controlled trials that included 959 patients, Gong *et al* attempted to establish the efficacy and safety of PS (using both PP and PF techniques) when compared to conventional biliary cannulation techniques [83]. The main outcomes assessed were rates of successful biliary cannulation and adverse events. The pooled analysis showed a trend toward higher rates of SBC with the use of PS (89.3% versus 78.1%), however this trend was not statistically significant for successful primary biliary cannulation with PS [OR 2.05 (95% CI 0.64-6.63)]. In addition the use of precut significantly reduced the risk of PEP (RR) of 0.46 (95% CI: 0.23-0.92) compared to standard techniques. By maintaining pancreatic flow using small diameter prophylactic PD stents, the risk of PEP can be decreased, especially with regard to the risk of severe PEP [20,84-88].

In a prospective study of 116 patients undergoing ERCP the efficacy of TPS to obtain biliary access after standard methods had failed was compared to conventional biliary sphincterotomy [71]. Immediate biliary access after TPS was achieved in 85% of cases; adverse events occurred in 12%, consisting of post-sphincterotomy bleeding in 2.6%, PEP in 8%, and retroperitoneal perforation in 1.7%, the latter of which were managed conservatively. The authors found that the amount of time between completing the PS and obtaining initial biliary access was the most important factor associated with successful biliary cannulation.

### Precut papillotomy versus precut fistulotomy

There are little comparative data on the efficacy and safety of PP and PF, the two most widely used PS techniques (Table 3).

Table 2 Selected Precut Technique Studies

	First Author	Study Type	Year	Study Location	Precut Timing/ Technique	Total ERCP Patients (n)	Successful ERCP (n) - Including Precut Cases	Overall ERCP Success Rate (%)	Precut Patients (n)	Precut Successful SBC (n)	Precut Success Rate (%)	Pancr- atitis (n)	Perfo- ration (n)	Hem- or- rhage (n)	Chol- angitis (n)	Overall Adverse Events (n)	Overall Adverse Event Rate (%)	Use of Pancreatic Duct Stents (Y/N)
Precut Papil- lotomy (PP) [27,64-67]	Tang S	Prospective Randomized Trial	2005	St. Michael's Hospital, Toronto, Canada	After 12 minutes	642	639	99.5%	32	31	96.9%	2	0	1	1	4	12.50%	N
	Figueroa F	Prospective Co- hort Study	2009	University of the State of Rio de Janeiro, Rio de Janeiro, Brazil	After 10-15 minutes	146	139	95.2%	43	36	83.7%	2	1	3	1	7	16.28%	N
	Bailey A	Prospective Co- hort Study	2010	Westmead Hospital, Sydney, Australia	After 10 minutes, or immediately if other techniques were deemed likely to fail	732	717	98.0%	94	80	85.1%	14	0	0	n/a	14	14.89%	Y (n=22)
	Fukatsu H	Retrospective Cohort Study	2007	Okayama University Hospital, Okayama, Japan	After 20 minutes	501	497	99.2%	80	76	95.0%	9	0	0	n/a	9	11.25%	N
	Ang T	Retrospective Cohort Study	2010	Changi General Hospi- tal, Singapore	Based on Study Cri- teria for Early Precut	765	764	99.9%	55	54	98.2%	1	0	0	0	1	1.82%	Y (n=un- known)
Precut Fistu- lotomy (PF) [4,30,68-70]	Khatib- ian M	Prospective Randomized Trial	2008	Shariati Hospital, Teh- ran, Iran	Standard ERCP tech- niques vs Immediate NKF	218	216	99.1%	106	105	99.1%	2	1	0	0	3	2.83%	N
	Manes G	Prospective Randomized Trial	2009	Multicenter Study at Four Hospitals in Italy	After 10 minutes	1654	n/a	n/a	77	71	92.2%	2	0	5	n/a	7	9.09%	N
	Lee TH	Prospective Clinical Trial	2011	Multicenter Study at Two Hospitals in South Korea	After 10 minutes, or after 5 unintentional PD cannulations	n/a	n/a	n/a	159	149	93.7%	9	1	6	n/a	16	10.06%	N
	Kasim F	Prospective Co- hort Study	1996	Beth Israel Medical Center, New York, New York	After 9-12 attempts	389	n/a	n/a	72	67	93.1%	3	3	0	0	9	12.50%	N
	Harewood G	Prospective Co- hort Study	2002	Mayo Clinic, Rochester, Minnesota	After no more than 20 minutes	2385	n/a	n/a	253	233	92.1%	28	0	5	n/a	38	15.02%	N
Transpancreatic Precut Sphinc- terotomy (TPS) [22,24,49,50,71,72]	Kahaleh M	Prospective Case Control Study	2004	University of Virginia Health System, Charlot- tesville, Virginia	After 3 opacifications of the pancreatic duct	2285	n/a	n/a	116	116	100.0%	9	2	3	0	14	12.07%	Y (n=29)
	Goff J	Retrospective Cohort Study	1999	University of Colorado Health Sciences Center, Denver, Colorado	Physician dependent	200	199	99.5%	51	50	98.0%	0	1	0	0	1	1.96%	N
	Akashi R	Retrospective Cohort Study	2004	Kumamoto Regional Medical Center, Ku- mamoto, Japan	Physician dependent	1942	1933	99.5%	172	163	94.8%	10	0	2	5	17	9.88%	N
	Kapetanios D	Retrospective Cohort Study	2007	George Papanikolaou Hospital, Thessaloniki, Greece	After > 10 attempts	306	250	81.7%	40	30	75.0%	1	0	1	n/a	2	5.00%	N
	Halttunen J	Retrospective Cohort Study	2008	Helsinki University Central Hospital, Helsinki, Finland	Physician dependent	6209	n/a	n/a	262	255	97.3%	23	n/a	4	n/a	27	10.31%	Y (n=6)
	Weber A	Retrospective Cohort Study	2008	Technical University of Munich, Munich, Germany	After > 30 minutes, and/or > 3 pancreatic duct cannulations	n/a	n/a	n/a	108	103	95.4%	6	0	6	0	12	11.11%	Y (n=103)

Note: To aid the reader, the data are presented in color-coded format with the strongest type of study listed first (i.e. randomized trials are listed before prospective studies)

**Table 3** Comparison of Precut Techniques [10,11,21,89]

First Author	Year	Study Type	Study Location	Precut Timing / Technique	Total ERCP Patients (n)	Successful ERCP (n) - Including Precut Cases	Overall ERCP Success Rate (%)	Precut Patients (n)	Precut-assisted Successful SBC (n)	Precut Success Rate (%)	Pancreatitis (n)	Perforation (n)	Hemorrhage (n)	Cholangitis (n)	Overall Adverse Events (n)	Overall Adverse Event Rate (%)	Use of Pancreatic Duct Stents (Y/N)
Abu-Hamda E	2005	Retrospective Cohort Study	Mayo Clinic, Rochester, Minnesota	PF Group A: Pure cutting current and occasional PD stenting	n/a	n/a	n/a	44	44	100,0%	0	0	1	n/a	1	2,27%	Y (n=6)
				PP Group B: Blended current and no PD stenting	n/a	n/a	n/a	47	46	97,9%	6	0	0	n/a	6	12,77%	N
				PP Group C: Pure cutting current and frequent PD stenting	n/a	n/a	n/a	48	43	89,6%	3	2	2	n/a	6	12,50%	Y (n=15)
Mavrogiannis C	1999	Prospective Randomized Trial	Hippokraton Hospital of Athens, University of Athens, Greece	PF Group - After 35 minutes, or 5 unintentional PD cannulations	772	n/a	n/a	74	67	90,5%	0	2	5	1	8	10,81%	N
				PP Group - After 35 minutes, or 5 unintentional PD cannulations	n/a	n/a	n/a	79	70	88,6%	6	2	4	0	12	15,19%	N
Wang P	2010	Retrospective Analysis of Prospective Cohort Data	Multicenter Study at Nine Hospitals in China	TPS Group - Timing and Technique were Physician Determined	3178	n/a	n/a	140	126	90,0%	16	0	2	2	20	14,29%	Y (n=26)
				PP Group - Timing and Technique were Physician Determined	n/a	n/a	n/a	76	69	90,8%	9	1	3	2	14	18,42%	Y (n=2)
Catalano M	2004	Prospective Randomized Trial	St. Luke's Medical Center, Milwaukee, Wisconsin	TPS Group - Timing was Physician Determined	4463	n/a	n/a	29	29	100,0%	n/a	n/a	n/a	n/a	1	3,45%	N
				PP Group - Timing was Physician Determined	n/a	n/a	n/a	34	24	70,6%	n/a	n/a	n/a	n/a	6	17,65%	Y (n=21)



Table 4 Comparison of Precut Timing [31,73]

First Author	Year	Study Type	Study Location	Precut Timing / Technique	Total ERCP Patients (n)	Successful ERCP - Including Precut Cases (n)	Overall ERCP Success Rate (%)	Precut Patients (n)	Precut Successful SBC (n)	Precut Success Rate (%)	Pancreatitis (n)	Perforation (n)	Hemorrhage (n)	Cholangitis (n)	Overall Adverse Events (n)	Overall Adverse Event Rate (%)	Use of Pancreatic Duct Stents (Y/N)
Cennamo V	2009	Prospective Randomized Trial	Bellaria-Maggiore Hospital, Bologna, Italy	Immediate PP	n/a	n/a	n/a	36	33	91.7%	0	1	0	3	8.33%	N	
				PP after 20 minutes	n/a	n/a	n/a	32	26	81.3%	0	0	0	0	0.00%	N	
Testoni P	2011	Retrospective Cohort Study	Vita-Salute San Raffaele University, Milan, Italy	PF when performed within 10 attempts	1703	1636	96.1%	121	118	97.5%	4	n/a	n/a	n/a	n/a	n/a	Y (n=4)
				PF when performed after >10 attempts	131	81	61.8%	49	43	87.8%	7	n/a	n/a	n/a	n/a	n/a	Y (n=2)
				Timing of PF was physician and case dependent**	2004	1878	93.7%	170	161	94.7%	11	n/a	n/a	n/a	n/a	n/a	Y (n=6)

Note:\*\*Combined data from both arms of the study are presented in this row

In a randomized comparative study of 153 patients with suspected choledocholithiasis, Mavrogiannis *et al* compared patients who underwent PF (n=74) to patients who underwent PP (n=79) [10]. Their analysis determined that patients who underwent PF had a reduced incidence of PEP with respective rates of 0% versus 7.59% with PP (P <0.05).

In a retrospective cohort study of patients undergoing ERCP at Mayo Clinic, Rochester the outcomes of 139 consecutive patients were assessed [11]. The same endoscopist performed the precut technique used in each of three groups. Forty-four patients underwent PF with occasional PD stenting (6 of 44), 47 patients received PP without PD stenting, and 48 patients received PP with frequent PD stenting (15 of 48). The success rate of each type of PS was 95.5%, 95.7%, and 89.6% respectively at initial ERCP, and 100%, 97.8%, and 95.6% after a second ERCP. A non-significant trend toward a lower incidence of PEP occurred in the PF group compared with the PP techniques (0%, 6% and 3%). The finding that PF may reduce the risk of PEP could be due to the fact that fistulotomy technique avoids the papillary orifice, whereas PP causes trauma and cautery effect/edema to the pancreatic orifice, which may result in subsequent poor drainage of the pancreas. As stated previously, the latter can be prevented with placement of a prophylactic PD stent.

#### Transpancreatic precut sphincterotomy versus precut papillotomy/fistulotomy techniques

In a retrospective analysis of data obtained during a prospective multicenter study on ERCP-related adverse events (Table 3), patients undergoing PS (both TPS and PP) were extracted and compared [89]. Of 3,178 patients who underwent initial ERCP, 216 patients underwent PS; 140 TPS and 76 PP were performed. There were no significant differences in primary success rates of SBC in those who underwent TPS and PP (82.9% vs. 90.8%). Eventual success rates were 90.0% vs. 90.8%, respectively. Furthermore, overall adverse events and rates of acute PEP were not significantly different between the two groups (14.3% vs. 18.4% and 11.4% vs. 11.8%, respectively).

#### The timing of precut sphincterotomy

Early implementation of PS has been proposed to reduce adverse events related to prolonged attempts at SBC [53,73,81]. Studies that evaluate the timing of PS during ERCP are compared in Table 4. In a meta-analysis of 6 randomized controlled trials that included 966 ERCP patients, PS using various techniques (PP, PF, and EPP) were compared to persistent attempted cannulation using standard techniques [81]. Overall biliary cannulation was similar at approximately 90% (OR 1.20; [95% CI] 0.54-2.69). A significantly lower PEP rate was seen in the early PS group, 2.5% vs. 5.3% respectively (OR 0.47; 95% CI: 0.24-0.91). The overall adverse event rates, including bleeding, pancreatitis, cholangitis, and perforation,

were not significantly different (OR 0.78; [95% CI] 0.44-1.37) between the early PS group and the persistent attempt group (5.0% versus 6.3%, respectively). This suggests that in experienced hands, persistent cannulation attempts and early implementation of PS have similar cannulation rates but early PS reduces the incidence of PEP without adversely affecting the overall adverse event rate.

In a retrospective study, the safety and efficacy of early PP for selective biliary access was assessed [66]. The authors reviewed a cohort of 765 patients who underwent ERCP, of which 55 patients early PP for the following criteria: 1) inadvertent guidewire cannulation of PD on three occasions; 2) biliary stone impacted at papilla; 3) inability to achieve deep cannulation within 10 min. The authors excluded patients due to: 1) the inability to visualize the papilla because of anatomical distortions; 2) complete tumor occlusion of distal bile duct; 3) failure to adhere to inclusion criteria. Of patients meeting the criteria for early PP, immediate biliary cannulation was achieved in 89% of cases, and this rate was increased to 98.2% with repeat ERCP. The overall adverse event rate for the cohort of 765 patients who received ERCP with and without PP was 2.1% (16 of 765), which included: pancreatitis 1.3%, bleeding 0.7%, and perforation 0.3%. The only adverse event observed in the early PP subgroup was pancreatitis (1.8%), which was not significantly different than the standard technique group 1.3% (9 of 710 patients).

Finally, it is important to note that as for any endoscopic procedure the choice of PS technique remains highly individualized and dependent on multiple factors (patient's anatomy, ERCP indication, endoscopist expertise). The success rate of PS improves with increasing experience and biliary cannulation is requisite for therapeutic ERCP. Based on the currently available data it is recommended to perform PS earlier during the procedure than to risk higher rates of adverse events by continued unsuccessful attempts at biliary cannulation.

## Conclusions

Selective cannulation of the biliary duct remains the limiting step in therapeutic ERCP. Difficult biliary cannulation is defined as failure to achieve deep and SBC after 10 or greater attempts or greater than 10 min after first attempt using standard cannulation techniques. There are several resources which may be used to aid successful biliary cannulation including guidewire-assisted biliary cannulation using a sphincterotome, PD guidewire cannulation followed by attempted biliary guidewire cannulation, placement of a PD stent followed by attempted biliary guidewire cannulation and precut biliary sphincterotomy, also known as access sphincterotomy. Placement of a PD stent or use of a guidewire reduces the rate of PEP when attempting SBC. PS increases cannulation success rates, but may be associated with an increased rate of adverse events even when performed by endoscopists with significant experience. Endoscopists who

are inexperienced in PS should consider using alternate techniques depending on the urgency and indication for the procedure. For the experienced endoscopist, it appears that early PS (especially with placement of a prophylactic PD stent) reduces the risk of adverse events as compared to persisting with standard techniques to achieve SBC.

## References

- McCune WS, Shorb PE, Moscovitz H. Endoscopic cannulation of the ampulla of Vater: a preliminary report. *Ann Surg* 1968;**167**:752-756.
- Classen M, Demling L. Endoscopic sphincterotomy of the papilla of Vater and extraction of stones from the choledochal duct (author's transl). *Dtsch Med Wochenschr* 1974;**99**:496-497.
- Kawai K, Akasaka Y, Murakami K, Tada M, Koli Y. Endoscopic sphincterotomy of the ampulla of Vater. *Gastrointest Endosc* 1974;**20**:148-151.
- Harewood GC, Baron TH. An assessment of the learning curve for precut biliary sphincterotomy. *Am J Gastroenterol* 2002;**97**:1708-1712.
- Freeman ML, Guda NM. ERCP cannulation: a review of reported techniques. *Gastrointest Endosc* 2005;**61**:112-125.
- Caletti GC, Vandelli A, Bolondi L, Fontana G, Labo G. Endoscopic retrograde cholangiography (ERC) through artificial endoscopic choledochoduodenal fistula. *Endoscopy* 1978;**10**:203-206.
- Siegel JH. Precut papillotomy: a method to improve success of ERCP and papillotomy. *Endoscopy* 1980;**12**:130-133.
- Osnes M, Kahrs T. Endoscopic choledochoduodenostomy for choledocholithiasis through choledochoduodenal fistula. *Endoscopy* 1977;**9**:162-165.
- Deng DH, Zuo HM, Wang JF, et al. New precut sphincterotomy for endoscopic retrograde cholangiopancreatography in difficult biliary duct cannulation. *World J Gastroenterol* 2007;**13**:4385-4390.
- Mavrogiannis C, Liatsos C, Romanos A, Petoumenos C, Nakos A, Karvountzis G. Needle-knife fistulotomy versus needle-knife precut papillotomy for the treatment of common bile duct stones. *Gastrointest Endosc* 1999;**50**:334-339.
- Abu-Hamda EM, Baron TH, Simmons DT, Petersen BT. A retrospective comparison of outcomes using three different precut needle knife techniques for biliary cannulation. *J Clin Gastroenterol* 2005;**39**:717-721.
- Artifon EL, Hondo FY, Sakai P, Ishioka S. A new approach to the bile duct via needle puncture of the papillary roof. *Endoscopy* 2005;**37**:1158.
- Hashiba K, D'Assuncao MA, Armellini S, Hasegawa RT, Cappellanes CA, Moribe D. Endoscopic suprapapillary blunt dissection of the distal common bile duct in cases of difficult cannulation: a pilot series. *Endoscopy* 2004;**36**:317-321.
- Chutkan RK, Ahmad AS, Cohen J, et al. ERCP core curriculum. *Gastrointest Endosc* 2006;**63**:361-376.
- Huibregtse K, Katon RM, Tytgat GN. Precut papillotomy via fine-needle knife papillotomy: a safe and effective technique. *Gastrointest Endosc* 1986;**32**:403-405.
- Binmoeller KF, Seifert H, Gerke H, Seitz U, Portis M, Soehendra N. Papillary roof incision using the erlangen-type pre-cut papillotomy to achieve selective bile duct cannulation. *Gastrointest Endosc* 1996;**44**:689-695.
- Palm J, Saarela A, Makela J. Safety of erlangen precut papillotomy: an analysis of 1044 consecutive ERCP examinations in a single institution. *J Clin Gastroenterol* 2007;**41**:528-533.

18. Farrell RJ, Khan MI, Noonan N, O'Byrne K, Keeling PW. Endoscopic papillectomy: a novel approach to difficult cannulation. *Gut* 1996;**39**:36-38.
19. Heiss FW, Cimis RS, Jr, MacMillan FP, Jr. Biliary sphincter scissor for pre-cut access: preliminary experience. *Gastrointest Endosc* 2002;**55**:719-722.
20. Elton E, Howell DA, Parsons WG, Qaseem T, Hanson BL. Endoscopic pancreatic sphincterotomy: indications, outcome, and a safe stentless technique. *Gastrointest Endosc* 1998;**47**:240-249.
21. Catalano MF, Linder JD, Geenen JE. Endoscopic transpancreatic papillary septotomy for inaccessible obstructed bile ducts: comparison with standard pre-cut papillotomy. *Gastrointest Endosc* 2004;**60**:557-561.
22. Goff JS. Long-term experience with the transpancreatic sphincter pre-cut approach to biliary sphincterotomy. *Gastrointest Endosc* 1999;**50**:642-645.
23. Goff JS. Common bile duct pre-cut sphincterotomy: transpancreatic sphincter approach. *Gastrointest Endosc* 1995;**41**:502-505.
24. Akashi R, Kiyozumi T, Jinnouchi K, Yoshida M, Adachi Y, Sagara K. Pancreatic sphincter precutting to gain selective access to the common bile duct: a series of 172 patients. *Endoscopy* 2004;**36**:405-410.
25. Artifon EL, Sakai P, Cunha JE, Halwan B, Ishioka S, Kumar A. Guidewire cannulation reduces risk of post-ERCP pancreatitis and facilitates bile duct cannulation. *Am J Gastroenterol* 2007;**102**:2147-2153.
26. Lee TH, Park do H, Park JY, et al. Can wire-guided cannulation prevent post-ERCP pancreatitis? A prospective randomized trial. *Gastrointest Endosc* 2009;**69**(3 Pt 1):444-449.
27. Bailey AA, Bourke MJ, Williams SJ, et al. A prospective randomized trial of cannulation technique in ERCP: effects on technical success and post-ERCP pancreatitis. *Endoscopy* 2008;**40**:296-301.
28. Cheung J, Tsoi KK, Quan WL, Lau JY, Sung JJ. Guidewire versus conventional contrast cannulation of the common bile duct for the prevention of post-ERCP pancreatitis: a systematic review and meta-analysis. *Gastrointest Endosc* 2009;**70**:1211-1219.
29. McCarthy JH, Miller GL, Laurence BH. Cannulation of the biliary tree, cystic duct and gallbladder using a hydrophilic polymer-coated steerable guide wire. *Gastrointest Endosc* 1990;**36**:386-389.
30. Manes G, Di Giorgio P, Repici A, Macarri G, Ardizzone S, Porro GB. An analysis of the factors associated with the development of complications in patients undergoing precut sphincterotomy: a prospective, controlled, randomized, multicenter study. *Am J Gastroenterol* 2009;**104**:2412-2417.
31. Testoni PA, Giussani A, Vailati C, Testoni S, Di Leo M, Mariani A. Precut sphincterotomy, repeated cannulation and post-ERCP pancreatitis in patients with bile duct stone disease. *Dig Liver Dis* 2011;**43**:792-796.
32. Dumonceau JM, Deviere J, Cremer M. A new method of achieving deep cannulation of the common bile duct during endoscopic retrograde cholangiopancreatography. *Endoscopy* 1998;**30**:S80.
33. Cote GA, Anstas M, Pawa R, et al. Difficult biliary cannulation: Use of physician-controlled wire-guided cannulation over a pancreatic duct stent to reduce the rate of precut sphincterotomy (with video). *Gastrointest Endosc* 2010;**71**:275-279.
34. Goldberg E, Titus M, Haluszka O, Darwin P. Pancreatic-duct stent placement facilitates difficult common bile duct cannulation. *Gastrointest Endosc* 2005;**62**:592-596.
35. Somogyi L, Chuttani R, Croffie J, et al. Biliary and pancreatic stents. *Gastrointest Endosc* 2006;**63**:910-919.
36. Choudhary A, Bechtold ML, Arif M, et al. Pancreatic stents for prophylaxis against post-ERCP pancreatitis: a meta-analysis and systematic review. *Gastrointest Endosc* 2011;**73**:275-282.
37. Masci E, Mariani A, Curioni S, Testoni PA. Risk factors for pancreatitis following endoscopic retrograde cholangiopancreatography: a meta-analysis. *Endoscopy* 2003;**35**:830-834.
38. Singh P, Das A, Isenberg G, et al. Does prophylactic pancreatic stent placement reduce the risk of post-ERCP acute pancreatitis? A meta-analysis of controlled trials. *Gastrointest Endosc* 2004;**60**:544-550.
39. Ito K, Fujita N, Noda Y, et al. Can pancreatic duct stenting prevent post-ERCP pancreatitis in patients who undergo pancreatic duct guidewire placement for achieving selective biliary cannulation? A prospective randomized controlled trial. *J Gastroenterol* 2010;**45**:1183-1191.
40. Donnellan F, Byrne MF. Prevention of post-ERCP pancreatitis. *Gastroenterol Res Pract* 2012;**2012**:796751.
41. Cotton PB, Lehman G, Vennes J, et al. Endoscopic sphincterotomy complications and their management: an attempt at consensus. *Gastrointest Endosc* 1991;**37**:383-393.
42. Cotton PB, Eisen GM, Aabakken L, et al. A lexicon for endoscopic adverse events: report of an ASGE workshop. *Gastrointest Endosc* 2010;**71**:446-454.
43. Das A, Singh P, V. SM V, Jr, Chak A. Pancreatic-stent placement for prevention of post-ERCP pancreatitis: a cost-effectiveness analysis. *Gastrointest Endosc* 2007;**65**:960-968.
44. Andriulli A, Loperfido S, Napolitano G, et al. Incidence rates of post-ERCP complications: a systematic survey of prospective studies. *Am J Gastroenterol* 2007;**102**:1781-1788.
45. Brackbill S, Young S, Schoenfeld P, Elta G. A survey of physician practices on prophylactic pancreatic stents. *Gastrointest Endosc* 2006;**64**:45-52.
46. Testoni PA, Testoni S, Giussani A. Difficult biliary cannulation during ERCP: how to facilitate biliary access and minimize the risk of post-ERCP pancreatitis. *Dig Liver Dis* 2011;**43**:596-603.
47. Meine GC, Baron TH. Endoscopic papillary large-balloon dilation combined with endoscopic biliary sphincterotomy for the removal of bile duct stones (with video). *Gastrointest Endosc* 2011;**74**:1119,26; quiz 1115 e1-e5.
48. Baron TH. Complications of endoscopic biliary sphincterotomy: the first cut is the deepest. *Clin Gastroenterol Hepatol* 2004;**2**:968-970.
49. Weber A, Roesch T, Pointner S, et al. Transpancreatic precut sphincterotomy for cannulation of inaccessible common bile duct: a safe and successful technique. *Pancreas* 2008;**36**:187-191.
50. Kapetanios D, Kokozidis G, Christodoulou D, et al. Case series of transpancreatic septotomy as precutting technique for difficult bile duct cannulation. *Endoscopy* 2007;**39**:802-806.
51. Sakai Y, Tsuyuguchi T, Sugiyama H, et al. Transpancreatic precut papillotomy in patients with difficulty in selective biliary cannulation. *Hepatogastroenterology* 2011;**58**:1853-1858.
52. Rabenstein T, Schneider HT, Hahn EG, Ell C. 25 years of endoscopic sphincterotomy in erlangen: assessment of the experience in 3498 patients. *Endoscopy* 1998;**30**:A194-A201.
53. de Weerth A, Seitz U, Zhong Y, et al. Primary precutting versus conventional over-the-wire sphincterotomy for bile duct access: a prospective randomized study. *Endoscopy* 2006;**38**:1235-1240.
54. Burdick JS, London A, Thompson DR. Intramural incision technique. *Gastrointest Endosc* 2002;**55**:425-427.
55. Garcia-Cano J. Needle-knife precut for ERCP cannulation over a guidewire causing intramural incision in the papilla of Vater. *Gastrointest Endosc* 2008;**68**:1024-1025; author reply 1025-1026.
56. Misra SP, Dwivedi M. Intramural incision technique: a useful and safe procedure for obtaining ductal access during ERCP. *Gastrointest Endosc* 2008;**67**:629-633.
57. Lo SK. Intramural incision during ERCP: turning a complication into a positive experience? *Gastrointest Endosc* 2008;**67**:634-635.
58. Zovich D, Faigel DO. Use of the intramural incision technique to retrieve a fractured biliary tube. *Gastrointest Endosc* 2002;**56**:465.
59. Artifon EL, da Silveira EB, Aparicio D, et al. Management of common bile duct stones in cirrhotic patients with coagulopathy: a



- comparison of supra-papillary puncture and standard cannulation technique. *Dig Dis Sci* 2011;**56**:1904-1911.
60. Artifon EL, Paulo S, Cardillo GZ, Ishioka S. Suprapapillary needle puncture for common bile duct access: laboratory profile. *Arq Gastroenterol* 2006;**43**:299-304.
  61. Artifon EL, Sakai P, Ishioka S, Hondo FY, Raju GS. Suprapapillary puncture of the common bile duct for selective biliary access: a novel technique (with videos). *Gastrointest Endosc* 2007;**65**:124-131.
  62. Wiersema MJ, Sandusky D, Carr R, Wiersema LM, Erdel WC, Frederick PK. Endosonography-guided cholangiopancreatography. *Gastrointest Endosc* 1996;**43**(2 Pt 1):102-106.
  63. Matsushita M, Uchida K, Okazaki K. EUS-guided suprapapillary puncture for safe selective biliary access. *Gastrointest Endosc* 2007;**66**:865-866; author reply 866-867.
  64. Tang SJ, Haber GB, Kortan P, et al. Precut papillotomy versus persistence in difficult biliary cannulation: a prospective randomized trial. *Endoscopy* 2005;**37**:58-65.
  65. Figueiredo FA, Pelosi AD, Machado L, et al. Precut papillotomy: a risky technique not only for experts but also for average endoscopists skilled in ERCP. *Dig Dis Sci* 2010;**55**:1485-1489.
  66. Ang TL, Kwek AB, Lim KB, Teo EK, Fock KM. An analysis of the efficacy and safety of a strategy of early precut for biliary access during difficult endoscopic retrograde cholangiopancreatography in a general hospital. *J Dig Dis* 2010;**11**:306-312.
  67. Fukatsu H, Kawamoto H, Kato H, et al. Evaluation of needle-knife precut papillotomy after unsuccessful biliary cannulation, especially with regard to postoperative anatomic factors. *Surg Endosc* 2008;**22**:717-723.
  68. Lee TH, Bang BW, Park SH, Jeong S, Lee DH, Kim SJ. Precut fistulotomy for difficult biliary cannulation: is it a risky preference in relation to the experience of an endoscopist? *Dig Dis Sci* 2011;**56**:1896-1903.
  69. Kasmin FE, Cohen D, Batra S, Cohen SA, Siegel JH. Needle-knife sphincterotomy in a tertiary referral center: efficacy and complications. *Gastrointest Endosc* 1996;**44**:48-53.
  70. Khatibian M, Sotoudehmanesh R, Ali-Asgari A, Movahedi Z, Kolahdoozan S. Needle-knife fistulotomy versus standard method for cannulation of common bile duct: a randomized controlled trial. *Arch Iran Med* 2008;**11**:16-20.
  71. Kahaleh M, Tokar J, Mullick T, Bickston SJ, Yeaton P. Prospective evaluation of pancreatic sphincterotomy as a precut technique for biliary cannulation. *Clin Gastroenterol Hepatol* 2004;**2**:971-977.
  72. Halttunen J, Keranen I, Udd M, Kylanpaa L. Pancreatic sphincterotomy versus needle knife precut in difficult biliary cannulation. *Surg Endosc* 2009;**23**:745-749.
  73. Cennamo V, Fuccio L, Repici A, et al. Timing of precut procedure does not influence success rate and complications of ERCP procedure: a prospective randomized comparative study. *Gastrointest Endosc* 2009;**69**(3 Pt 1):473-479.
  74. Cotton PB. Precut papillotomy-a risky technique for experts only. *Gastrointest Endosc* 1989;**35**:578-579.
  75. Freeman ML. Complications of endoscopic biliary sphincterotomy: a review. *Endoscopy* 1997;**29**:288-297.
  76. Jowell PS, Baillie J, Branch MS, Affronti J, Browning CL, Bute BP. Quantitative assessment of procedural competence. A prospective study of training in endoscopic retrograde cholangiopancreatography. *Ann Intern Med* 1996;**125**:983-989.
  77. Hogan WJ. Uniform standards for gastrointestinal endoscopic training in the U.S.-a need for evaluation and definition. *Gastrointest Endosc* 1988;**34**:362-363.
  78. Kostrzewska M, Baniukiewicz A, Wroblewski E, et al. Complications of endoscopic retrograde cholangiopancreatography (ERCP) and their risk factors. *Adv Med Sci* 2011;**56**:6-12.
  79. Freeman ML, Nelson DB, Sherman S, et al. Complications of endoscopic biliary sphincterotomy. *N Engl J Med* 1996;**335**:909-918.
  80. Freeman ML. Adverse outcomes of endoscopic retrograde cholangiopancreatography. *Rev Gastroenterol Disord* 2002;**2**:147-168.
  81. Cennamo V, Fuccio L, Zagari RM, et al. Can early precut implementation reduce endoscopic retrograde cholangiopancreatography-related complication risk? Meta-analysis of randomized controlled trials. *Endoscopy* 2010;**42**:381-388.
  82. Freeman ML, DiSario JA, Nelson DB, et al. Risk factors for post-ERCP pancreatitis: a prospective, multicenter study. *Gastrointest Endosc* 2001;**54**:425-434.
  83. Gong B, Hao L, Bie L, Sun B, Wang M. Does precut technique improve selective bile duct cannulation or increase post-ERCP pancreatitis rate? A meta-analysis of randomized controlled trials. *Surg Endosc* 2010;**24**:2670-2680.
  84. Smithline A, Silverman W, Rogers D, et al. Effect of prophylactic main pancreatic duct stenting on the incidence of biliary endoscopic sphincterotomy-induced pancreatitis in high-risk patients. *Gastrointest Endosc* 1993;**39**:652-657.
  85. Fazel A, Quadri A, Catalano MF, Meyerson SM, Geenen JE. Does a pancreatic duct stent prevent post-ERCP pancreatitis? A prospective randomized study. *Gastrointest Endosc* 2003;**57**:291-294.
  86. Sofuni A, Maguchi H, Itoi T, et al. Prophylaxis of post-endoscopic retrograde cholangiopancreatography pancreatitis by an endoscopic pancreatic spontaneous dislodgement stent. *Clin Gastroenterol Hepatol* 2007;**5**:1339-1346.
  87. Sofuni A, Maguchi H, Mukai T, et al. Endoscopic pancreatic duct stents reduce the incidence of post-endoscopic retrograde cholangiopancreatography pancreatitis in high-risk patients. *Clin Gastroenterol Hepatol* 2011;**9**:851,8; quiz e110.
  88. Dumonceau JM, Andriulli A, Deviere J, et al. European society of gastrointestinal endoscopy (ESGE) guideline: prophylaxis of post-ERCP pancreatitis. *Endoscopy* 2010;**42**:503-515.
  89. Wang P, Zhang W, Liu F, et al. Success and complication rates of two precut techniques, transpancreatic sphincterotomy and needle-knife sphincterotomy for bile duct cannulation. *J Gastrointest Surg* 2010;**14**:697-704.