

Blunt gastric traumatic injuries: a case revealed at endoscopy

Mohammed Amine Benatta

Military University Hospital, Oran, Algeria

A 24-year-old man was referred to surgical emergency with abdominal pain after a poly-traumatism caused by a car traffic accident, without abnormalities at physical examination and normal findings at thorax radiography, radiography of the pelvis, ultrasonography and abdominal CT scan. Two days later, a peritoneal lavage was scheduled after an upper gastrointestinal endoscopy for persistent and unexplained abdominal pain. The endoscopic findings were a transversal dilaceration several centimeters long and more than one centimeter wide in the fundus with apparent muscular layer and many blood clots (Fig. 1). Our patient was treated with intravenous proton pump inhibitors for 3 days and then with oral relay. Two weeks later an endoscopic control revealed a central clean ulceration with converging folds (Fig. 2). These findings were suggestive of an endoscopic healing.

This kind of lesion is more often the consequence of high velocity impact involving the epigastric region in the post-meal phase which favors a condition of gastric fullness. Car traffic accidents are the most frequent cause of these injuries and are increasingly seen in young populations. Blunt traumatic injuries of the stomach have rarely been described in the medical literature [1,2]; their incidence is estimated between 0.4% and 1.7% of all abdominal traumas [1,3]. The fundus tends to be the most commonly damaged part of the stomach, according to the direct proportionality between pressure and the radius of the cavity (Laplace's law). The thick muscular walls of the stomach make it more resistant to injuries than the other organs. The external, the internal or the middle layer may be partially involved because of the trauma. Peritoneal symptoms are expected and progression to perforation is possible. Blunt gastric traumatic injuries and their endoscopic appearance have been infrequently reported in the medical literature. In our case, the gastric trauma was misdiagnosed at abdominal CT scan. Upper gastrointestinal endoscopy allows an accurate diagnosis and imposes medical treatment.

Endoscopic management and medical treatment avoids peritoneal lavage and possible complications such as perforation of the stomach and peritonitis. Endoscopic evaluation of gastric lesions in traumatized patients may be useful especially in cases with unexplained abdominal pain.

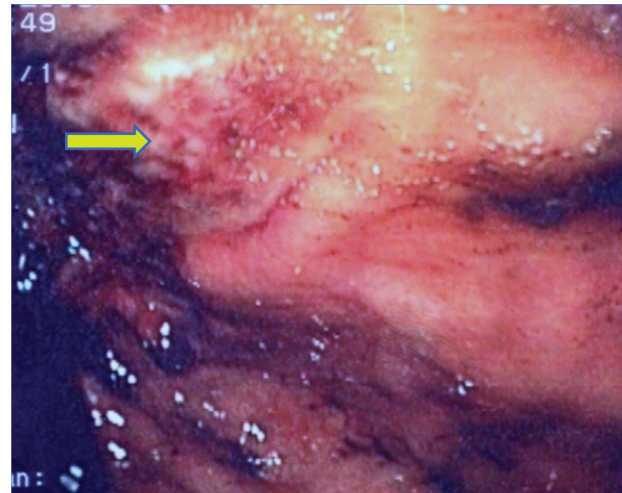


Figure 1 Transversal fundic dilaceration with an apparent muscular layer

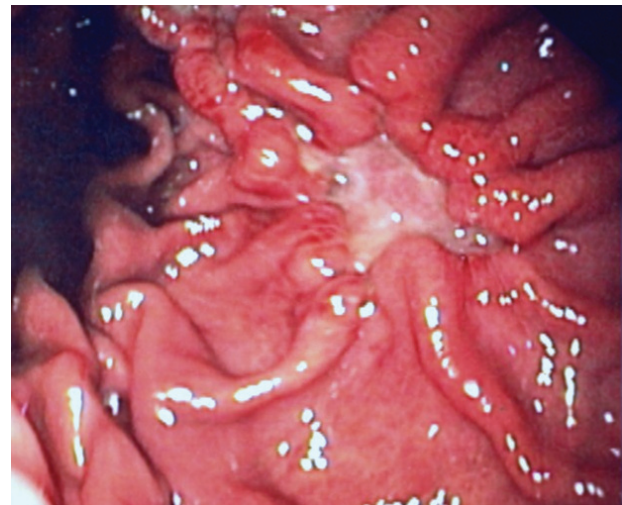


Figure 2 Central ulceration with converging folds

Gastroenterology Department, Military University Hospital, Oran, Algeria

Conflict of Interest: None

Correspondence to: Mohammed Amine Benatta, 156 Bakhti Noubia Oran, Algeria, e-mail: benattaamine@yahoo.fr

Received 30 March 2012; accepted 21 April 2012

References

1. Brunsting LA, Morton JH. Gastric rupture from blunt abdominal trauma. *J Trauma* 1987;**27**:887-891.
2. Yajko RD, Seydel F, Trimble C. Rupture of the stomach from blunt abdominal trauma. *J Trauma* 1975;**15**:77-83.
3. Pikoulis E, Delis S, Tsatsoulis P, et al. Blunt injuries of the stomach. *Eur J Surg* 1999;**165**:937-939.