

Acute pulmonary embolism following N-butyl-cyanoacrylate endoscopic injection sclerotherapy

Nikolaos E. Papiamoni^a, Erminia Matrella^a, Emmanuel G. Blevrakis^b, Elias A. Kouroumalis^a

University Hospital of Heraklion, Heraklion, Crete, Greece

Endoscopic injection of N-butyl-2-cyanoacrylate (Histoacryl) is widely used for the control of gastric variceal bleeding with initial hemostasis rates of 87-100% [1,2]. However, Histoacryl injection has been associated with major complications, including embolism, sepsis, fistula and adherence of the needle within the varix [3,4].

We report a 32-year-old male patient with chronic hepatitis B infection, who presented to our emergency department with loss of consciousness following hematemesis and melena. Due to torrential bleeding, the patient was incubated and underwent upper gastrointestinal endoscopy in the operating theater. An acutely bleeding isolated fundic varix was found, which was obliterated with 2 cc of a 1:1 mixture of Histoacryl (B. Braun, Germany) with Lipiodol (Guerbert, France). Despite successful hemostasis, the patient immediately exhibited ventricular tachycardia, hypoxia (O₂ saturation of 89%), and hypotension (systolic blood pressure of 70 mmHg). The arrhythmia was treated with i.v. infusion of amiodaron (Angoron, Sanofi-Aventis, France) and circulation instability was reversed. A chest radiograph revealed multiple bilateral pulmonary emboli of the Histoacryl/lipiodol mixture (Fig. 1). Pulmonary embolism was confirmed by computed tomography (CT), which showed no evidence of lung infarcts (Fig. 2). The patient remained hemodynamically stable, and hypoxia was reversed within 48 h. Our patient illustrates the risk of pulmonary embolization following sclerotherapy with even small volumes of Histoacryl/lipiodol. Despite eventual recovery of normal lung function, pulmonary embolism with Histoacryl/lipiodol can cause life threatening cardiovascular complications such as ventricular tachycardia that require appropriate monitoring and treatment settings for their management.

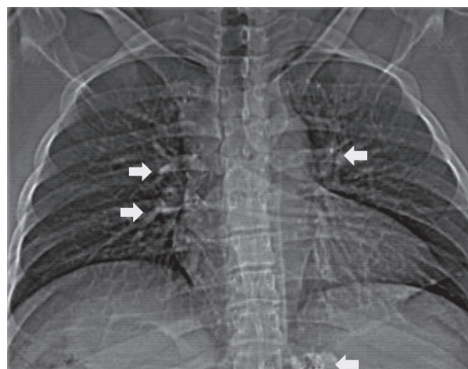


Figure 1 Chest radiograph, following variceal sclerotherapy, showing branching opacities of lipiodol and cyanocrylate mixture throughout both lungs

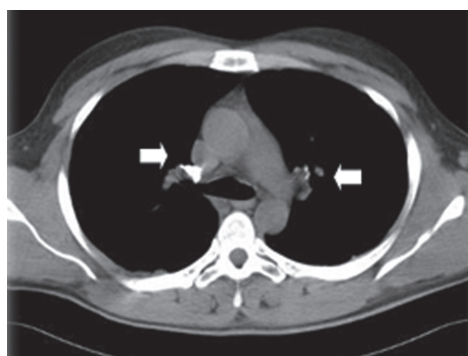

Figure 2 Pre-contrast agent infusion computed tomography scan. Hyperdense material evident in the right pulmonary artery and also in different segmental and subsegmental branches of both lungs

^aDepartment of Gastroenterology, (Nikolaos E. Papiamoni, Erminia Matrella, Elias A. Kouroumalis);

^bDepartment of Radiology (Emmanuel G. Blevrakis), University Hospital of Heraklion, Crete, Greece

Conflict of Interest: None

Correspondence to: Nikolaos E. Papiamoni, MD, Department of Gastroenterology, University Hospital of Heraklion, P.O. BOX 1352, 71110 Heraklion, Crete, Greece, Tel: +30 2810392356, Fax: +30 2810542085, e-mail: nikospapiamoni@hotmail.com

Received 1 March 2012; accepted 12 March 2012

References

- Huang YH, Yeh HZ, Chen GH, et al. Endoscopic treatment of bleeding gastric varices by N-butyl-2-cyanoacrylate (Histoacryl) injection: long-term efficacy and safety. *Gastrointest Endosc* 2000;**52**:160-167.
- Lo GH, Lai KH, Cheng JS, et al. A prospective, randomized trial of butyl cyanoacrylate injection versus band ligation in the management of bleeding gastric varices. *Hepatology* 2001;**33**:1060-1064.
- Seewald S, Ang TL, Imazu H, et al. A standardized injection technique and regimen ensures success and safety of N-butyl-2-cyanoacrylate injection for the treatment of gastric fundal varices (with videos). *Gastrointest Endosc* 2008;**68**:447-454.
- Archimandritis A, Balatsos V, Skandalis N. Image of the month. Histoacryl-lipiodol embolization to the lung. *Gastroenterology* 2001;**120**:336, 589.