

Intramural hematoma of the ascending colon leading to intraperitoneal hemorrhage: a possible post-polypectomy complication

Evangelos Voudoukis^a, Konstantinos G. Spiridakis^b, Konstantinos Karmiris^a, Georgios Georgiou^c, Nikolaos Kontopodis^b, Konstantinos Konstantinidis^a, Konstantinos Psilakis^d, Odysseas Miliadis^b, Georgios Tribonias^a, Gregorios A. Paspatis^a

Venizeleion General Hospital, Heraklion, Crete, Greece

Abstract

A 61-year-old male on anticoagulant therapy underwent an endoscopic multiple colon polypectomy in our Department according to established procedures. Several days later he developed an intramural colonic hematoma, which burst into the peritoneal cavity leading to fatal intra-peritoneal hemorrhage. Herein we present the case and discuss the causative role of the anticoagulant therapy but also of the endoscopic procedure *per se*.

Keywords colonoscopy, intramural colonic hematoma, intra-peritoneal hemorrhage

Ann Gastroenterol 2012; 25 (2): 265-267

Introduction

Intramural colonic hematomas manifest an extremely rare complication mainly following blunt traumas or accompanying diseases with bleeding tendency [1]. When present, they are mostly characterized by abdominal pain, rectal bleeding and bowel obstruction [2-6]. Intra-abdominal hemorrhage is more frequently seen after spleen, liver, kidney or bladder injury.

We present a case of a 61-year-old male, who developed a fatal intramural colonic hematoma several days after an endoscopic procedure, on the basis of long-standing anticoagulant use. The endoscopic as well as the cross-sectional imaging were not typical of a colonic hematoma but rather suggestive for intussusception making diagnosis more puzzling.

Departments of ^aGastroenterology (Evangelos Voudoukis, Konstantinos Karmiris, Konstantinos Konstantinidis, Georgios Tribonias, Gregorios A. Paspatis);

^bAbdominal Surgery (Konstantinos G. Spiridakis, Nikolaos Kontopodis, Odysseas Miliadis); ^cPathology (Georgios Georgiou);

^dAbdominal Imaging (Konstantinos Psilakis), Venizeleion General Hospital, Heraklion, Crete, Greece

Conflict of Interest: None

Correspondence to: Konstantinos Karmiris MD, PhD; Department of Gastroenterology, Venizeleion General Hospital, Leoforos Knossou, P.O. BOX 1044, 71409 Heraklion, Crete, Greece, Tel: +30 2810 311982, Fax: +30 2810 368017, e-mail: karmirhs@hol.gr

Received 31 January 2012; accepted 12 March 2012

Case report

A 61-year-old male was admitted to our hospital due to lymphadenopathy of unknown origin. He was an obese, ex-smoker, receiving acenocoumarol due to aortic valve replacement and coronary artery bypass graft surgery. A colonoscopy with ileal intubation was conducted as part of a thorough work-up. Acenocoumarol was discontinued 5 days before the endoscopic procedure and was substituted by low molecular weight heparin (LMWH). Last LMWH injection was administered the day before endoscopy and was reinstated the day after [7]. His laboratory tests on the day of colonoscopy were: hemoglobin 9.48 g/dL (11-14), platelet count 150 K/ μ L (150-400) and INR 1.3 (0.9-1.2). Three polyps (d=0.4-0.8 cm) were detected and removed: a sessile in the proximal ascending colon using hot snare and two in the sigmoid (a sessile and a pedunculated) using cold snare technique. The diathermy used for hot snare polypectomy (ERBE ICC 200, Tübingen, Germany) was set in endo-cut mode at 120 Watt. The patient was discharged 2 days later without any signs of short-term complications, with instructions for continuing LMWH injections. Two days later he presented with rectal bleeding. A new colonoscopy revealed a red clot on every polypectomy site with oozing bleeding at the ascending colon. Adrenaline solution was injected initially, then clots were removed with a snare and metallic clips (Resolution Clip, Boston Scientific Corporation, Natick, MA) were placed in all three polypectomy sites with resolution of hemorrhage. The patient was discharged 2 days later with instructions for initiating LMWH injections the day after. Ten days later, he presented with lower abdominal pain, three vomiting episodes and gas and stool retention

over the last 24 h. Physical examination revealed an acutely ill, afebrile patient with a palpable mass on his right lower abdominal quadrant and a suggestion of ileus in the plain radiograph. A nasogastric tube was placed and intravenous antibiotic therapy (cefotaxim, metronidazole) and decongestive enemas were introduced. On the following day, his condition deteriorated with an exacerbation of the abdominal pain and a sharp decrease in hemoglobin (11.3 to 9.1 g/dL). He underwent an abdominal CT scan, which provided a suspicion for intussusception of the cecum into the ascending colon (Fig. 1) and a new colonoscopy was conducted. Clips remained intact but in the ascending colon a protruding violet-reddish mass with edematous rims was seen next to the polypectomy site (Fig. 2). The patient was urgently operated, where extensive intra-abdominal hemorrhage was the initial finding. The bleeding source was a wide rupture of both the serosal and muscular layers of the proximal ascending colon. A right hemicolectomy was performed. The patient died, while in the Intensive Care Unit, 4 days later due to recurrent cardiac arrest episodes. Pathology report confirmed the existence of an intramural hematoma in the proximal ascending colon with hemorrhagic infiltration of all layers and no signs of intussusception, vasculitis or other noteworthy coexistent lesions (Fig. 3A).

Discussion

Several cases of intramural colonic hematomas have been described worldwide but to our knowledge this is the first to be considered a late consequence of polypectomy and to lead to intra-peritoneal hemorrhage with fatal outcome. They can develop in different segments of the gastrointestinal tract most commonly in the esophagus, the small and large

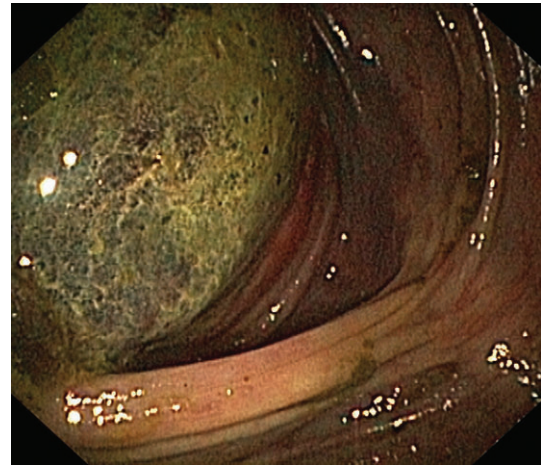


Figure 2 View of the violet-reddish mass on endoscopy

bowel. Anticoagulant therapy can play a crucial role even in the case of pre-procedural drug withdrawal, according to existing guidelines, because re-introduction of the respective agent is not always based on solid data [5]. The clinical symptoms are nonspecific, varying from tolerable abdominal pain to hemorrhagic shock. The examinations of choice are abdominal CT scan and colonoscopy. Intramural

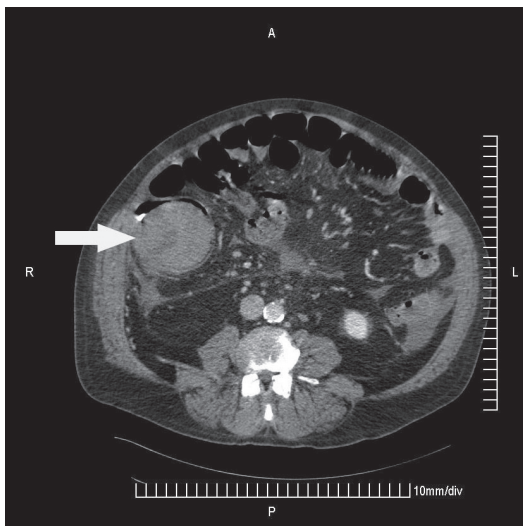
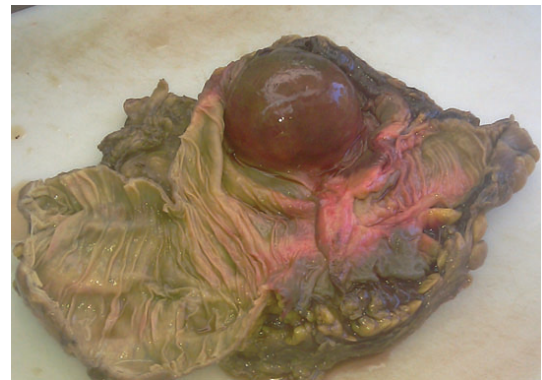
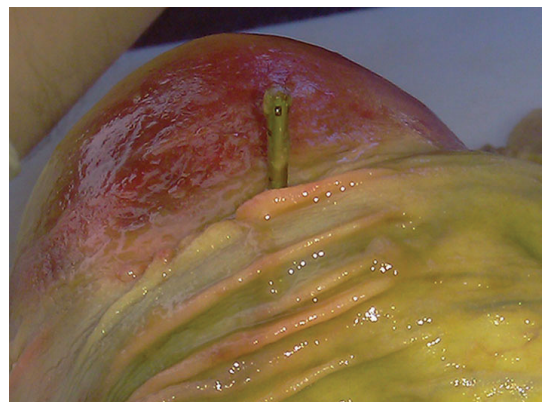
Figure 1 A computed tomography scan section demonstrating the “intussusception” of the cecum into the ascending colon (white arrow)



A



B

Figure 3 Surgical specimen; internal surface (A), proximal view of the clip in close proximity to the intramural colonic hematoma (B)

colonic hematomas can be treated either conservatively or surgically, according to the severity and manifestations of the hematoma. In our case, proper clip placement could be the reason for blocking blood drainage into the bowel lumen, which, in combination with a bleeding diathesis, led to the formation of the intramural hematoma and finally to colon perforation and fatal intra-peritoneal hemorrhage (Fig. 3B). In conclusion, intramural colonic hematoma should be considered in patients undergoing anticoagulant therapy, who present with hematochezia with or without signs and symptoms from the peritoneal cavity after excluding more common causes.

References

1. Ko CW, Dominitz JA. Complications of colonoscopy: magnitude and management. *Gastrointest Endosc Clin N Am* 2010;**20**:659-671.
2. Liu Y, Yang S, Tong Q. Spontaneous intramural hematoma of colon. *Clin Gastroenterol Hepatol* 2012 (in press).
3. Marques I, Lagos AC, Pinto A, Neves BC. Rectal intramural hematoma: a rare complication of endoscopic tattooing. *Gastrointest Endosc* 2011;**73**:366-367.
4. Nogales Rincon O, Yepes Barreto I, Hernando Alonso A, Gonzalez Asanza C, Menchen Fernandez-Pacheco P. Large intramural colonic hematoma after polypectomy. *Endoscopy* 2009;**41**(Suppl 2):E3.
5. Lee SH, Lee JH, Park DH, Chung IK, Park SH, Kim SJ. Intramural colonic hematoma: complication of anticoagulation with heparin. *Gastrointest Endosc* 2005;**62**:783-784.
6. Gallo D, Tebrock C, Rivera D. Intramural cecal hematoma: an unusual complication of colonoscopy. *Gastrointest Endosc* 2003;**57**:254-257.
7. Eisen GM, Baron TH, Dominitz JA, et al. Guideline on the management of anticoagulation and antiplatelet therapy for endoscopic procedures. *Gastrointest Endosc* 2002;**55**:775-779.